

# Management and Clinical Outcome of Acute Basilar Artery Dissection

B.M. Kim  
S.H. Suh  
S.I. Park  
Y.S. Shin  
E.C. Chung  
M.H. Lee  
E.J. Kim  
J.S. Koh  
H.-s. Kang  
H.G. Roh  
Y.S. Won  
P.-W. Chung  
Y.-B. Kim  
B.C. Suh



**BACKGROUND AND PURPOSE:** There have been inconsistencies on the prognosis and controversies as to the proper management of acute basilar artery dissection. The aim of this study was to evaluate acute basilar artery dissection and its outcome after management.

**MATERIALS AND METHODS:** A total of 21 patients (mean age, 53 years; range, 24–78 years) with acute basilar artery dissection were identified between January 2001 and October 2007. Clinical presentation, management, and outcomes were retrospectively evaluated.

**RESULTS:** The patients presented with subarachnoid hemorrhage ( $n = 10$ ), brain stem ischemia ( $n = 10$ ), or stem compression sign ( $n = 1$ ). Ruptured basilar artery dissections were treated by stent placement with coiling ( $n = 4$ ), single stent placement ( $n = 3$ ), or conservatively ( $n = 3$ ). Of the patients treated with endovascular technique, 6 had favorable outcome (modified Rankin scale [mRS], 0–2) and the remaining patient, who was treated by single stent placement, died from rebleeding. All 3 conservatively managed patients experienced rebleeding, of whom 2 died and the other was moderately disabled. Unruptured basilar artery dissections were treated conservatively ( $n = 7$ ) or by stent placement ( $n = 4$ ). Of the patients with unruptured basilar artery dissection, 9 had favorable outcome and the remaining 2 patients, both of whom were conservatively managed, had poor outcome because of infarct progression. The group with the ruptured basilar artery dissection revealed a higher mortality rate than the group with the unruptured dissection (30% vs 0%). The group treated with endovascular means revealed more favorable outcome than the group that was treated with conservative measures (90.9% vs 50%).

**CONCLUSION:** The ruptured basilar artery dissections were at high risk for rebleeding, resulting in a grave outcome. Stent placement with or without coiling may be considered to prevent rebleeding in ruptured basilar dissections and judiciously considered in unruptured dissections with signs of progressive brain stem ischemia.

Acute basilar artery dissections are rare lesions with significant morbidity and mortality rates. However, recent advances in imaging techniques have increased the recognition of basilar artery dissection. There have been inconsistencies on the prognosis and controversies as to the proper management of acute basilar artery dissection.<sup>1–4</sup> Although conservative management has been advocated by some authors,<sup>1</sup> the serious nature of the disease might require surgical or endovascular treatment in selected cases that were ruptured or revealed progressive ischemic symptoms.<sup>2–4</sup> Besides 2 small clinical series<sup>1,2</sup> and a few case reports, clinical features, possible treatment options, and clinical outcome of acute basilar artery dissection have rarely been analyzed. In this study, we retrospectively evaluated clinical presentation, management, clinical course, and outcomes of 21 consecutive patients with acute basilar artery dissection.

Received May 1, 2008; accepted after revision June 10.

From the Departments of Radiology (B.M.K., E.C.C., M.H.L.), Neurosurgery (Y.S.W.), and Neurology (P.-W.C., Y.-B.K., B.C.S.), Sungkyunkwan University School of Medicine, Kangbuk Samsung Hospital, Seoul, Korea; Department of Radiology (S.H.S.), Yonsei University College of Medicine, Seoul, Korea; Department of Radiology (S.I.P.), Soonchunhyang University, Bucheon Hospital, Bucheon, Korea; Department of Neurosurgery (Y.S.S.), Ajou University College of Medicine, Suwon, Korea; Departments of Radiology (E.J.K.) and Neurosurgery (J.S.K.), Kyung Hee University Medical Center, Seoul, Korea; and Departments of Neurosurgery (H.-s.K.) and Radiology (H.G.R.), Konkuk University Hospital, Seoul, Korea.

Please address correspondence to Yong Sam Shin, MD, Department of Neurosurgery, Ajou University College of Medicine, Suwon, Republic of Korea, 442-721; e-mail: nsshin@ajou.ac.kr

 indicates article with supplemental on-line tables.

DOI 10.3174/ajnr.A1243

## Materials and Methods

The institutional review board approved this retrospective study, and informed consents were not required.

Diagnosis of basilar artery dissection was based on clinical manifestations and findings of radiologic examinations including CT with CT angiography, MR imaging with MR angiography, and conventional angiography. Clinical manifestations suggestive of acute basilar artery dissection include subarachnoid hemorrhage confirmed by CT or lumbar tapping, brain stem ischemic symptoms, or sudden posterior headache. Radiologic diagnosis of basilar artery dissection was made when conventional angiography and CT with CT angiography or MR imaging with MR angiography revealed at least 2 of the following findings: intramural hematoma, intimal flap, double-lumen sign, signs of a string or pearl-and-string appearance, focal symmetric or asymmetric dilation of the basilar artery trunk with proximal or distal stenosis, configurational change of the involved segment on serial imaging studies, and contrast media stasis in the affected segment of the basilar artery. Incidentally found radiologic abnormalities of basilar artery, which might be suggestive of arterial dissection but without corresponding clinical symptoms, were excluded because the lesion was not thought to be acute dissection but rather chronic dissection or another pathologic process of the artery.

A total of 25 patients with suspected basilar artery dissections were recruited from the data base of 3 referral institutions between January 2001 and October 2007. Four patients were excluded because of a lack of corresponding clinical symptoms ( $n = 1$ ), insufficient radiologic findings ( $n = 2$ ), or coexistence of a saccular aneurysm that might explain the subarachnoid hemorrhage ( $n = 1$ ). The remaining 21 patients constituted the population of this study. The patients consisted of 12 men and 9 women with ages ranging from 24 to 78 years

(mean, 53 years). All patients underwent conventional angiography. Eighteen patients underwent CT examination and also CT angiography except for 1 patient. Thirteen patients underwent MR imaging with MR angiography.

### **Management Strategy and Endovascular Treatment**

Reconstructive endovascular treatment with stents with or without coiling was primarily considered and was performed for the ruptured basilar artery dissections because reconstructive basilar artery occlusion might lead to severe complications. In unruptured basilar artery dissections, conservative management with anticoagulation and strict blood pressure control was primarily applied to the patients to prevent progression of dissection and recurrent embolism. However, for the patients in whom progression of brain stem ischemia from hemodynamic insufficiency was highly suspected or documented on diffusion MR imaging, or if a brain stem compression sign occurred, stent placement was performed.

Endovascular treatment was performed with the patients under general anesthesia or deep sedation. For the patients with ruptured basilar artery dissection, antiplatelet premedication was not given, but a loading dose of dual antiplatelet medication (aspirin plus clopidogrel) was given after the completion of the treatment. For the patients with unruptured basilar artery dissection, dual antiplatelet premedication preceded the treatment except for 1 patient, who was treated in an early period. Activated coagulation time (ACT) was maintained at 2 to 2.5 times the baseline value for 24 to 48 hours after the procedure. ACT was then normalized for the ruptured basilar artery dissections throughout the follow-up, whereas ACT was maintained for the unruptured basilar artery dissections for 1 to 3 months.

Stent placement or stent-assisted coiling for ruptured basilar artery dissection was performed either with a balloon-expandable stent (Vision; Guidant, Santa Clara, Calif) or with a self-expanding stent (Neuroform; Boston Scientific, Fremont, Calif). Stent placement for unruptured basilar artery dissection with progressive brain stem ischemia was performed with a balloon-expandable Vision stent.

### **Clinical Evaluation and Follow-up**

Patients were clinically assessed at admission, when neurological status of the patient was aggravated, after treatment if treated, and at discharge by neurosurgeons or neurologists. For the patients with ruptured basilar artery dissection, admission clinical status was evaluated according to the Hunt and Hess grading system. For the patients with unruptured basilar artery dissection, admission clinical status was evaluated according to the National Institutes of Health Stroke Scale score. Each patient's clinical outcome was evaluated and graded according to the modified Rankin scale score (mRS),<sup>5</sup> and clinical outcome at the latest clinical follow-up was defined as the final outcome.

### **Results**

Clinical presentation, the shape of the basilar artery dissection, treatment, clinical course, and outcome of patients with basilar artery dissection are summarized in on-line Table 1. On-line Table 2 summarizes angiographic follow-up results in patients who were treated by the reconstructive endovascular method.

There were 10 patients who presented with subarachnoid hemorrhage, 10 patients with brain stem ischemic symptoms with or without headache, and 1 patient with a brain stem compression sign 3 years after initial presentation of brain stem infarct.

The identified cause of acute basilar artery dissection was traumatic in 1 patient. In the remaining 20 patients, there was no identifiable cause of the basilar artery dissection.

### **Management and Clinical Outcome**

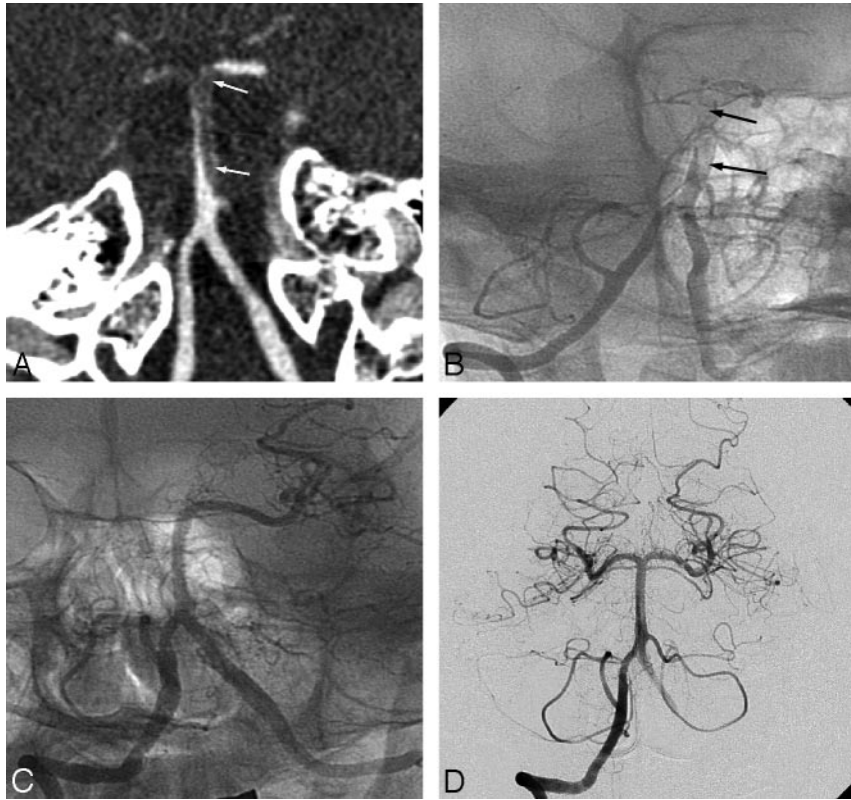
Of the 10 patients with ruptured basilar artery dissection, 3 (30%) died from rebleeding, but none of the 11 patients with unruptured basilar artery dissection died. Eleven patients (7 with ruptured and 4 with unruptured dissection) were treated by stent placement with or without coiling, and the other 10 patients were treated conservatively. There was no treatment-related complication or neurologic deterioration during or after the treatment. All of the 18 surviving patients were clinically followed up at a mean of 21.5 months (range, 5–50 months). Ten (90.9%) of the 11 patients who were treated by the endovascular method (7 with ruptured and 4 with unruptured dissection) had a favorable outcome, whereas 5 (50%) of the 10 conservatively treated patients (3 with ruptured and 7 with unruptured dissection) had a favorable outcome.

Of the 10 patients with ruptured basilar artery dissection, 4 patients were treated by single- or double-stent placement with coiling, 3 by single-stent placement, and 3 by conservative management. All of the 3 conservatively treated patients experienced rebleeding, of whom 2 died and the other was moderately disabled (mRS, 4). Of the 7 patients treated with the endovascular method, 6 had a favorable outcome (mRS, 0–2), but the other patient, who was treated by single-stent placement, experienced rebleeding and died.

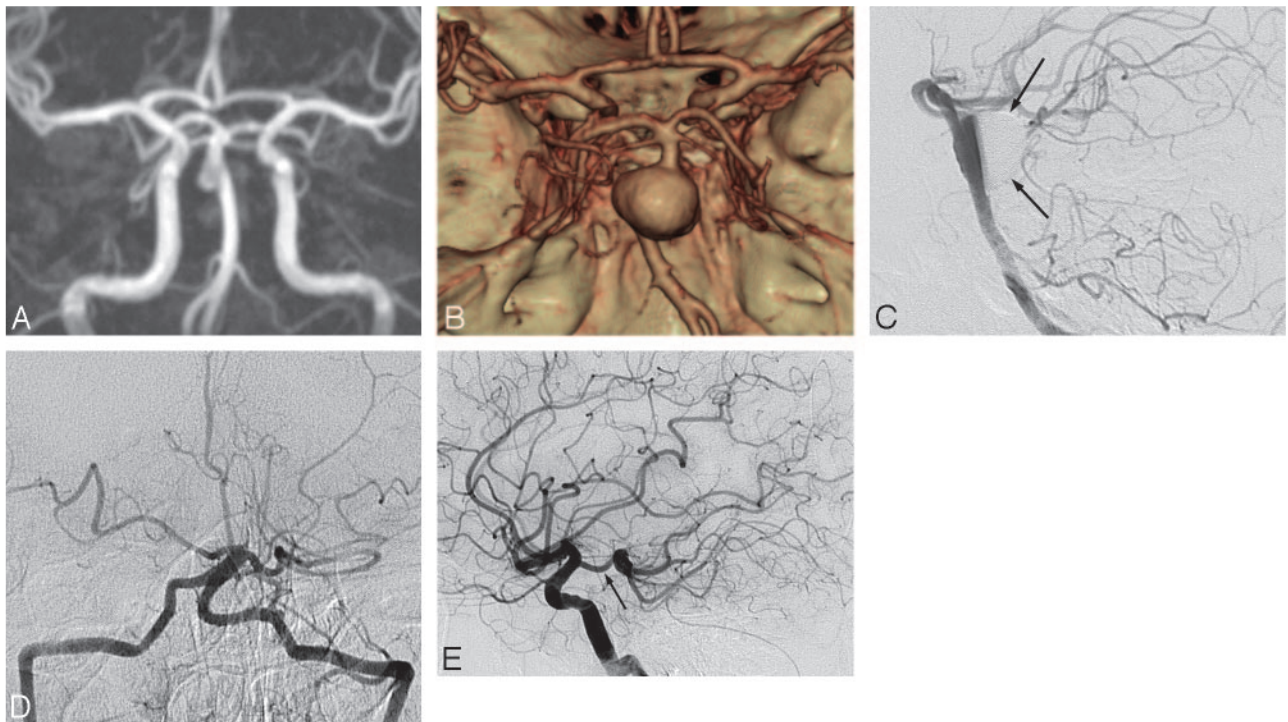
Of the 11 patients with unruptured basilar artery dissection, 9 were treated first by anticoagulation therapy and strict blood pressure control. Of these 9 patients, 5 recovered without further progression of the infarct. The remaining 4 patients had signs of progressive brain stem ischemia, of whom 2 were treated by single-stent placement and the other 2 were treated conservatively. The 2 patients treated by single-stent placement had a favorable outcome without further progression of the infarct, whereas the other 2 patients had a poor outcome from infarct progression.

Of the 11 patients with unruptured basilar artery dissection, 2 were initially treated by stent placement. One patient was treated by emergency stent placement for progressive deterioration of consciousness at presentation and near-occlusion of the basilar artery on angiography and completely recovered (Fig 1). The other patient presented with stem compression by a growing pseudoaneurysm 3 years after initial presentation of brain stem infarct (Fig 2). He was treated by double-overlapping stent placement and also completely recovered.

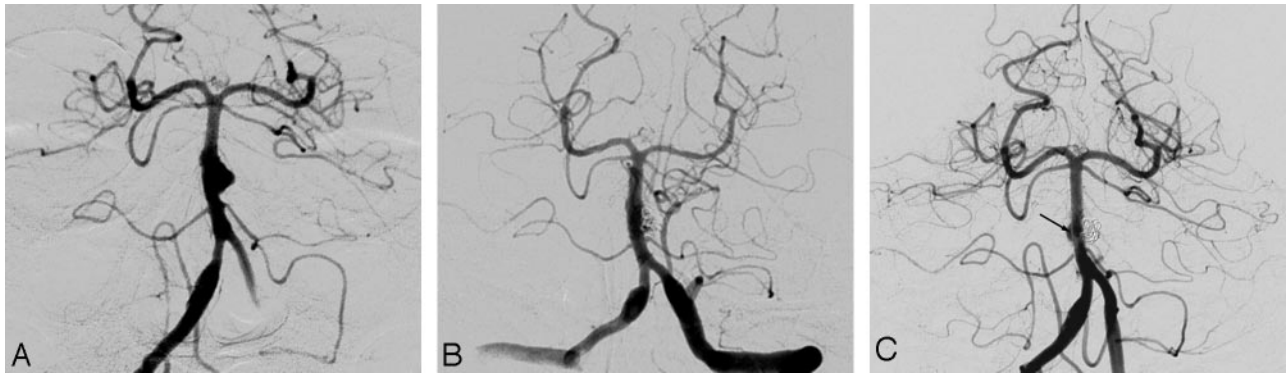
All of the 10 surviving patients treated with the endovascular method underwent follow-up conventional angiography at a mean of 9 months (range, 3–18 months). In 8 of these 10 patients, follow-up angiograms revealed complete resolution of the dilation or stenosis with reconstruction of the basilar artery. In 1 patient who was treated by double stents with coiling for a ruptured basilar artery dissection, a 9-month follow-up angiogram revealed minimal contrast media filling outside the stent (Fig 3). In the other patient who was treated by double-stent placement, a 4-month follow-up angiogram revealed in-stent occlusion of the basilar artery and a hypertrophied right posterior communicating artery that suffi-



**Fig 1.** A 42-year-old man presenting with progressive deterioration of consciousness. CT angiogram (A) and vertebral angiogram (B) reveal near-occlusion of the basilar artery by an intramural hematoma (arrows). C, After emergency stent insertion, the basilar artery and left posterior cerebral artery are visualized, but the right posterior cerebral artery is not seen on vertebral angiogram. D, A 2-week (not seen) and 18-month follow-up vertebral angiogram show a patent basilar artery and its branches. The patient had a favorable outcome (mRS score, 0).



**Fig 2.** A 30-year-old man presenting with signs of stem compression 3 years after initial presentation of brain stem infarction. A, Initial MR angiogram reveals focal asymmetric dilation in the distal basilar artery. B, CT angiogram 3 years after initial MR imaging as a result of brain stem compression. A large asymmetric pseudoaneurysm is demonstrated in the same location. C, Vertebral angiogram in lateral projection after overlapping double-stent deployment shows flow redirection through the stent and the basilar artery with stasis of contrast media in the pseudoaneurysmal sac (arrows). D and E, A 4-month follow-up vertebral artery angiogram (D) and right internal carotid artery angiogram (E) reveal occlusion of the basilar artery and hypertrophied right posterior communicating artery (arrow), which supplies the distal basilar artery and its branches.



**Fig 3.** A 48-year-old woman presenting with a subarachnoid hemorrhage. *A*, Initial vertebral angiogram reveals focal asymmetric dilation of the basilar artery. *B*, Minimal contrast media filling remains in the coil-embolized pseudoaneurysmal sac outside the stents. *C*, A 9-month follow-up angiogram shows complete obliteration of the pseudoaneurysmal sac and minimal contrast media filling portion in the right side outside the stents. Note the gap (*arrow*) between the stents and contrast media filling portion.

ciently supplied the upper basilar artery and its branches (Fig 2). This patient did not have any ischemic complications and completely recovered.

### Discussion

Regardless of its presentation, acute basilar artery dissection seems to have a worse prognosis than a dissection limited to the vertebral artery;<sup>1-4</sup> nevertheless, little is known about the clinical course and prognosis. A literature review by Masson et al<sup>4</sup> disclosed 38 cases of basilar artery dissection, including 18 cases of isolated basilar artery dissection. Of the 38 patients, 30 (78.9%) died. Yoshimoto et al<sup>2</sup> reported 10 patients with basilar artery dissection (4 with ruptured and 6 with unruptured dissections). Of the 4 patients with ruptured basilar artery dissection, 1 died and 2 were severely disabled, whereas 4 of the 6 patients with unruptured basilar artery dissection were severely disabled because of infarct progression.

In the present study, 10 (47.6%) of the 21 basilar artery dissections were ruptured. The ruptured basilar artery dissections had a higher mortality rate than the unruptured ones (30% for ruptured group vs 0% for unruptured group) and the endovascularly treated group had a more favorable outcome than the conservatively managed group (90.9% for endovascularly treated group vs 50% for conservatively treated group).

Although several authors<sup>1,6,7</sup> have reported spontaneous healing of ruptured basilar artery dissections and recommended conservative therapy, a review of the literature indicates that ruptured basilar artery dissection is a life-threatening disease.<sup>4,8</sup> Nakahara et al<sup>8</sup> reviewed 25 cases of ruptured basilar artery dissection including their own case. Of those 25 cases, the morbidity and mortality rates of ruptured basilar artery dissection were 20% and 40%, respectively. Therefore, given the risk of rebleeding, which results in a grave outcome, surgical or endovascular treatment may be necessary in ruptured basilar artery dissection. However, treatment options for the ruptured dissections are rather limited, because the basilar artery has many important perforating branches and unique anatomic characteristics. Although a few cases have been reported,<sup>9,10</sup> surgical or endovascular basilar artery occlusion may result in severe ischemic complications, which may be life threatening unless sufficient collateral is present through the posterior communicating arteries. Unilateral vertebral artery occlusion or staged bilateral vertebral artery oc-

clusion may be an option for treatment of ruptured basilar artery dissection.<sup>8</sup> However, a protective effect of unilateral vertebral artery occlusion is in doubt because persistent antegrade flow impinges the ruptured fragile wall of the dissection.<sup>2</sup> Furthermore, staged bilateral vertebral artery occlusion cannot guarantee protection of the patient from rebleeding in the acute stage when unilateral vertebral artery occlusion is conducted, nor can it guarantee protection from severe ischemic complications after bilateral occlusion. Reconstructive clipping of a dissecting aneurysm is another option; however, it can be very difficult and dangerous because of the nature of the dissection, which has a fragile wall and usually does not have a neck feasible for clipping. To the best of our knowledge, such reconstructive clipping of a basilar artery dissection has been reported in only a single case, which was definitively in the saccular form feasible for clipping.<sup>11</sup>

Reconstructive endovascular treatment by stents with or without coiling seems to be a promising treatment option for ruptured basilar artery dissections. In this study, all 3 conservatively managed patients experienced rebleeding, whereas 6 of 7 treated patients favorably recovered with complete or near-complete healing of the dissection on follow-up angiography. Only 1 patient, who was treated by single stent placement, died from rebleeding. Mizutani et al<sup>12</sup> demonstrated that an acute ruptured vertebral artery dissection may heal with neointima formation in 4 weeks. Therefore, the treatment goals for ruptured dissection are prevention from rebleeding in the acute stage and promotion of healing as rapidly as possible. A stent promotes neointima formation along the stent struts in experimental models<sup>13,14</sup> and may also prevent rebleeding in the acute stage by flow redirection and lowering of the wall stress of a dissecting pseudoaneurysm.<sup>15</sup> As seen in this study, however, a single stent may not be sufficient to prevent rebleeding. Coiling combined with stent placement immediately decreases blood flow impingement into the fragile wall by forming a thrombus within the pseudoaneurysmal sac, thereby immediately further decreasing the wall stress of the pseudoaneurysm. As a result, it may further lessen the possibility of rebleeding compared with a stent alone.<sup>16</sup> Multiple stent placement without coiling was not tried in this study, though several cases have been reported to show that multiple overlapping stents prevent rebleeding and heal the pseudoaneurysm.<sup>15,17,18</sup> It may be another option for rup-

tured basilar artery dissection, especially when stent-assisted coiling is not feasible.

In our study, either the balloon-expandable stent or the self-expanding stent was used. In an early period, only the balloon-expandable coronary stent was used because the self-expanding neurovascular stent (Neuroform stent) was not available. After introduction of the self-expanding Neuroform stent, the stent used was selected according to the angio-anatomic features of the vertebrobasilar artery (ie, the difference between the proximal and distal diameter of the basilar artery and tortuosity of the vertebrobasilar artery) and the availability of the stent appropriate for the lesion in each institute. Some different characteristics seem to be present between the 2 types of stents. The self-expanding Neuroform stent is easier to navigate into the target lesion even in very tortuous vertebrobasilar arteries. It has a larger pore size and permits easy selection of the pseudoaneurysmal sac by using a microcatheter between the interstices when stent-assisted coiling was tried. It is also safely deployed in the artery with a quite different proximal and distal diameter. Lastly, it is probably safer than the balloon-expandable stent because it has low radial pressure, and there is no need for the inflating pressure during deployment. The balloon-expandable stent has more strut attenuation, and its struts herniate less into the pseudoaneurysmal sac. This characteristic may make the balloon-expandable stent superior to the self-expanding Neuroform stent in the flow remodeling effect. Additional studies will be required about which type of stent is better in the treatment of intracranial vertebrobasilar dissections.

Although the unruptured basilar artery dissection had relatively favorable outcome compared with the ruptured one, unruptured basilar artery dissection may sometimes be fatal or lead to severe deficits.<sup>2,4</sup> Although no patient died from unruptured basilar artery dissection in our study, 2 patients who were conservatively managed were disabled because of infarct progression. On the other hand, 3 patients who were treated by stent placement because of signs of progressive brain stem ischemia recovered favorably without further infarct progression. Therefore, stent placement may judiciously be considered in the patient who reveals signs of progressive brain stem ischemia from hemodynamic insufficiency.

## Conclusion

The results of this study suggest that a ruptured basilar artery dissection is at high risk for rebleeding, resulting in a grave outcome, whereas an unruptured basilar artery dissection has relatively favorable outcome. The patients with basilar artery dissections treated by stent placement with or without coiling

revealed a better outcome than conservatively managed patients. Stent placement with or without coiling may be considered a treatment option to prevent rebleeding in ruptured basilar artery dissections. The patients with unruptured basilar artery dissections should first be treated conservatively. However, stent placement may judiciously be considered in selected patients who reveal signs of progressive brain stem ischemia.

## References

1. Pozzati E, Andreoli A, Padovani R, et al. **Dissecting aneurysms of the basilar artery.** *Neurosurgery* 1995;36:254–58
2. Yoshimoto Y, Hoya K, Tanaka Y, et al. **Basilar artery dissection.** *J Neurosurg* 2005;102:476–81
3. Hosoda K, Fujita S, Kawaguchi T, et al. **Spontaneous dissecting aneurysms of the basilar artery presenting with a subarachnoid hemorrhage. Report of two cases.** *J Neurosurg* 1991;75:628–33
4. Masson C, Krespy Y, Masson M, et al. **Magnetic resonance imaging in basilar artery dissection.** *Stroke* 1993;24:1264–66
5. van Swieten JC, Koudstaal PJ, Visser MC, et al. **Interobserver agreement for the assessment of handicap in stroke patients.** *Stroke* 1988;19:604–07
6. Woimant F, Spelle L. **Spontaneous basilar artery dissection: contribution of magnetic resonance imaging to diagnosis.** *J Neurol Neurosurg Psychiatry* 1995;58:540
7. Ross GJ, Ferraro F, DeRiggi L, et al. **Spontaneous healing of basilar artery dissection: MR findings.** *J Comput Assist Tomogr* 1994;18:292–48
8. Nakahara T, Satoh H, Mizoue T, et al. **Dissecting aneurysm of basilar artery presenting with recurrent subarachnoid hemorrhage.** *Neurosurg Rev* 1999;22:155–58
9. Wenderoth JD, Khangure MS, Phatouros CC, et al. **Basilar trunk occlusion during endovascular treatment of giant and fusiform aneurysms of the basilar artery.** *AJNR Am J Neuroradiol* 2003;24:1226–29
10. Amin-Hanjani S, Ogilvy CS, Buonanno FS, et al. **Treatment of dissecting basilar artery aneurysm by flow reversal.** *Acta Neurochir* 1997;139:44–51
11. Ali MJ, Bendok BR, Tella MN, et al. **Arterial reconstruction by direct surgical clipping of a basilar artery dissecting aneurysm after failed vertebral artery occlusion: technical case report and literature review.** *Neurosurgery* 2003;52:1475–81
12. Mizutani T, Kojima H, Asamoto S. **Healing process for cerebral dissecting aneurysms presenting with subarachnoid hemorrhage.** *Neurosurgery* 2004;54:342–48
13. Geremia G, Brack T, Brennecke L, et al. **Occlusion of experimentally created fusiform aneurysms with porous metallic stents.** *AJNR Am J Neuroradiol* 2000;21:739–45
14. Bai H, Masuda J, Sawa Y, et al. **Neointima formation after vascular stent implantation. Spatial and chronological distribution of smooth muscle cell proliferation and phenotypic modulation.** *Arterioscler Thromb* 1994;14:1846–53
15. Fiorella D, Albuquerque FC, Deshmukh VR, et al. **Endovascular reconstruction with the Neuroform stent as monotherapy for the treatment of uncoilable intradural pseudoaneurysm.** *Neurosurgery* 2006;59:291–300
16. Kim BM, Chung EC, Park SI, et al. **Treatment of blood blister-like aneurysm of the internal carotid artery with stent-assisted coil embolization followed by stent-within-a-stent technique. Case report.** *J Neurosurg* 2007;107:1211–13
17. Benndorf G, Herbon U, Sollmann WP, et al. **Treatment of a ruptured dissecting vertebral artery aneurysm with double stent placement: case report.** *AJNR Am J Neuroradiol* 2001;22:1844–48
18. Mehta B, Burke T, Kole M, et al. **Stent-within-a-stent technique for the treatment of dissecting vertebral aneurysms.** *AJNR Am J Neuroradiol* 2003;24:1814–18