

The **next generation** GBCA  
from Guerbet is here

Explore new possibilities >

Guerbet | 

© Guerbet 2024 GUOB220151-A

# AJNR

## **Results of 101 Aneurysms Treated with Polyglycolic/Polylactic Acid Microfilament Nexus Coils Compared with Historical Controls Treated with Standard Coils**

W.J. van Rooij, A.N. de Gast and M. Sluzewski

This information is current as  
of March 20, 2024.

*AJNR Am J Neuroradiol* 2008, 29 (5) 991-996

doi: <https://doi.org/10.3174/ajnr.A1021>

<http://www.ajnr.org/content/29/5/991>

## ORIGINAL RESEARCH

W.J. van Rooij  
A.N. de Gast  
M. Sluzewski

# Results of 101 Aneurysms Treated with Polyglycolic/Polylactic Acid Microfilament Nexus Coils Compared with Historical Controls Treated with Standard Coils

**BACKGROUND AND PURPOSE:** Polyglycolic/polylactic acid (PGLA) addition to bare platinum coils is intended to reduce the reopening rate of coiled intracranial aneurysms. Nexus coils are standard complex platinum coils with interwoven PGLA microfilament threads. We present the clinical results of 101 intracranial aneurysms treated with Nexus coils.

**MATERIALS AND METHODS:** Results of coiling of 101 aneurysms treated with Nexus coils were compared with our results of coiling of 120 aneurysms with Guglielmi detachable coils (GDC 10) and 115 with Trufill coils treated between May 2003 and December 2004 with the same treatment protocol. Rate of complications, mean aneurysmal volume, packing attenuation, incomplete aneurysmal occlusion at 6 months, and rates of retreatment were compared.

**RESULTS:** Initial occlusion in aneurysms treated with Nexus coils was (near) complete in 97 aneurysms and incomplete in 4 aneurysms. There were no permanent procedural complications (0/95 patients, 0%; 97.5% CI, 0.0% to 3.3%). Mean aneurysmal volume was 180.2 mm<sup>3</sup> (range, 5–1624 mm<sup>3</sup>). Mean packing was 19.4% (range, 7.5% to 38.9%). Six months' angiographic follow-up in 87 of 101 aneurysms showed incomplete occlusion in 14 (16%), and 12 (14%) of those had additional coiling. Mean packing of 19.4% of Nexus coils was significantly lower than 22.9% for GDC 10 and 29.7% for Trufill coils. Other clinical results were not significantly different.

**CONCLUSION:** In this series, PGLA microfilament Nexus coils were safe to use with clinical results comparable with those of standard platinum coils. This study gives additional evidence of the lack of beneficial effect of PGLA addition to reduce the reopening rate of coiled intracranial aneurysms.

Endovascular treatment of intracranial aneurysms with bare platinum coils has become an accepted alternative to surgery.<sup>1</sup> The most significant drawback of this technique is the possibility of aneurysmal reopening with time that occurs at an incidence of approximately 10%. In particular, large and giant aneurysms and initially incompletely occluded aneurysms are at risk of reopening.<sup>2–4</sup> Animal models and human studies have shown that the biologic response of intracranial aneurysms to bare coils is complex, requiring stability of the initial occlusion for a considerable period of time for a stable and durable treatment result. As for now, high packing attenuation is the only proved factor predictive of stable occlusion.<sup>2</sup> Recently, coating the surface of bare platinum coils with a biodegradable polymer consisting of polyglycolic/polylactic acid (PGLA) was proposed in an attempt to amplify tissue response to coils with intended reduction of reopening rate. After an experimental study in 26 swine and a registry of 100 patients,<sup>5,6</sup> Boston Scientific (Fremont, Calif) introduced the first PGLA-coated coil (Matrix) on the market in 2003, later followed by other manufacturers. Matrix coils have a thick PGLA coating over a platinum core with different physical properties (eg, softness, surface smoothness) from standard bare platinum coils resulting in different handling.

The Nexus PGLA microfilament coil was introduced by ev3

(Irvine, Calif) in 2005. Nexus coils are standard bare platinum coils with additional PGLA microfilament threads interwoven into the primary coil. The concept of microfilament threads was chosen by the manufacturer to maintain the physical properties of the standard bare platinum coil (personal communication, Research and Development, ev3). In our study, we present our results with coiling of 101 intracranial aneurysms with Nexus microfilament coils. In addition, we compare the results of Nexus coils with historical data of 2 types of bare platinum coils from our institution.<sup>7</sup>

## Patients and Methods

### Description of Coils

Nexus coils have a thickness of 0.010 inch and are available in helical and in 2 different complex shapes (Morpheus and Tetris). Nexus coils have PGLA microfilament threads interwoven into the primary coil (Fig 1). In addition, the coils have a nitinol inner core intended to make the coil resistant to stretch and compaction.

### Patients

Between May 15, 2006, and May 5, 2007, a total of 101 aneurysms in 95 patients were treated with Nexus coils. Patients were not consecutive; in the same period, another 23 aneurysms were treated with other types of coils for the following reasons: in the beginning and end of the study period, stock of Nexus coils was incomplete (12 aneurysms), there was operator preference for (thicker) GDC 18 coils (Boston Scientific) in aneurysms of 10 to 20 mm (7 aneurysms), and conversion from Nexus coils to other types of coils took place (4 aneurysms).

There were 39 men and 56 women with a mean age of 53.6 years

Received November 16, 2007; accepted after revision December 19.

From the Department of Radiology, St. Elisabeth Ziekenhuis, Tilburg, the Netherlands.

Please address correspondence to Willem Jan van Rooij, MD, PhD, Department of Radiology, St. Elisabeth Ziekenhuis, Hilvarenbeekseweg 60, 5022 GC Tilburg, the Netherlands; e-mail: radiol@knmg.nl

DOI 10.3174/ajnr.A1021



**Fig 1.** Schematic representation of complex-shaped Nexus coil with interwoven PGLA microfilament threads.

(median, 53 years; range, 14–89 years). Of 101 aneurysms, 77 had ruptured and 24 had not. Of 24 unruptured aneurysms, 12 were incidentally discovered, 8 were additional to another ruptured aneurysm, and 4 presented with symptoms of mass effect. Of 77 patients with a ruptured aneurysm, Hunt and Hess (HH) grading at the time of treatment was HH I–II in 41, HH III in 16, HH IV–V in 20 patients. Timing of treatment after subarachnoid aneurysm (SAH) was 0 to 3 days in 55 patients, 4 to 7 days in 13 patients, and more than 7 days in 9 patients.

The location of the 101 aneurysms was the anterior communicating artery in 34, middle cerebral artery in 20, posterior communicating artery in 15, ophthalmic artery in 10, basilar tip in 7, posterior inferior cerebellar artery in 5, pericallosal artery in 4, anterior choroidal artery in 2, superior cerebellar artery in 2, posterior cerebral artery in 1, and vertebral artery in 1. Mean aneurysmal size was 6.6 mm (median, 6; range, 2–16 mm).

### Coiling Procedure and Complication Registration

Coiling of aneurysms was performed on a biplane angiographic unit (Integris BN3000; Philips Medical Systems, Best, the Netherlands) with the patient under general anesthesia. The aim of coiling was to obtain an attenuated packing of the aneurysm, until not 1 coil could be placed. After location of the aneurysm on 2D angiography, 3D rotational angiography was performed of the vessel harboring the aneurysm. From 3D images, coil projection was assessed, and measurements of the diameter and volume of the aneurysm were performed. Used types of coils, number and lengths of coils, and total volume of inserted coils were assessed for every aneurysm. Packing, defined as coil volume/aneurysmal volume  $\times$  100%, was calculated. Coil volume was calculated with a spreadsheet provided by the manufacturer, which contained volumes per centimeter of every type of coil. Angiographic occlusion was dichotomized in (near) complete occlusion (90% to 100%) or incomplete occlusion ( $<$  90%).

Complications leading to temporary or permanent neurologic deficit or death were recorded. In addition, all technical complications related to the Nexus coils were recorded, regardless of clinical impact.

**Table 1: Comparison of rupture status and aneurysm locations for the three compared groups treated with different types of coils**

	Nexus	GDC 10	Trufill
Number of aneurysms	101	120	115
Ruptured aneurysms (%)	77 (76)	97 (81)	93 (81)
Location on anterior cerebral artery (%)	38 (37)	50 (42)	45 (39)
Location on carotid artery (%)	27 (27)	35 (29)	38 (33)
Location on middle cerebral artery (%)	20 (20)	12 (10)	5 (4)
Location on posterior circulation (%)	16 (16)	23 (19)	27 (24)

**Note:**—GDC indicates Guglielmi detachable coils.

### Supporting Devices

One aneurysm was coiled with a temporary supporting balloon (HyperForm; ev3), another aneurysm was coiled after placement of a neck-bridging device (TriSpan; Boston Scientific), and 5 aneurysms were coiled after stent placement (Enterprise; Cordis Neurovascular, Miami Lakes, Fla).

### Anticoagulation Protocol

During coiling of ruptured aneurysms, no heparin was administered apart from the heparin in the pressure bags (1000 U per 500 mL of saline). During coiling of unruptured aneurysms not additional to another ruptured aneurysm, 2500 U of heparin was administered before insertion of the microcatheter. After the procedure, no anticoagulation was given in small aneurysms with complete occlusion. In larger and wide-necked aneurysms, subcutaneous heparin in a therapeutic dosage was prescribed for 48 hours.

Patients with unruptured aneurysms treated with stent-assisted coiling were preloaded with clopidogrel 75 mg and aspirin 80 mg; this was continued for 3 to 6 months after the procedure. Patients with acutely ruptured aneurysms treated with stent-assisted coiling received intravenous aspirin 500 mg before placement of the stent. In all patients treated with stents, response to antiplatelet medication was tested with the VerifyNow P2Y<sub>12</sub> Assay (Accumetrics, San Diego, Calif) before stent placement.

When formation of thrombus on the coil mesh was angiographically visible or when coil loops protruded outside the aneurysm in the parent artery, intravenous infusion of a glycoprotein IIb/IIIa antagonist (tirofiban [Aggrastat], Merck & Co, Whitehouse Station, NJ), was started for 24 to 48 hours' duration.

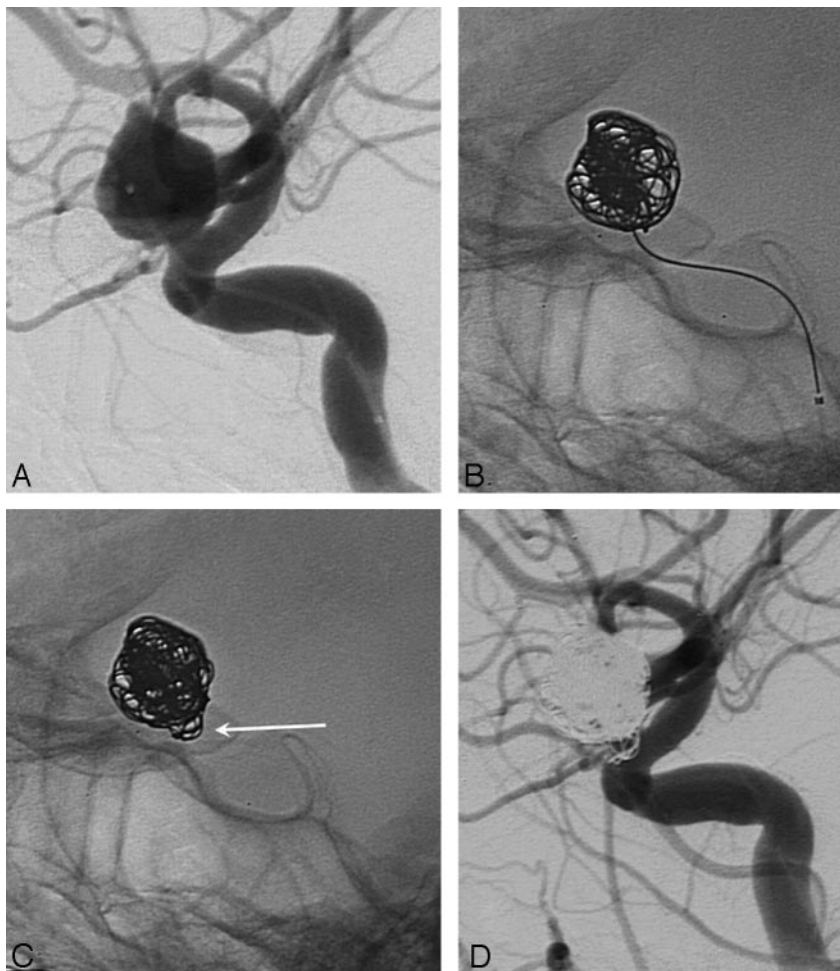### Clinical and Angiographic Follow-Up

Patients who survived the hospital admission period were scheduled for a follow-up visit at 6 weeks and for angiographic follow-up at 6 months. Results of angiographic follow-up were classified in the same way as initial angiographic occlusion. Need for additional treatment was assessed in a weekly meeting with neuroradiologists, neurologists, and neurosurgeons. Outcome according to the Glasgow Outcome Scale (GOS) was assessed at 6 months.

### Comparison With Historical Data of Bare Platinum Coils

Results of coiling of 101 aneurysms with Nexus coils were compared with historical results of coiling of 120 aneurysms with GDC 10 coils and 115 aneurysms with Trufill coils (Cordis) with use of identical methodology.<sup>7</sup> Locations of the aneurysms and status of rupture for the 3 compared groups are displayed in Table 1. In 1 aneurysm treated with GDC 10 coils, a stent was used; in aneurysms treated with Trufill coils, no stents were used.

Mean aneurysmal volume, packing, incomplete aneurysmal oc-



**Fig 2.** A 50-year-old woman with an incidentally discovered unruptured ophthalmic aneurysm. *A*, Lateral internal carotid angiogram demonstrates 9-mm ophthalmic aneurysm. *B*, After insertion of three 8 × 30 Nexus Morpheus coils, an adequate basket is formed. *C*, After failed attempt to deliver and withdrawal of a 7 × 30 Nexus Morpheus coil, coil loops of previous coils are protruding in the parent artery (arrow). *D*, Final result with coil loops in carotid artery. The patient received Aggrastat infusion for 48 hours, with good clinical outcome.

clusion at 6 months' follow-up angiography, and retreatment rates for Nexus coils were compared with both GDC 10 coils and Trufill coils. Differences were statistically analyzed with use of the unpaired *t* test for comparison of means and the  $\chi^2$  test for comparison of proportions. *P* values of less than .05 were considered significant.

## Results

### Initial Angiographic Results and Packing

Initial occlusion was (near) complete in 97 aneurysms and incomplete in 4. Mean aneurysmal volume was 180.2 mm<sup>3</sup> (median, 71 mm<sup>3</sup>; range, 5–1624 mm<sup>3</sup>). Mean packing was 19.4% (median, 18.3%; range, 7.5% to 38.9%). Anticoagulation after the procedure was prescribed in 42 (55%) of 77 ruptured aneurysms and in 18 (75%) of 24 unruptured aneurysms.

In 101 aneurysms, 426 Nexus coils were used (mean, 4.2; median, 3; range, 1–14). The 426 coils had a total length of 5776 cm, and total coil volume was 3088 mm<sup>3</sup>. Of 5776-cm total length of coils, 2775 cm (48%) was from helical coils, 2372 cm (41%) was from complex Morpheus coils, and 629 cm (11%) was from complex Tetris coils. Inserted coil length per mm<sup>3</sup> aneurysmal volume was 0.32 cm (total coil length 5776 cm/total aneurysmal volume 18,201 mm<sup>3</sup>).

### Clinical Complications

There were no complications leading to transient or permanent morbidity or mortality (0/95 patients, 0%; 97.5% CI,

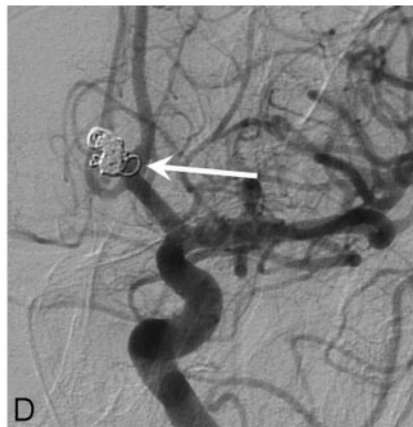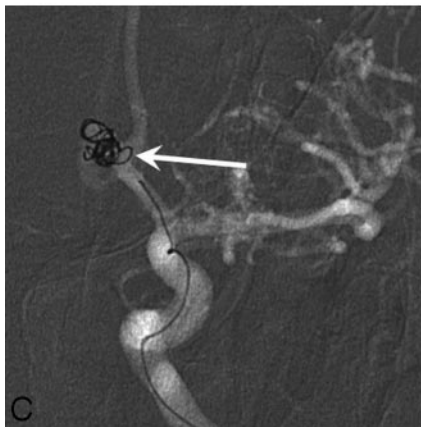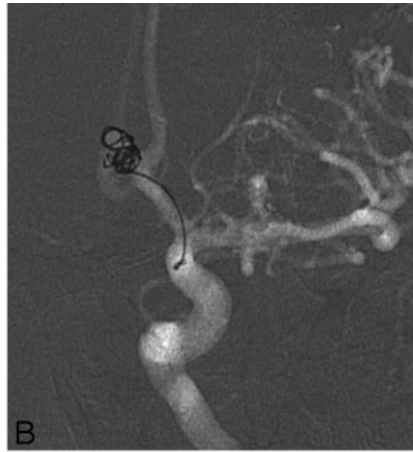
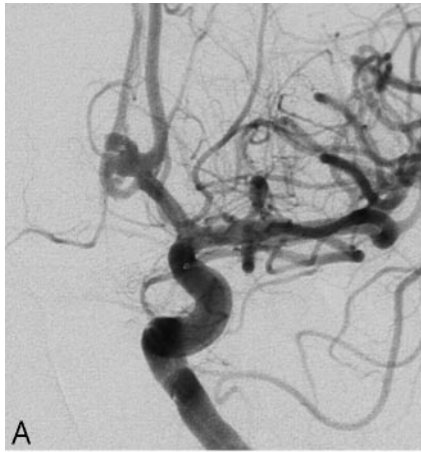0.0% to 3.3%). Procedural rupture occurred in 4 aneurysms, all without clinical sequelae.

### Technical Complications and Conversions

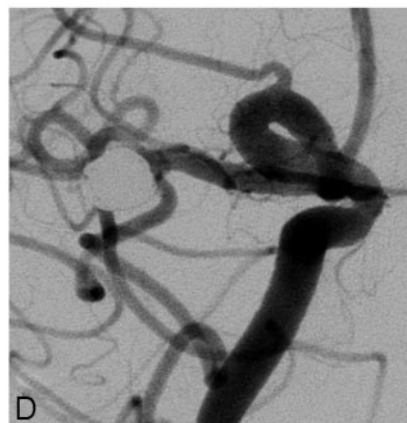
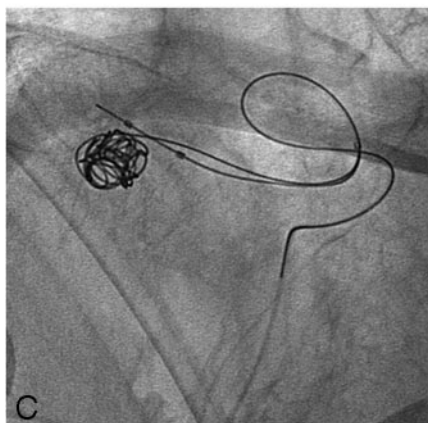
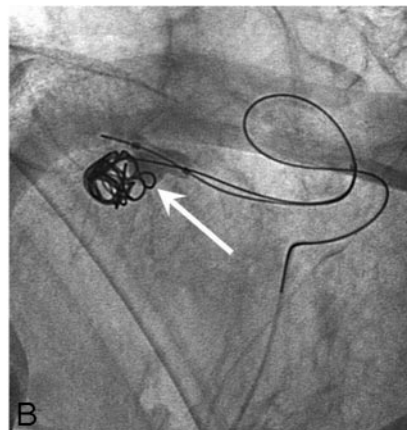
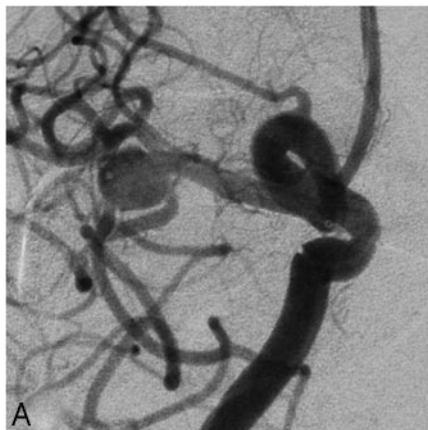Coil loops protruding from the aneurysm in the parent vessel occurred in 11 aneurysms, in 2 patients with angiographic visible formation of thrombus on the coils. Aggrastat infusion was administered in 7 of 11 patients. In all cases, malposition of coil loops occurred after correct placement of the first coil and was caused by insertion of additional coils that displaced loops of previously inserted coils (Figs 2 and 3).

In 4 aneurysms intended to be treated with Nexus coils, this proved impossible; therefore, these aneurysms were treated with other types of coils. In 2 wide-necked aneurysms (one 7-mm aneurysm in the middle cerebral artery and one 10-mm aneurysm in the anterior communicating artery) treated with balloon-assisted coiling, the first inserted Nexus coil did not retain its shape after insertion with balloon assistance but retook its original shape after the balloon was deflated, which resulted in protrusion of loops in the parent artery (Fig 4). Both aneurysms were treated with GDC 18 coils. In one 2-mm anterior communicating artery aneurysm, a 2-mm helical Nexus coil could not be delivered, so this aneurysm was treated with a 2-mm GDC 10 UltraSoft coil (Boston Scientific). Finally, because a 10-mm Nexus Morpheus coil first inserted in a 12-mm middle cerebral artery aneurysm could





**Fig 3.** A 62-year-old man with grade III SAH from anterior communicating artery aneurysm. *A*, Internal carotid angiogram shows bilobed 5-mm anterior communicating artery aneurysm. *B*, First coil (5 × 15-mm Morpheus) forms adequate basket. *C*, During insertion of the second coil (2 × 8-mm helical), suddenly a coil loop protruded in the parent artery (arrow). After withdrawal of this coil in the microcatheter, the protruding loop persisted, proving this was a displaced loop of the first coil. *D*, Final result with persisting protrusion of the coil loop (arrow). Aggrastat infusion was started, with good clinical outcome.



**Fig 4.** A 57-year-old woman with grade II SAH from a middle cerebral artery aneurysm. *A*, Internal carotid angiogram shows wide-necked 7-mm middle cerebral artery aneurysm. *B*, Adequate placement of the first coil (7 × 21-mm Morpheus) with assistance of HyperForm 7-mm balloon. *C*, After deflation of the balloon, there was expansion of the coil with protrusion into the parent artery. This coil was withdrawn. *D*, Final result after balloon-assisted treatment with GDC 18 coils.

**Table 2: Comparison of clinical results of Nexus PGLA microfilament coils with both GDC 10 and Trufill bare platinum coils**

	Nexus	GDC 10	Trufill	P Value Nexus-GDC 10/Nexus-Trufill
Mean aneurysmal volume (mm <sup>3</sup> )	180	128	162	.10/0.57
Mean packing (%)	19.4 (median, 18.3; range, 8–39)	22.9 (median, 21.8; range, 9–48)	29.7 (median, 29.6; range, 15–57)	< .0001/< .0001
Morbidity/mortality (%)	0/0	2.5/0.8	0.9/0	.18/.97*
Number of initial incompletely occluded aneurysms (%)	4 (4.0)	4 (3.5)	3 (2.6)	.87/.85
Incomplete aneurysm occlusion at 6 months	14 (17%) of 87	22 (22.2%) of 99	15 (15.8%) of 95	.43/.96
Number of retreatments	12 (11.9%) of 101	16 (13.3%) of 120	9 (7.8%) of 115	.91/.43
Number of incompletely occluded aneurysms at 6 months left untreated (%)	2 (2.0)	6 (5.0)	6 (5.2)	.41/.38

**Note:**—GDC indicates Guglielmi detachable coils; PGLA, polyglycolic/polylactic acid.

\* Combined morbidity/mortality compared.

not be placed satisfactorily, this aneurysm was treated with GDC 18 coils.

### Clinical Follow-Up

Clinical follow-up at 6 months was available for all patients. Of 77 patients with ruptured aneurysms, 7 died in the hospital of initial impact of SAH or vasospasm (GOS 1). Two patients were in a nursing home (GOS 3), 4 patients had nondisabling neurologic deficits (GOS 4) as a result of vasospasm, and 64 patients had good outcomes (GOS 5). All 18 patients with unruptured aneurysms were neurologically intact.

### Angiographic Follow-Up

Angiographic follow-up at 6 months was available for 82 patients with 87 (86%) aneurysms. Thirteen patients (with 14 aneurysms) had no follow-up angiography for the following reasons: death after SAH in 7, refusal in 5, and advanced age (78 years) in 1 patient with comorbidities. Occlusion status for 87 aneurysms at 6 months was (near) complete in 73 (84%) and incomplete in 14 (16%) aneurysms. Of 14 incompletely occluded aneurysms, 12 were additionally coiled. In 2 aneurysms, both 80% occluded, additional follow-up is scheduled. Overall rate of retreatment was 12% (12/101), and rate of retreatment for aneurysms with angiographic follow-up was 14% (12/87). Additional coiling was without complications.

### Comparison With Historical Data of Bare Platinum Coils

Results of comparison of Nexus-coated coils with GDC 10 coils and with Trufill coils are displayed in Table 2. Mean packing of 19.2% of Nexus coils was significantly lower than 22.9% of GDC 10 coils ( $P < .0001$ ) and 29.7% of Trufill coils ( $P < .0001$ ). All other parameters (including proportion of incompletely occluded aneurysms at follow-up and retreatment rates) were statistically not significantly different.

Procedural ruptures occurred in 4 aneurysms treated with Nexus coils, 6 aneurysms treated with Trufill coils, and 4 aneurysms treated with GDC 10 coils. Coil loop protrusion into the parent artery occurred in 11 aneurysms treated with Nexus coils and in none of the aneurysms treated with Trufill coils and GDC 10 coils.

### Discussion

In our study, we found that results of treating aneurysms with PGLA microfilament Nexus coils are similar to those of 2 types of standard bare platinum coils. A beneficial effect of PGLA addition on stability at follow-up could not be demonstrated. Nexus coils were safe to use: no neurologic complications occurred in 95 patients with 101 aneurysms. The slight, but significantly lower, packing of Nexus coils compared with both GDC 10 coils and Trufill coils had no significant effect on reopening and retreatment rates in this relatively small aneurysm group, though there was a trend to a lower retreatment rate for Trufill coils. Reopening of coiled aneurysms with time is not only dependent on packing but also on other factors such as aneurysmal size, neck width, and the presence of an intraluminal thrombus.

Technical complications occurred rather frequently, which, in our opinion, were predominantly related to the inner nitinol core of the coil, intended to make the coil resistant to compaction and stretch. Nitinol has the propensity to regain its original shape after being forced into a different shape. In clinical practice, this physical property of the coil resulted in displacement of loops of coils that were already inserted during placement of additional coils, which resulted in coil loops protruding in the parent artery (Figs 2 and 3). In our experience, we have not encountered this phenomenon with use of other types of bare platinum coils. In patients with coil loops protruding outside the aneurysm in the parent artery, we administered an intravenous infusion of a glycoprotein IIb/IIIa antagonist for 24 to 48 hours because Nexus coils have additional PGLA microfilaments with possible increased thrombogenicity. With this protocol, no permanent thromboembolic complications occurred.

Another disadvantage of the physical property of the nitinol core is the dire performance in balloon-assisted treatment. The first inserted Nexus coil usually did not retain its shape after insertion with balloon assistance but retook its original shape after the balloon was deflated, which resulted in protrusion of loops in the parent artery, thereby neutralizing the intended effect of balloon assistance (Fig 4). In these cases, treatment was continued with other types of coils, with good results.

The coil manufacturer (ev3) has recently introduced a new

range of coils of several thicknesses, from 0.0115 to 0.0145 inch, dependent on the diameter of the loop. This new coil, named *Axium*, is intended to replace the current available Nexus range. The Axium coil has no nitinol core and will be available as a bare platinum coil and as a microfilament coil with either PGLA or nylon.

In general, the results of our study are comparable with those of studies with other types of coils with PGLA addition such as Matrix and Cerecyte (Micrus Endovascular, San Jose, Calif) coils.<sup>8-18</sup> As in our study, a beneficial effect of PGLA regarding better stability at follow-up was absent or was not significant in previous studies.<sup>8-18</sup>

The important question is whether we should continue to use these PGLA coils to treat intracranial aneurysms. In our opinion,<sup>19-21</sup> supported by other authors,<sup>22-24</sup> the answer is clearly *no* for the following reasons. First, and most important, clinical results of coils with PGLA addition are not better than those of bare platinum coils. Second, in some PGLA-coated coils (Matrix), the coating modifies the physical properties of the coil, negatively affecting ease of handling. Third, PGLA-coated coils are more expensive. Large prospective randomized trials, instigated by coil manufacturers<sup>24</sup> comparing performance of PGLA coils and standard coils, are not warranted on the basis of current available data.

## Conclusion

PGLA microfilament Nexus coils are safe to use, with results comparable with those of standard platinum coils. Handling properties are not optimal: Displacement of coil loops with protrusion into the parent artery may occur, and coiling with balloon assistance is hampered by the propensity of the coil to retake its original shape. This study gives further evidence of a lack of beneficial effect of PGLA addition to reduce the re-opening rate of coiled intracranial aneurysms.

## References

1. Molyneux A, Kerr R, Stratton I, et al. International Subarachnoid Aneurysm Trial (ISAT) of neurosurgical clipping versus endovascular coiling in 2143 patients with ruptured intracranial aneurysms: a randomised trial. *Lancet* 2002;360:1267-74
2. Slob MJ, van Rooij WJ, Sluzewski M. The relation between packing and re-opening in coiled intracranial aneurysms: a prospective study. *Neuroradiology* 2005;47:942-45
3. Sluzewski M, van Rooij WJ, Slob MJ, et al. Relation between aneurysm volume, packing, and compaction in 145 cerebral aneurysms treated with coils. *Radiology* 2004;231:653-58

4. van Rooij WJ, Sprengers ME, Sluzewski M, et al. Intracranial aneurysms that repeatedly reopen over time after coiling: imaging characteristics and treatment outcome. *Neuroradiology* 2007;49:343-49
5. Murayama Y, Tateshima S, Gonzalez NR, et al. Matrix and bioabsorbable polymeric coils accelerate healing of intracranial aneurysms: long-term experimental study. *Stroke* 2003;34:2031-37
6. Matrix Newsletter 2004, Boston Scientific, Fremont, Calif
7. Slob MJ, van Rooij WJ, Sluzewski M. Influence of coil thickness on packing, re-opening and retreatment of intracranial aneurysms: a comparative study between two types of coils. *Neurol Res* 2005;27 Suppl 1:S116-19
8. Taschner CA, Leclerc X, Rachdi H, et al. Matrix detachable coils for the endovascular treatment of intracranial aneurysms: analysis of early angiographic and clinical outcomes. *Stroke* 2005;36:2176-80
9. Linfante I, Akkawi NM, Perlow A, et al. Polyglycolide/poly(lactide)-coated platinum coils for patients with ruptured and unruptured cerebral aneurysms: a single-center experience. *Stroke* 2005;36:1948-53
10. Katsaridis V, Papagiannaki C, Violaris C. Guglielmi detachable coils versus Matrix coils: a comparison of the immediate posttreatment results of the embolization of 364 cerebral aneurysms in 307 patients: a single-center, single-surgeon experience. *AJNR Am J Neuroradiol* 2006;27:1841-48
11. Rivet DJ, Moran CJ, Mazumdar A, et al. Single-institution experience with Matrix coils in the treatment of intracranial aneurysms: comparison with same-center outcomes with the use of platinum coils. *AJNR Am J Neuroradiol* 2007;28:1736-42
12. Fiorella D, Albuquerque FC, McDougall CG. Durability of aneurysm embolization with Matrix detachable coils. *Neurosurgery* 2006;58:51-59
13. Niimi Y, Song J, Madrid M, et al. Endosaccular treatment of intracranial aneurysms using Matrix coils: early experience and midterm follow-up. *Stroke* 2006;37:1028-32
14. Kang HS, Han MH, Kwon BJ, et al. Short-term outcome of intracranial aneurysms treated with polyglycolic acid/lactide copolymer-coated coils compared to historical controls treated with bare platinum coils: a single-center experience. *AJNR Am J Neuroradiol* 2005;26:1921-28
15. Pierot L, Bonafé A, Bracard S, et al. Endovascular treatment of intracranial aneurysms with Matrix detachable coils: immediate posttreatment results from a prospective multicenter registry. *AJNR Am J Neuroradiol* 2006;27:1693-99
16. Pierot L, Leclerc X, Bonafé A, et al. Endovascular treatment of intracranial aneurysms with Matrix detachable coils: midterm anatomic follow-up from a prospective multicenter registry. *AJNR Am J Neuroradiol* 2008;29:57-61
17. Bendszus M, Solymosi L. Cerecyte coils in the treatment of intracranial aneurysms: A preliminary clinical study. *AJNR Am J Neuroradiol* 2006;27:2053-57
18. Butteriss D, Gholkar A, Mitra D, et al. Single-center experience of Cerecyte coils in the treatment of intracranial aneurysms: initial experience and early follow-up results. *AJNR Am J Neuroradiol* 2008;29:53-56
19. Sluzewski M, van Rooij WJ. Questionable interpretation of results of ACTIVE study on Matrix coils by Boston Scientific [letter]. *AJNR Am J Neuroradiol* 2005;26:1882-83
20. Sluzewski M, van Rooij WJ. Reply to letter regarding interpretation of results of ACTIVE Study. *AJNR Am J Neuroradiol* 2005;26:2436-37
21. van Rooij WJ, Sluzewski M. Registry on Matrix coils: bias in inclusion, exclusion, and publication. *AJNR Am J Neuroradiol* 2007;28:398-99
22. Cloft HJ. Have you been smoking something that is biologically active? *AJNR Am J Neuroradiol* 2006;27:240-42
23. Cloft HJ. Matrix reloaded. *AJNR Am J Neuroradiol* 2008;29:62
24. Kallmes DF, Cloft HJ. Ready or not, here they come: randomized trials evaluating new endovascular aneurysm therapies. *AJNR Am J Neuroradiol* 2007;28:799-803