

**Are your MRI contrast agents cost-effective?**  
Learn more about generic Gadolinium-Based Contrast Agents.



**AJNR**

**CT of nasal chondrosarcoma.**

E F Downey, Jr, A C Friedman and J Finizio

*AJNR Am J Neuroradiol* 1982, 3 (1) 80-81  
<http://www.ajnr.org/content/3/1/80.citation>

This information is current as  
of April 18, 2024.

## CT of Nasal Chondrosarcoma

Edward F. Downey, Jr.,<sup>1</sup> Arnold C. Friedman,<sup>2</sup> and Joseph Finizio<sup>3</sup>

Chondrosarcomas rarely occur in the nose and paranasal sinus. Furthermore, because they cause minimal symptoms, the tumors are often discovered only after they have reached considerable size. Although plain radiographs of the nasal cavity are often difficult to interpret, and the extent of the lesion can be inferred only from adjacent bone involvement with pluridirectional tomography, computed tomography (CT) is ideally suited for evaluating this area [1]. Not only is CT easier to perform than pluridirectional tomography, but CT accurately shows the extent and destructiveness of a mass, occasionally enables a preoperative diagnosis to be made, and detects minimal changes on follow-up studies. We report the CT findings in two cases of chondrosarcoma of nasal cavity.

### Case Reports

#### Case 1

A previously healthy, 64-year-old man had a 2 month history of painless swelling in the left medial orbital region. There was increased tearing of the left eye and an 8–10 year history of anosmia. Sinus films demonstrated opacification of the ethmoid, frontal, and sphenoid sinuses as well as expansion of the bony rim of the ethmoids bilaterally (fig. 1A). A dacrocystogram showed obstruction of the left lacrimal duct. CT demonstrated a large mass extending from the left medial canthal region to the superior nasal region bilaterally. Erosion and expansion of the medial left orbital rim and expansion of ethmoid walls with sclerosis were noted as well as scattered areas of calcification throughout the mass (figs. 1B and 1C). Biopsy revealed a chondrosarcoma and the patient underwent bilateral frontoethmoidectomy, sphenoidectomy, and resection of the posterior nasal septum. The mass could not be completely resected, and residual tumor was left at the inferior floor of the nose. The patient's postoperative course was uneventful.

#### Case 2

A previously healthy, 56-year-old man had nasal blockage and difficulty breathing. CT revealed a mass containing scattered areas of calcification involving the posterior nasal cavity (fig. 2). Biopsy

revealed a chondrosarcoma, and left lateral rhinotomy and septoplasty removed the bulk of the tumor. The patient's postoperative course was uneventful and radiation therapy was begun.

### Discussion

Chondrosarcoma of the nose, paranasal sinuses, or nasopharynx is extremely rare. In two series of patients seen at the Mayo Clinic over a 68 year period (1907–1975), only 18 cases were reported [2, 3]. Review of the Japanese literature revealed only eight cases [4]. In addition, there have been several scattered case reports [5–9]. In all these cases most patients were in the fifth or sixth decade of life with occurrence in men slightly more common than women. These tumors tend to be slow-growing, cartilaginous masses that displace local structures before invading them; they remain relatively asymptomatic because they do not become inflamed or ulcerated. For these reasons chondrosarcomas tend to be quite large when discovered.

Several methods can be used to investigate the nasal cavity including plain radiographs, pluridirectional tomography, angiography, contrast nasopharyngography, and CT. On plain films, calcifications are seen within chondrosarcomas in more than 50% of cases [10]. Bony destruction or expansion can also usually be seen on plain films. However, the extent of a lesion is often not well appreciated. CT should be the next study because it yields the most information; it has largely supplanted the other studies mentioned for investigation of lesions in the nasal area [11]. CT will give an accurate determination of the extent of the tumor, which is extremely important to the surgeon and/or radiation therapist. Block excision apparently is curative when the entire tumor is removed during the initial surgery, but if a tumor focus remains, local recurrences are inevitable [2]. Of the 18 patients in the Mayo Clinic series, six died within 10 years of their disease despite multiple excisions and radiotherapy [2, 3].

CT provides an effective means of follow-up, and early asymptomatic recurrence of the chondrosarcoma may be

Received March 9, 1981; accepted July 5, 1981.

The views expressed here are those of the authors and do not necessarily reflect those of the Department of the Navy or the Department of Defense.

<sup>1</sup>Department of Radiology, National Naval Medical Center, Bethesda, MD 20014. Address reprint requests to E. F. Downey, Jr.

<sup>2</sup>Department of Radiology, Uniformed Services University of the Health Sciences, Bethesda, MD 20014.

<sup>3</sup>Department of Radiology, Southern Maryland Medical Center, Clinton, MD 20735.



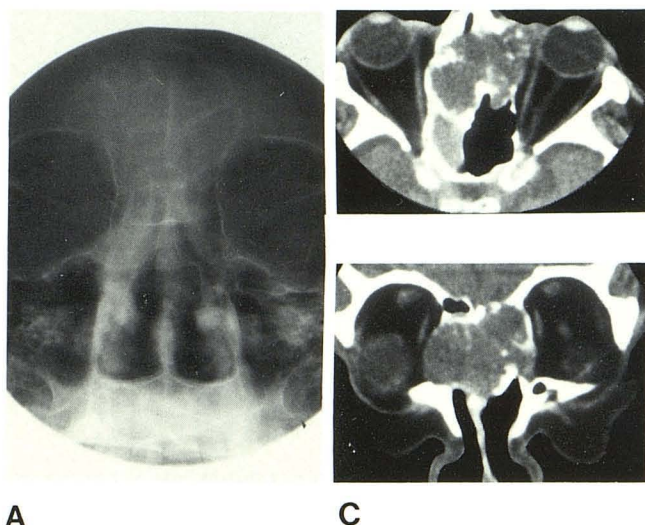


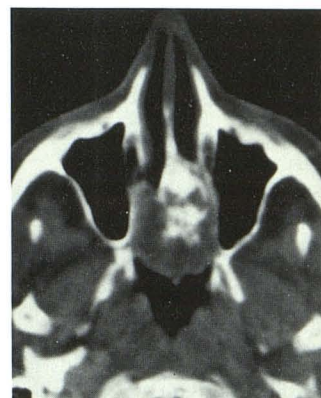Fig. 1.—Case 1. **A**, Anteroposterior sinus film. Opacification of ethmoid and frontal sinuses. Expansion of bony rim of ethmoid sinuses. **B**, Axial scan. **C**, Coronal scan. Mass involves ethmoid, sphenoid, and frontal sinuses. Scattered intratumoral calcifications, expansion of ethmoid bony walls, and erosion of both lamina papyracea, particularly on left.

detected enabling a second definitive procedure to be performed. In view of previous reports, a reasonable follow-up schedule might be to obtain scans 1 and 6 months postoperatively and then yearly if there is no evidence of recurrence.

In only two other cases was CT mentioned as useful in determining the extent of a chondrosarcoma in the nasal region [2, 12]. Both cases had CT findings similar to our two cases, that is, intratumoral calcification and expansion of the bony walls. Probably the most important point in the diagnosis of chondrosarcoma is the presence of intratumoral calcification of the chondroid matrix. Tumoral chondroid calcification can be differentiated from bone fragments in that it is scattered throughout the tumor with no relation to the position of normal bony structures. When chondrosarcomas metastasize, it is late in their course, while other primary malignant tumors of the nasopharynx often show cervical adenopathy as the initial clinical finding [13]. Neither patient in this report had any evidence of metastases. Another useful radiologic sign is that chondrosarcomas, being slow growing, often expand rather than destroy bone; other malignancies of this region such as squamous cell carcinomas, lymphomas, or metastases tend to destroy adjacent bone due to their rapid growth. However, when chondrosarcomas become aggressive they may erode bony walls, as in case 1.

CT is the most useful radiographic examination for masses in the nasal region. When a relatively large mass is seen that has calcifications, evidence of bone expansion rather than destruction, minimal symptoms, and no evidence of

Fig. 2.—Case 2. Axial scan. Mass involves posterior nasal cavity and nasopharynx, with intratumoral calcifications and expansion of bony walls.



metastasis, then chondrosarcoma—despite its rarity—should be strongly considered as the diagnosis.

#### ACKNOWLEDGMENT

We thank Anne Brower for reviewing the manuscript.

#### REFERENCES

- Hesselink JR, New PFJ, David KR, Weber AL, Roberson GH, Taveras JM. Computed tomography of the paranasal sinuses and face: part I. Normal anatomy. *J Comput Assist Tomogr* 1978;2:559-567
- Coates HL, Pearson BW, Devine KD, Unni KK. Chondrosarcoma of the nasal cavity, paranasal sinuses and nasopharynx. *Trans Am Acad Ophthalmol Otolaryngol* 1977;84:919-926
- Kraph LV, Dahlin DC, Erich JB. Cartilaginous tumors of the jaws and facial region. *Am J Surg* 1960;99:852-856
- Sato K, Nukaga H, Horikoshi T. Chondrosarcoma of the jaws and facial skeleton. A review of the Japanese literature. *J Oral Surg* 1977;35:892-897
- Gray R, Leonard G. Chondrosarcoma of the nasal septum. *J Laryngol Otol* 1977;91:427-431
- Aretsky PJ, Kantu K, Freund HR, Polisor IA. Chondrosarcoma of the nasal septum. *Ann Otol Rhinol Laryngol* 1970;79:382-388
- Coyas AJ. Chondrosarcoma of the nose. *J Laryngol Otol* 1965;79:69-72
- Lawson LJ. Intranasal chondrosarcoma. *Arch Otolaryngol* 1956;64:331-334
- Soboroff BJ, Lederer FL. Chondrosarcoma of the nasal cavity. *Ann Otol Rhinol Laryngol* 1955;64:718-727
- Buhr GL, Gayler BW. Cranial chondrosarcomas. *Radiology* 1977;124:151-156
- Bohman L, Mancuso A, Thompson J, Hanefee W. CT approach to benign nasopharyngeal masses. *AJNR* 1980;1:513-520
- Hesselink JR, New PFJ, Davis KR, Weber AL, Roberson GH, Taveras JM. Computed tomography of the paranasal sinuses and face: part II. Pathological anatomy. *J Comput Assist Tomogr* 1978;2:568-576
- Elie G, Vazel P, Renaud-Salis JR, Guibert-Tranier F, LeTrent A, Caille JM. CT of primary malignant tumors of the nasopharynx. *Comput Tomogr* 1980;4:235-241