

Are your **MRI contrast agents** cost-effective?

Learn more about generic **Gadolinium-Based Contrast Agents**.



FRESENIUS
KABI

caring for life

AJNR

New Perspectives in Computed Tomography of Multiple Sclerosis

F. V. Viñuela, A. J. Fox, G. M. Debrun, T. E. Feasby and G. C. Ebers

AJNR Am J Neuroradiol 1982, 3 (3) 277-281

<http://www.ajnr.org/content/3/3/277>

This information is current as of April 19, 2024.

New Perspectives in Computed Tomography of Multiple Sclerosis

F. V. Viñuela¹
A. J. Fox¹
G. M. Debrun^{1,2}
T. E. Feasby³
G. C. Ebers³

A prospective clinical study was performed in 70 consecutive patients with known or strong clinical suspicion of acute or relapsing multiple sclerosis. The study was designed to compare the results of standard computed tomography and high-volume contrast-delayed scanning for the detection of enhancing lesions. In 39 cases with clinically definitive multiple sclerosis, the conventional enhanced scan was positive in 25 cases and the high-volume delay scan in 32. The high-volume enhanced scan added information in 23 of these 32 cases. In 21 cases, suspicious of multiple sclerosis but not clinically confirmed, the standard enhanced scan was positive in two cases and the high-volume delay scan in five. In these cases, computed tomography was definitive in establishing the diagnosis by showing clinically unsuspected brain lesions. In 10 cases in which the disease was eventually excluded, the scans were negative in all instances. For the first time, by the high-volume delayed technique, enhancing plaques in the cortical gray matter and in the gray/white matter regions were demonstrated. This technique is a very useful diagnostic tool, not only for morphologic assessment when multiple sclerosis is known, but for the positive diagnosis of this disease when the first clinical presentation is diagnostically uncertain.

Neuroradiologic studies in patients with suspected multiple sclerosis (MS) have been traditionally used mainly for exclusion of other pathology. With the introduction of computed tomographic (CT) scanning of the brain, specific details of the gray and white matter can now be evaluated. It is well known that MS has several different CT appearances in patients with clinical evidence of cerebral involvement [1-4]. The CT scan may be normal or it may show focal lesions with or without evidence of atrophy [1-6].

It is presumed that MS demyelinating plaques produce a "mild" blood-brain barrier (BBB) disruption, as manifested by a relatively slight elevation of cerebrospinal fluid (CSF) protein. On the basis of that premise, it was thought that a prolonged exposure of MS lesions to a high-volume sustained blood-iodine level (3-6 mg/dl) and delayed scanning might depict areas of enhancement in zones of BBB disruption not visible on standard CT.

The high-volume delayed (HVD) scan was originally described by Hayman et al. [7-9] for the assessment of other intracranial diseases. The potential usefulness of this technique for the assessment of MS was also suggested by Prendes [10] and Davis et al. [11].

Subjects and Methods

Using a protocol set up at University Hospital, University of Western Ontario, we examined 70 patients with known or strong clinical suspicion of early acute or relapsing MS during a period of 14 months. Each of the 70 patients was scanned before contrast medium infusion. Then, 100 ml of Conray 400 (40 g iodine) were administered intravenously as a bolus injection. Immediate contrast CT scans were obtained. On completion of these scans, an additional rapid drip of 300 ml of Hypaque 30 (42 g iodine) was given. The HVD

This article appears in the May/June 1982 issue of *AJNR* and the July 1982 issue of *AJR*.

Received August 21, 1981; accepted after revision February 1, 1982

¹ Department of Diagnostic Radiology, Neuro-radiology Section, University Hospital, 339 Windermere Rd., London, Ontario, Canada N6A 5A5. Address reprint requests to F. V. Viñuela.

² Present address: Department of Diagnostic Radiology, Massachusetts General Hospital, Boston, MA 02114.

³ Department of Clinical Neurological Sciences, University Hospital, London, Ontario, Canada N6A 5A5.

scans were obtained 1 hr after the rapid drip infusion. None of these patients had diabetes or elevated creatinine levels. No relevant neurologic or systemic side effects after contrast medium infusion (82 g iodine) were detected.

All these studies were done on a GE 8800 scanner using a 9.6 sec, high-resolution mode. Similar window settings were used for filming the standard and the high-volume delayed scans. The CT scans were evaluated by two staff neuroradiologists. Special attention was given to differences in information obtained in the high-volume delayed scan when compared with the standard dose scan.

Results

Patients were divided into three groups, depending on their eventual diagnosis, on the basis of standard clinical and laboratory information.

TABLE 1: CT Findings in 70 Patients Examined for Multiple Sclerosis

	Definite Disease (n = 39)	Suspicious Disease (n = 21)	Disease Excluded (n = 10)
Normal	7	16	10
Abnormal:			
Nonenhanced scan	20	1	0
Standard enhanced scan	25	2	0
High-volume delayed scan	32	5	0

Group 1: Definite Multiple Sclerosis

In 39 cases having definitive clinical and laboratory evidence of MS, the CT scan was positive in 32 cases (82%) and normal in seven (18%) (table 1). The criteria of Schumacher et al. [12] were used for the clinical diagnosis and the laboratory criteria were the CSF electrophoretic changes described by Ebers and Paty [13].

In the 32 CT-positive cases, the nonenhanced scan was abnormal in 20, the conventional enhanced scan was abnormal in 25, and the HVD showed enhancing lesions in all 32. The latter technique showed important additional information in 23 (72%) of these cases. This additional information was: (1) reinforcement of equivocal findings on standard CT scan in 17 cases (fig. 1); (2) enhancement of low-density plaques not enhanced on standard CT in 13 cases (fig. 2); (3) enhancement of isodense plaques not enhanced on standard CT in nine cases (fig. 3); and (4) perception of low-density plaques not discernible on standard CT in four cases (fig. 4). In none of the 32 positive cases was less information observed by HVD scanning than by conventional scanning.

Group 2: Suspected Multiple Sclerosis

In the 21 cases of suspicious but not clinically confirmed intracranial MS, CT was positive in five. In these five cases,

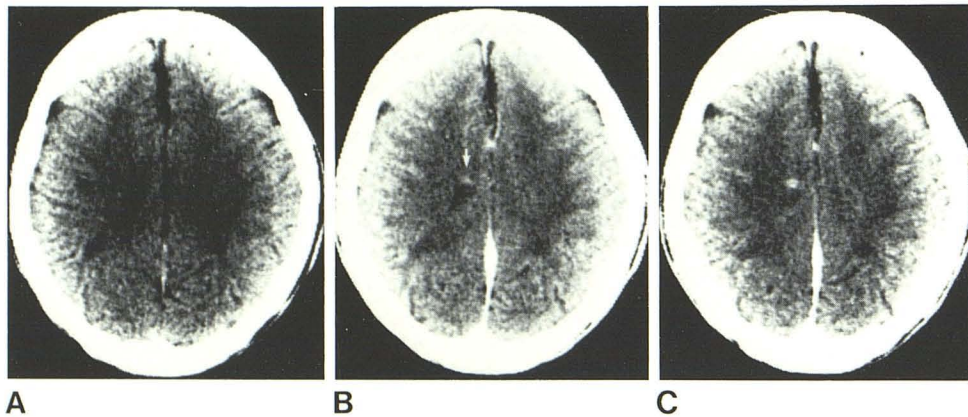


Fig. 1.—Questionable enhancement on standard CT, reinforced on high-volume delay scan. **A**, Noncontrast axial scan. Low-density lesions in both central semiovale. **B**, Standard contrast scan. Small area of enhancement difficult to differentiate from cortical vessel (arrow). **C**, Definitive enhancing plaque in right centrum semiovale with HVD.

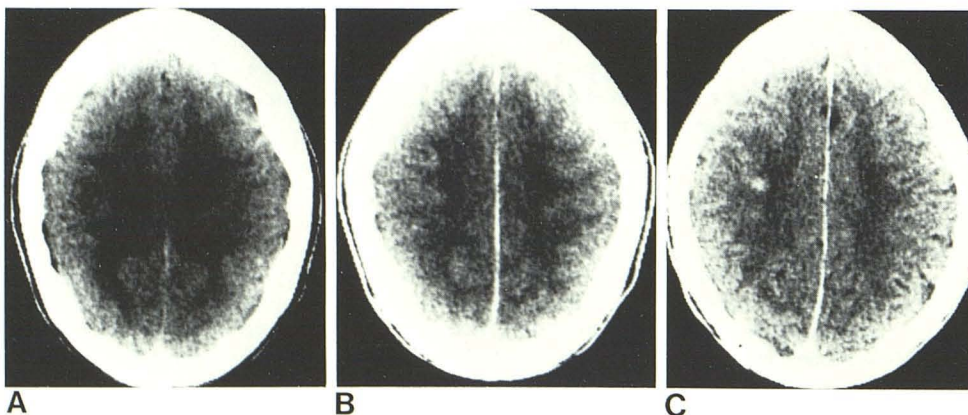


Fig. 2.—Enhancement of low-density plaque on high-volume delay scan. **A**, Poorly defined low-density lesions in both centra semiovale. **B**, Standard contrast scan. No abnormal enhancement. **C**, Enhancing lesion in right centrum semiovale.

Fig. 3.—Enhancement of isodense plaque on high-volume delay scan. Normal standard nonenhanced (A) and enhanced (B) scans. C, Marked enhancement of right centrum semiovale isodense on HVD.

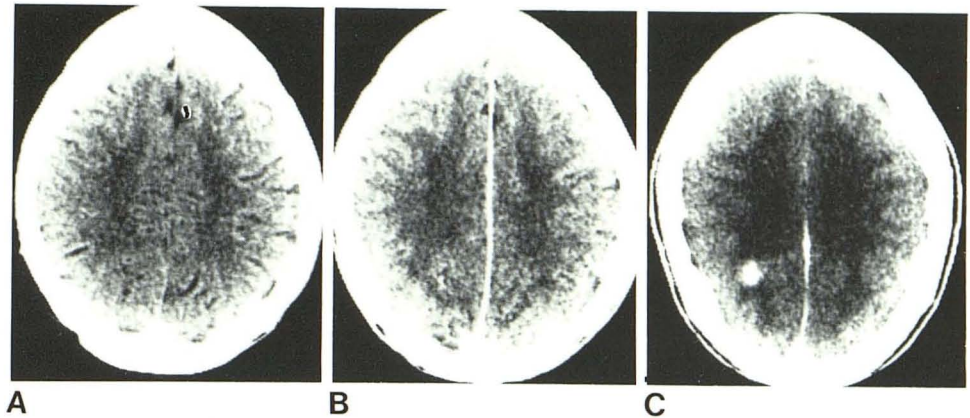


Fig. 4.—Low-density plaque seen only on high-volume delay scan. Normal standard nonenhanced (A) and enhanced (B) scans. C, HVD scan. Left centrum semiovale well defined low-density lesion (arrow). Normal enhancement of surrounding white matter delineates plaque.

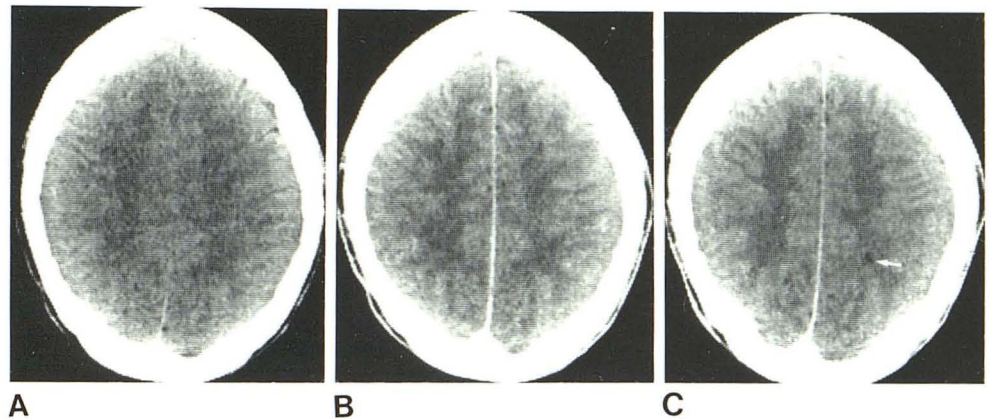
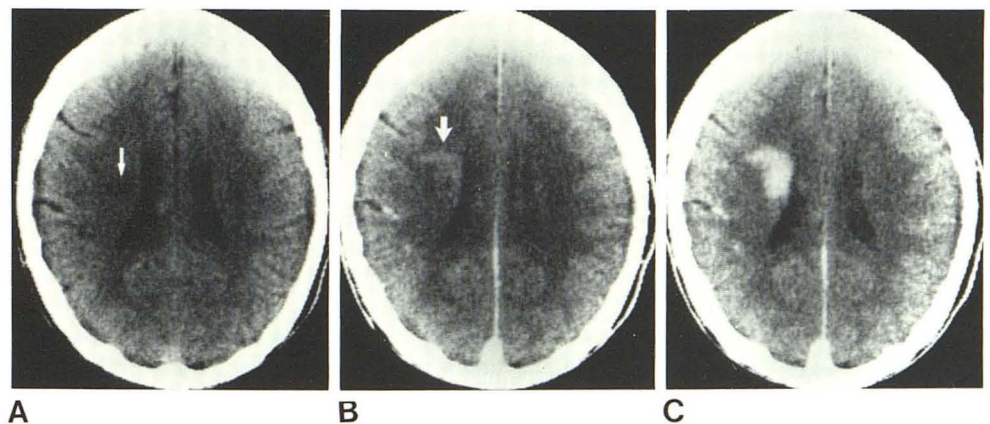


Fig. 5.—Clinical diagnosis of acute transverse myelitis. Localized enlargement of midthoracic cord was seen on metrizamide myelography. A, Nonenhanced scan. Low-density lesion (arrow). B, Standard enhanced scan. Lesion enhances (arrow). C, HVD enhancing scan. Large enhancing lesion in right corona radiata compatible with MS.



the nonenhanced scan was abnormal in one case, the standard enhanced scan was abnormal in two, and the high-volume delayed (HVD) scan showed enhancing lesions in all five.

All the CT-positive cases also had positive oligoclonal bands in the CSF. It is noteworthy that the intracranial lesions detected by CT were unsuspected and spatially separated from the clinical topographic diagnosis (figs. 5 and 6). Among these five cases were three cases of trans-

verse myelitis, one case of optic neuritis, and one case of a clinical single brain lesion. Again, HVD showed important additional information in these cases (figs. 5 and 6).

The other 16 cases with negative CT scans showed a wide spectrum of single or multiple neurologic symptoms such as gait ataxia, bilateral optic atrophy, bilateral internuclear ophthalmoplegia, generalized parathesia, bilateral/lateral gaze nystagmus, etc. This group of patients remains undiagnosed.

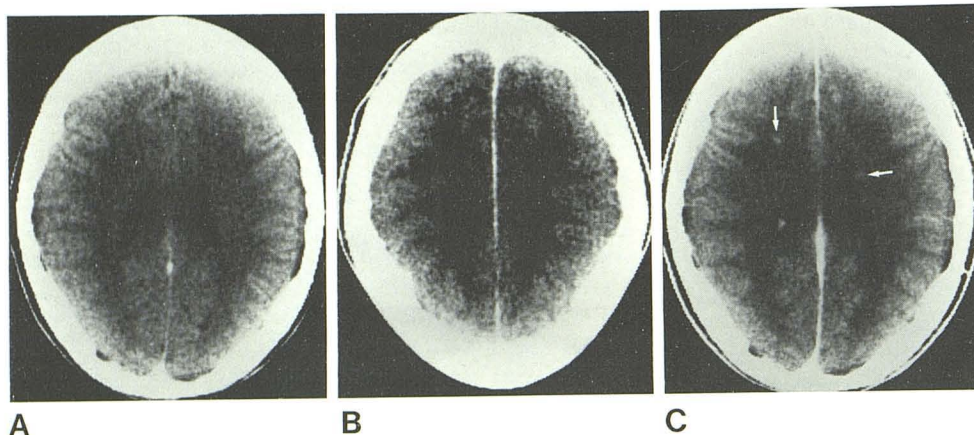


Fig. 6.—Clinical diagnosis of acute optic neuritis. Standard noncontrast (A) and contrast (B) scans were negative. C, HVD. Small enhancing lesions in right centrum semiovale and left caudate nucleus adjacent to lateral ventricular wall (arrows).

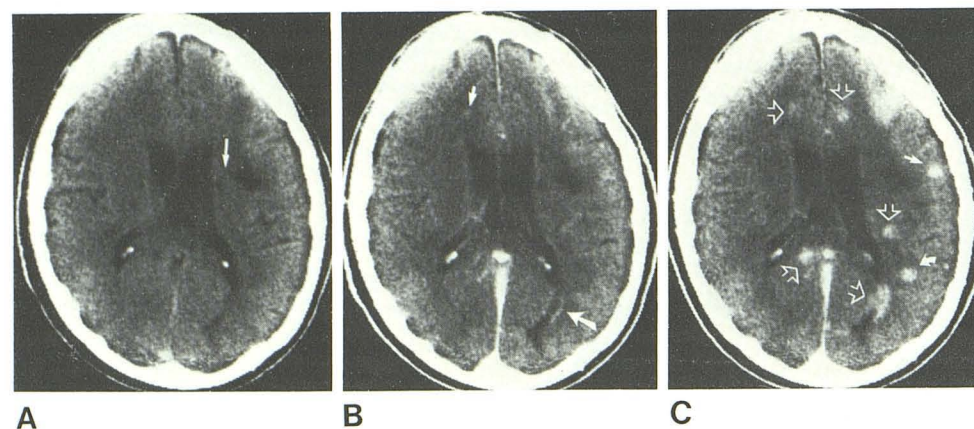


Fig. 7.—Cortical and subcortical multiple sclerosis. A, Noncontrast scan. Small low-density lesion in left corona radiata (arrow). Large well defined low-density lesion lateral to it. B, Standard contrast scan. Questionable enhancement in right frontal white matter (small arrow). Definitive though mild enhancement in left occipital white matter (large arrow). No enhancement in low-density lesion. C, HVD scan. Enhancing plaques in cortical gray matter (closed straight arrow), gray/white matter junction (curved arrow), and deep white matter (open arrows).

Group 3: Multiple Sclerosis Excluded

In the 10 patients in whom MS was eventually clinically excluded, CT scans of all types were negative in all cases.

Discussion

Evidence that CT is a valuable diagnostic tool in MS has been extensively reported [1, 2, 4–6, 9, 14, 15]. CT scans have been an important source of anatomic/morphologic information in patients with known disease. Enhancing white matter lesions have been described in these patients. In most reports, a relatively low rate of enhancing lesions has been demonstrated: 24.5% [4], 20.8% [6], 9% [15], and 12.5% [16]. Our detection rate of enhancing lesions is substantially higher than that described previously. This discrepancy may be explained by two factors: (1) all our patients were in a state of early acute or relapsing MS and (2) we used HVD scanning.

HVD demonstrated additional MS enhancing lesions in 23 of the 32 positive cases, and it offered a positive diagnosis in nine cases (seven cases in group 1 and two cases in group 2), in which the standard CT scans had been interpreted as normal or as showing no evidence of active disease.

HVD demonstrated areas of enhancement produced by blood-brain barrier disruption [17, 18] in low-density or isodense MS plaques that were not seen on standard CT. We also observed enhancing MS plaques in the cerebral cortical and cortical/subcortical regions (fig. 7). These findings are well known to neuropathologists [19, 20], but to our knowledge they have not been reported before in the CT literature of MS. There were strong positive clinical/CT correlations in our acute or relapsing cases of MS reinforcing the concept that the areas of enhancement are probably acute demyelinating plaques. Ultimate certainty will require comparison of the CT enhancing lesions and the corresponding biopsies or postmortem histology.

It is important to emphasize the essential role played by CT in the group of patients in whom MS was only suspected but not clinically confirmed using standard criteria. In such patients, CT suggested the diagnosis of MS by showing clinically silent and spatially separated central nervous system (CNS) lesions. Even at the time of the first clinical presentation of a single lesion such as optic neuritis (fig. 6), transverse myelitis (fig. 5), or a single intracranial asymptomatic plaque, CT scanning showed additional lesions that were helpful in diagnosing the disease. CT should be added to the list of laboratory studies that can aid in the diagnosis of MS.

On the basis of our experience, we regard the high-volume delayed (HVD) CT scan as the examination of choice for the detection of MS enhancing lesions. It not only increases the number of enhancing lesions detected by standard CT but demonstrates new lesions with a topography otherwise rarely observed, that is, cortical gray matter and gray matter/white matter junction. It may suggest the diagnosis by showing clinically silent and spatially separated CNS lesions. The sequential use of CT scanning may help in understanding the morphologic evolution of enhancing, "active" MS plaques and the effects of treatment on them.

REFERENCES

1. Cole M, Ross RH. Plaques of MS seen on computerized transaxial tomograms. *Neurology (NY)* **1977**;27:890-891
2. Byldensted C. Computer tomography of the cerebrum in multiple sclerosis. *Neuroradiology* **1976**;12:33-42
3. Jacobs L, Kinkel WR. Computerized axial transverse tomography in multiple sclerosis (abstr). *Neurology (NY)* **1976**;26:390-391
4. Weinstein M, Lederman R, Rothner D, et al. Interval computed tomography in MS. *Radiology* **1978**;129:689-694
5. Haughton VM, Ho KC, Williams A, Eldevik OP. CT detection of demyelinated plaques in MS. *AJR* **1979**;132:213-215
6. Mikol F, Bouchareine A, Aubin ML, Vignaud J. La Tomodensitométrie dans la sclérose en plaques. *Rev Neurol (Paris)* **1980**;6:481-490
7. Hayman LA, Evans RA, Hinck VC. Rapid high dose (RHD) contrast computed tomography of perisellar vessels. *Radiology* **1979**;131:121-123
8. Hayman LA, Evans RA, Hinck VC. Rapid high dose contrast computed tomography of isodense subdural hematoma and cerebral swelling. *Radiology* **1979**;131:381-383
9. Hayman LA, Evans RA, Hinck VC. Rapid high dose (RHD) contrast cranial computed tomography: a concise review of normal anatomy. *J Comput Assist Tomogr* **1979**;3:12:147-154
10. Prendes JL. Letter to the editor. *Arch Neurol* **1981**;38:67-68
11. Davis J, Davis K, Newhouse J. Expanded high iodine dose in computed cranial tomography; a preliminary test report. *Radiology* **1979**;131:372-380
12. Schumacher GA, Beebe G, Kibler RF, et al. Problems of experimental trials of therapy in multiple sclerosis: report by the panel of the evaluation of experimental trials of therapy in multiple sclerosis. *Ann NY Acad Sci* **1973**;122:552-568
13. Ebers GC, Paty DW. CSF electrophoresis in one thousand patients. *Can J Neurol Sci* **1980**;7:275-280
14. Huckman M, Fox J, Ramsey R. Computed tomography in the diagnosis of degenerative diseases of the brain. *Semin Roentgenol* **1977**;12:63-76
15. Hersey LA, Gado MH, Trotter JL. Computerized tomography in the diagnostic evaluation of multiple sclerosis. *Ann Neurol* **1979**;5:32-39
16. Radve EW, Kendall BE. Iodide and xenon enhancement of CT in MS. *Neuroradiology* **1978**;15:153-158
17. Wuthrich R, Gigli H, Wiggli V, Muller HR. *CT scanning in demyelinating disease for cranial computerized tomography*. Berlin: Springer, **1976**:239-243
18. Broman T. Blood-brain barrier damage in MS: supravital test observation. *Acta Neurol Scand* **1964**;40:21-24
19. Blackwood W, McMenemey WH, Meyer A, Norman RM. *Greenfield's neuropathology*, 3d ed. Chicago: Yearbook Medical, **1976**
20. Escourrolle R, Poirier J. *Manual of basic neuropathology* (transl). Philadelphia: Saunders, **1973**