AJNR

Calcified brain metastases: demonstration by computed tomography.

A K Anand and D G Potts

AJNR Am J Neuroradiol 1982, 3 (5) 527-529
http://www.ajnr.org/content/3/5/527.citation

Calcified Brain Metastases:
Demonstration by Computed Tomography

Azad K. Anand[1, 2]
D. Gordon Potts[1]

Seven patients are reported with calcification in brain metastases. The calcification was punctate, curvilinear, or amorphous and sometimes closely simulated a hemorrhage. The attenuation values were 50–105 Hounsfield units before administration of contrast material. Although various degrees of contrast enhancement were noted in the noncalcified parts of the metastases, slight or no enhancement was seen in the regions of calcification. The primary tumors were: colon (two cases), lung (two cases), breast (one case), esophagus (one case), and both breast and lung (one case).

Calcification is seen in 9.3% of brain gliomas by conventional radiography [1]. However, calcification in brain metastases in conventional radiographs has only been reported in a small number of cases [2, 3]. A total of 136 patients with brain metastases were studied by Potts and Svare [3]. Although nine showed histologic evidence of tumor calcification, only two showed calcification on plain skull radiography. In the series studied by Griffiths [2], 91 patients had metastatic lesions; one patient with a silent bronchial carcinoma showed calcification in the brain metastasis. The calcification was described as "fairly dense and almost linear." A subsequent autopsy confirmed that the calcification was lying in the necrotic part of the lesion.

Although calcification was only rarely demonstrated by conventional radiographic techniques, it is predictable that, because of its greatly superior contrast resolution, computed tomography (CT) would demonstrate calcification in metastases more often.

Materials and Methods

The patients reviewed had been studied by CT scanning at New York Hospital during an 8 month period and had a known primary tumor and one or more cerebral metastases. In seven cases there was evidence of calcification in the metastatic lesions. A solitary lesion was surgically explored and excised in one case (case 5).

CT was performed on a GE 8800 scanner using 300 mAs and 120 kV. Scans were obtained before intravenous administration of contrast material and immediately after an intravenous bolus injection of 100 ml of Conray 60. Follow-up scans were obtained in one case at 3 and 5 months after the initial scan (fig. 1). In the preenhancement scans showing hyperdense lesions, the highest density was recorded. The lowest attenuation value within the hyperdense lesions was also recorded. Similar measurements were made after intravenous injection of contrast material. The character of the calcification was also recorded (table 1).

Results

Seven patients showed calcification, two men and five women. They were 38–72 years old. Four had supratentorial lesions, three had infratentorial lesions, and two had supratentorial and infratentorial lesions. The attenuation values were

Received December 15, 1981; accepted after revision March 5, 1982.

[1] Department of Radiology, Section of Neuroradiology, New York Hospital–Cornell Medical Center, New York, NY 10021.

[2] Present address: Department of Radiology, School of Medicine, Health Sciences Center, State University of New York at Stony Brook, Stony Brook, NY 11794. Address reprint request to A. K. Anand.

AJNR 3:527–529, September/October 1982
0195-6108/82/0305-0527 $00.00

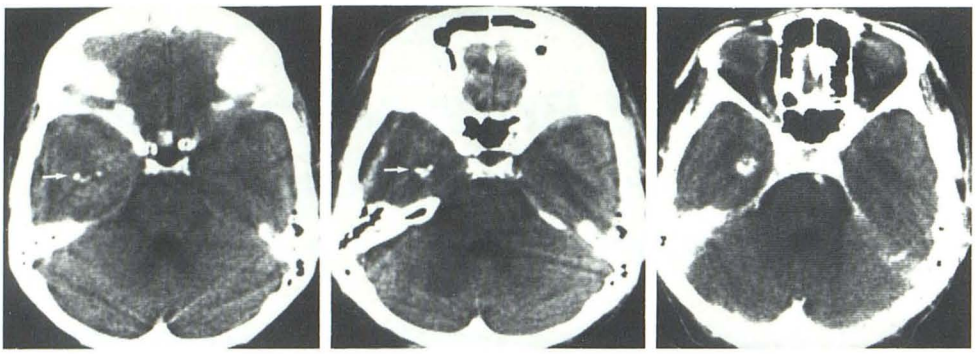

A B C

Fig. 1.—Case 1. Metastases from lung and breast. **A**, Punctate calcification (*arrow*) in right temporal lobe. **B**, Increase in calcification (*arrow*) 5 months later. **C**, Contrast enhancement in area adjacent to calcification.

TABLE 1: **Character of Metastatic Brain Calcifications**

Type of calcification: Case No.	Site of Primary Lesion	Site of Brain Lesion	Attenuation Values (H*)	
			Precontrast	Postcontrast
Punctate:				
1	Lung, breast	Right temporal	80–105	90–110
2	Lung	Multiple supra- and infratentorial	60–70	60–80
6	Breast	Multiple supratentorial	70–75	70–80
Curvilinear:				
3	Esophagus	Right cerebellum	50–57	70–80
4	Lung	Right cerebellum	60–70	70–75
Amorphous:				
5	Colon	Right frontal	60–65	76–80
7	Colon	Right frontal and parietal	65–71	70–80

* H = Hounsfield units.

A B

Fig. 2.—Case 2. Metastases from lung. **A**, Three areas in cerebellar hemispheres show punctate calcification (*arrows*). **B**, After injection of contrast material, enhancement surrounds areas of calcification.

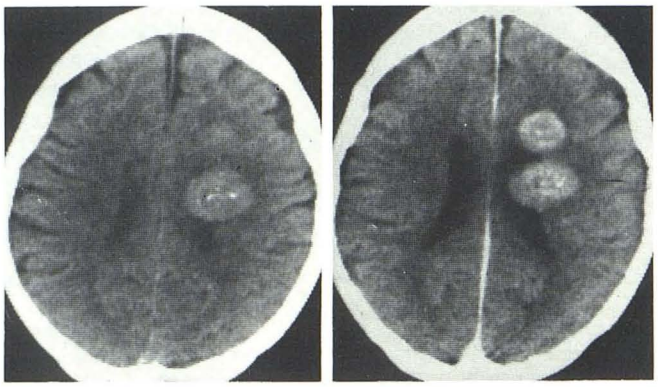

A B

Fig. 3.—Case 6. Metastases from breast. **A**, Central punctate calcification with amorphous, surrounding dense areas in left cerebral hemisphere. **B**, Slightly lower section. Enhancement in region of amorphous density.

50–105 Hounsfield units (H) on the precontrast scans. The regions of calcification showed a minor increase after injection of contrast material but the adjacent areas showed a greater degree of enhancement (figs. 2 and 3). The character of the calcification was punctate, curvilinear, or amorphous (table 1).

Discussion

The fact that seven cases of calcified metastases have been collected during a period of 8 months indicates that this condition is more common than suggested by the small number of cases reported in the radiologic literature [2, 3].

Modern CT is able to demonstrate minor calcification that would be missed on conventional radiographs. Sometimes small hemorrhages into metastases may be difficult to differentiate from calcification [4, 6]. However, attenuation values of hemorrhages are usually lower at 35–55 H [7]. Punctate or curvilinear densities are more likely to be calcification, but poorly defined amorphous densities may be caused by calcification or hemorrhage. Calcification may remain unchanged or gradually increase in scans repeated at intervals, while densities caused by hemorrhage usually disappear after 1–2 weeks. Calcification is usually centrally situated in a metastatic lesion [3].

The attenuation values were 50–105 H in our series. In the previous report of calcified breast metastases examined by CT [5], the attenuation values were 86 H. The presence of calcification was confirmed histologically in that case. Because the calcification usually occurs in a region of necrosis, significant enhancement in this necrotic region is not seen, but marked enhancement may be seen in the nonnecrotic part of the metastatic lesion.

REFERENCES

1. Kalan C, Burrows EH. Calcification in intracranial gliomata. *Br J Radiol* **1962**;35:589–602.
2. Griffiths T. Observations on cranial radiography in a series of intracranial tumors. *Br J Radiol* **1957**;350:57–69
3. Potts DG, Svare G. Calcification in intracranial metastases. *AJR* **1964**;92:1249–1251
4. Dohrmann GJ, Geeher RB, Robinson F, Allen WE, Orphanoudakis SC. Small hemorrhages vs. small calcifications in brain tumors: difficulty in differentiation by computed tomography. *Surg Neurol* **1978**;10:309–312
5. Handa J, Nakasu Y, Kamijyo Y. Calcified metastatic carcinoma of the brain. *Surg. Neurol* **1980**;14:67–70
6. Phelps ME, Hoffman EJ, Ter-Pogossian NM. Attenuation coefficients of various body tissues, fluids and lesions at photon energies of 18 to 136 kev. *Radiology* **1975**;117:573–583
7. Deck MDF, Messina AV, Sackett JF. Computed tomography in metastatic disease of the brain. *Radiology* **1976**;119:115–120