

Are your **MRI contrast agents** cost-effective?

Learn more about generic **Gadolinium-Based Contrast Agents**.



FRESENIUS
KABI

caring for life

AJNR

Computed Tomography of the Sacrum: 1. Normal Anatomy

Margaret Anne Whelan and Richard Palmer Gold

AJNR Am J Neuroradiol 1982, 3 (5) 547-554

<http://www.ajnr.org/content/3/5/547>

This information is current as
of April 18, 2024.

Computed Tomography of the Sacrum: 1. Normal Anatomy

Margaret Anne Whelan^{1, 2}
Richard Palmer Gold¹

The sacrum of a disarticulated pelvis was scanned with a Pfizer 0450 computed tomographic scanner using contiguous 5 mm sections to display the normal computed tomographic anatomy of the sacrum. These anatomic sections were then compared with normal sacra. In analyzing the computed tomographic anatomy, emphasis was placed on the central canal and sacral foramina, in that these landmarks are important in determining not only the presence but also the type of pathology involving the sacrum.

Computed tomography (CT) provides an accurate means of evaluating the curved surface of the sacrum. However, a thorough knowledge of the normal anatomy is required in order to appreciate pathologic changes in this area [1-4]. Part 1 of our paper addresses the normal CT anatomy. Part 2 discusses the effects of a number of pathologic processes on the sacrum with emphasis on changes affecting the bony matrix, central canal, and sacral foramina.

Materials and Methods

Transverse CT scans were obtained with a Pfizer 450 system using a 512 × 512 matrix, a scanning time of 10 sec, and slice thickness of 2-10 mm. To verify the accuracy of our anatomic interpretation in patients, the sacrum of a disarticulated pelvis was scanned from the ala to the level of the first coccygeal segment with careful visual monitoring of each scan section relative to sacral anatomy via the laser beam localizer. This sacrum was scanned in the "supine" position with no angulation of the gantry.

Scans from the skeleton were then compared with those in a number of patients whose sacra were studied for a variety of reasons and were thought to be anatomically normal. The clinical scans were often obtained at very close intervals and individual anatomy could be deduced as it developed in sequential fashion.

Because individual anatomy does vary and sacral angulation is inconstant, a series of sections from different patients was assembled that we believed corresponded well to our skeletal scan and that represented a "typical" enough sacrum such that any clinical variations could be readily understood.

When this series of scans was completed, a series of lines was superimposed over a radiograph of the disarticulated pelvis to indicate the anatomic position of the assembled clinical CT scans (figure key).

Corresponding to each clinical CT section, a line drawing was prepared on which were placed arrows and numbers indicating anatomic structures listed in a master key (table 1). Each structure maintains its same number throughout all the sections and is identified in table 1. All sections are referred to as a numbered "level" from 1 to 16 corresponding to the lines superimposed over the skeletal radiograph. Accompanying eight of these levels are the actual scans from the disarticulated skeleton (fig. 17) to illustrate that the clinically chosen levels are indeed accurate and anatomically correct. As each structure is referred to in the text, its number in table 1 is given in parentheses.

This article appears in the September/October 1982 issue of *AJNR* and the December 1982 issue of *AJR*.

Received December 28, 1981; accepted after revision April 20, 1982.

¹Department of Radiology, Columbia-Presbyterian Medical Center, New York, NY 10032.

²Present address: Department of Radiology, New York University Medical Center, 560 First Ave., New York, NY 10016. Address reprint requests to M. A. Whelan.

AJNR 3:547-554, September/October 1982
0195-6108/82/0305-0547 \$00.00
© American Roentgen Ray Society

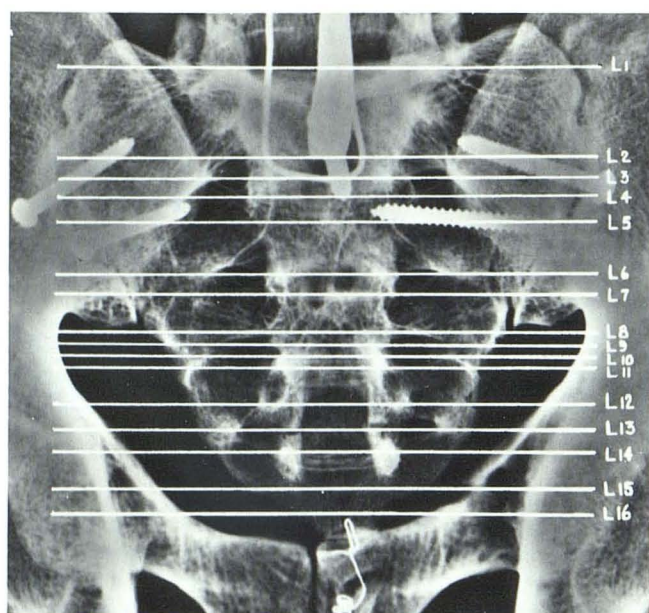


Figure key. Disarticulated sacrum from dry skeleton. Horizontal lines correspond to CT levels in figures 1–17.

Results

Normal Sacral Anatomy

The sacrum is a triangular bone formed by the fusion of the five sacral vertebrae (figure key). These five vertebral bodies begin to fuse with each other from below upward at about 17–18 years, fusion being complete by 23 years.

The sacrum lies at the upper posterior part of the pelvic cavity. There are five surfaces—pelvic, dorsal, lateral, superior (base), and inferior (apex). Within the bony sacrum are the dorsal midline canal, four ventral sacral foramina, and four dorsal sacral foramina. The midline dorsal canal (3) contains the five pairs of sacral nerve roots that descend from the conus medullaris. The first four nerve roots exit through their respective foramina while the fifth exits between the sacrum and coccyx. Since all the major nerve roots exit anteriorly, the ventral foramina (16, 20, 22, 25) are much larger than the dorsal foramina (15, 19, 21, 24), which carry only minor cutaneous nerve roots.

The large ventral foramina begin medially and dorsally near the central canal traveling laterally, inferiorly, and anteriorly to end at the ventral surface of the sacrum. The sacrum is curved longitudinally so that the ventral pelvic surface is concave and the dorsal surface convex. The ventral part of the sacrum displays the four pairs of sacral foramina that communicate through intervertebral foramina (17) with the sacral canal. The area between the right and left foramina consists of the flattened pelvic surfaces of the bodies of the sacral vertebrae. On gross specimen, the lines of fusion of the sacral bodies are visible as four raised transverse ridges. The most lateral bony part of the ventral

TABLE 1: Key to Anatomic Structures in Text and Figures

No.	Structure	No.	Structure
1	Sacral promontory	16	Ventral S1 foramen
2	Ala	17	Intervertebral foramen
3	Central sacral canal	18	S2 nerve root
4	Superior articular facet S1	19	Dorsal S2 foramen
5	Inferior articular facet L5	20	Ventral S2 foramen (region of)
6	L5–S1 disk space	21	Dorsal S3 foramen
7	Iliac bones	22	Ventral S3 foramen
8	Median sacral crest	23	Sacral hiatus
9	Intermediate sacral crest	24	Dorsal S4 foramen
10	Lateral sacral crest	25	Ventral S4 foramen
11	Lamina	26	Inferior lateral angle
12	Lateral part of sacrum	27	Sacral cornua
13	S1 nerve root	28	Oval facet
14	Sacral nerve bundle	29	Tubercles of unfused median sacral crest
15	Dorsal S1 foramen	30	S3 nerve root

surface is formed by the costal elements that unite with one another and then fuse with the vertebrae.

The convex dorsal surface consists of a midline raised interrupted median sacral crest (8) representing the fused spines of the sacral vertebrae. There are either three or four spinous tubercles along this crest. Beneath the lowest tubercle, there is a gap in the posterior wall of the sacral canal called the sacral hiatus (23). This defect is secondary to the failure of the laminae of the fifth sacral vertebrae to meet in the midline. The dorsal surface lateral to the median crest and medial to the dorsal foramina consists of the fused laminae (11) as well as the intermediate sacral crest (9), to which are attached sacroiliac ligaments. The crest is formed by a row of four small tubercles representing the fusion of the articular processes. The inferior articular processes of the fifth sacral vertebra then project downward at the sides of the sacral hiatus forming the sacral cornua (27). These cornua are in turn attached to the cornua of the coccyx by the intercornual ligaments.

Lateral to the intermediate sacral crest are the four dorsal sacral foramina. Like the ventral foramina, these smaller dorsal foramina communicate with the sacral canal through the intervertebral foramina. Lateral to the dorsal foramina is the lateral sacral crest (10), formed by the fusion of the transverse process, the tips of which appear as a row of tubercles, called the transverse tubercles. The lateral surface of the sacrum is formed by fusion of the transverse process with the costal elements. The broad upper part, the auricular surface, articulates with the ilium. Just posterior to this articular surface, a number of ligaments attach to the sacrum, while below the ilial articulation, the lateral surface narrows abruptly and then curves medially to form the inferior lateral angle (26).

The superior surface of the sacrum or base consists of the upper surface of the first sacral vertebrae. This vertebral body has a wide transverse diameter and a large convex

Fig. 1.—Level 1, L5–S1. L5–S1 disk space (6), facet joints (4, 5), and upper sacral ala (2).

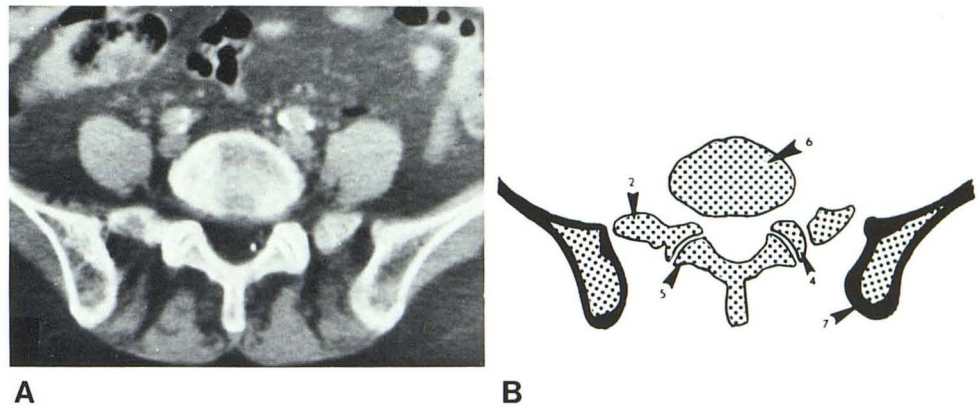


Fig. 2.—Level 2, upper S1. S1 nerve root (13) separated from sacral nerve bundle (14). Medial (8), intermediate (9), and lateral (10) sacral crests dorsally. Central canal has assumed triangular shape.

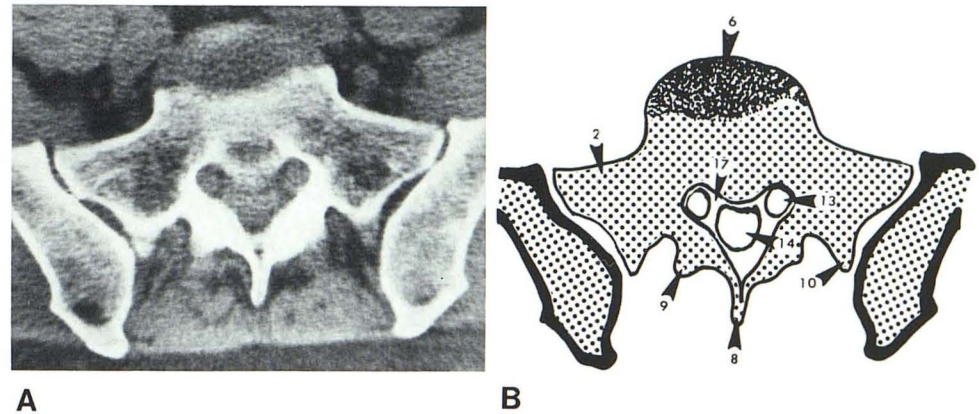
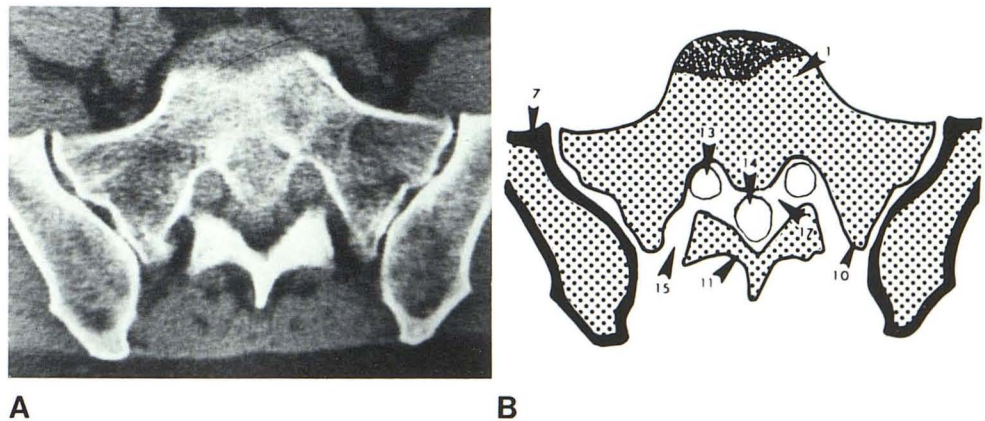


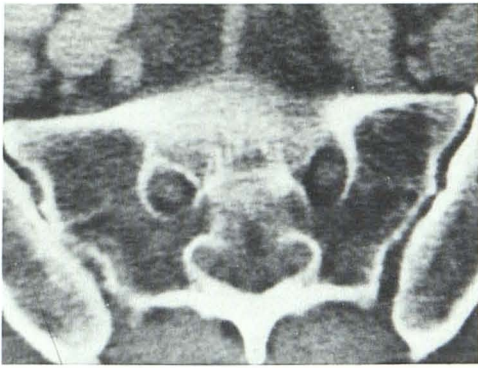
Fig. 3.—Level 3, middle S1. Dorsal S1 foramen (15) through which small dorsal S1 root exits. Major S1 nerve root (ventral S1) leaves intervertebral foramen (17). Convex sacral promontory anteriorly (1).



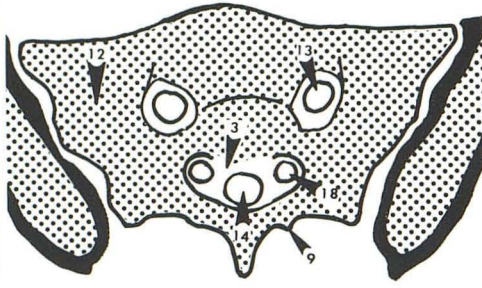
anterior border, the sacral promontory (1). The central dorsal canal is triangular at this level due to the short pedicles, while the large superior articular facets of S1 (4) point dorsomedially to articulate with the inferior articular facets

of L5 (5). The transverse process and costal element then join and fuse to the body of S1 to form the lateral part of the upper sacrum or ala (2).

The inferior surface of the sacrum or apex is formed by

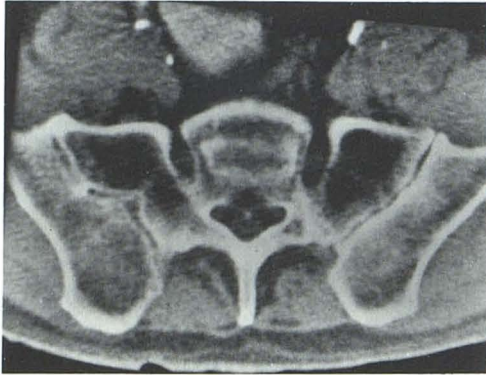


A

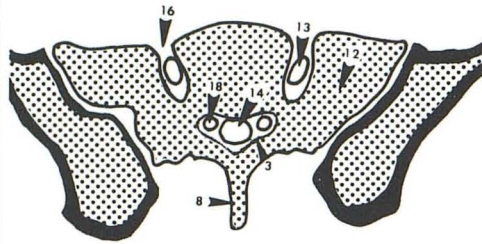


B

Fig. 4.—Level 4, lower S1. S1 root (ventral) (13) within sacrum. Posteriorly, S2 nerve roots have separated off (18). Sacroiliac joint is widest at this point, while central canal is becoming small and more elliptical.

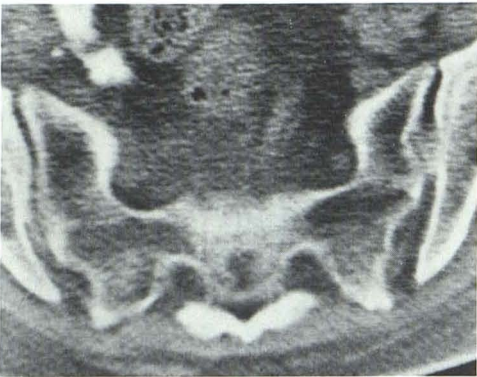


A

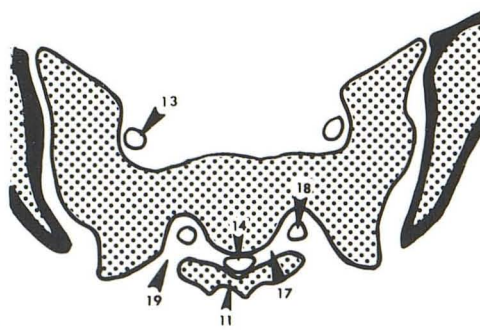


B

Fig. 5.—Level 5, S1-S2. S1 root (ventral) (13) leaves sacrum through ventral S1 foramen (16).

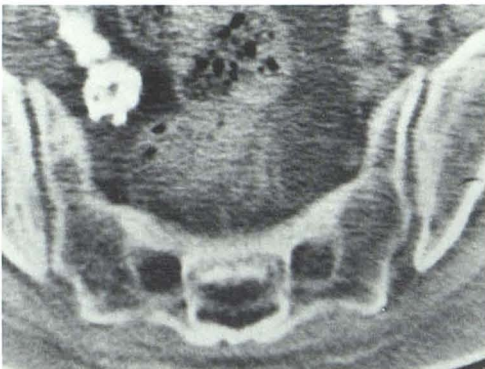


A

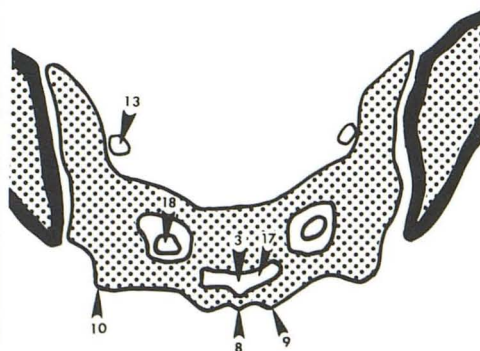


B

Fig. 6.—Level 6, upper S2. Dorsal S2 foramen (19) contains small dorsal S2 root. Major S2 root (ventral S2) (18) leaves intervertebral foramen (17). Large ventral S1 root (13) is in pelvis.



A



B

Fig. 7.—Level 7, lower S2. S2 nerve root (ventral) (18) within sacrum. Anterior border of sacrum has become concave while central sacral canal (3) is small and even more elliptical. Small S3 nerve root is not easily distinguished exiting intervertebral foramen (17).

Fig. 8.—Level 8, S2–S3. S2 root (ventral) (18) has exited its foramen (20) into pelvis.

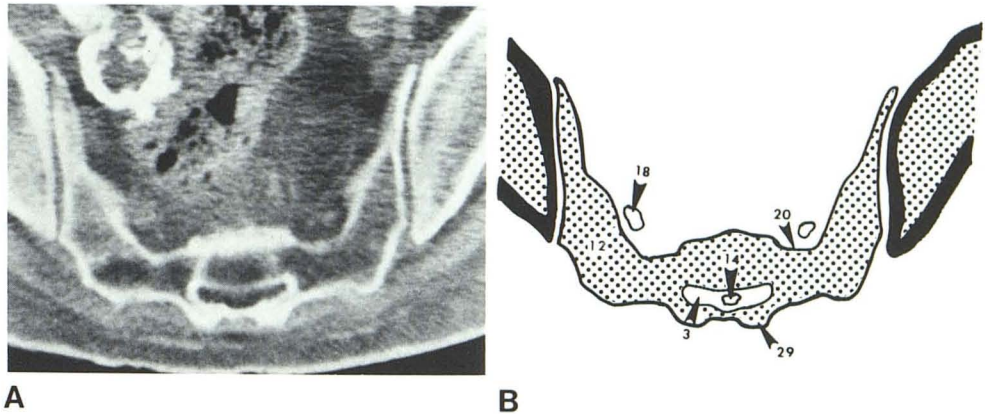


Fig. 9.—Level 9, upper S3. Dorsal S3 foramen (21) contains small dorsal S3 root and sacral hiatus (23). Sacroiliac joint is much smaller at this level.

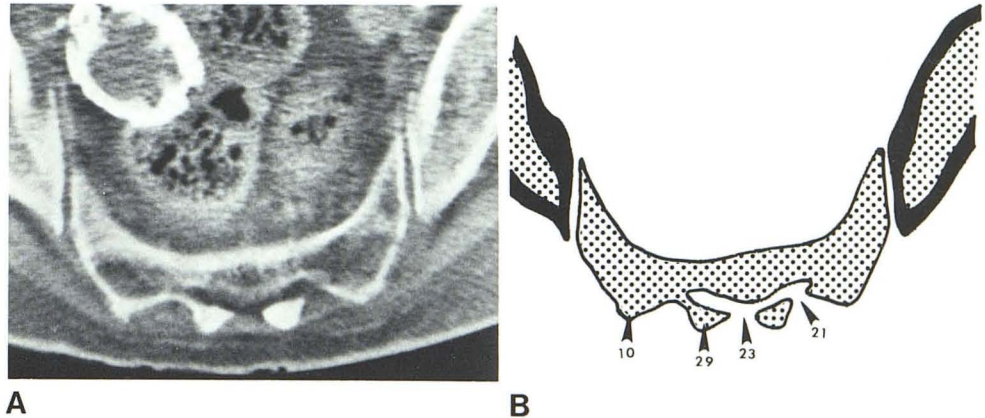
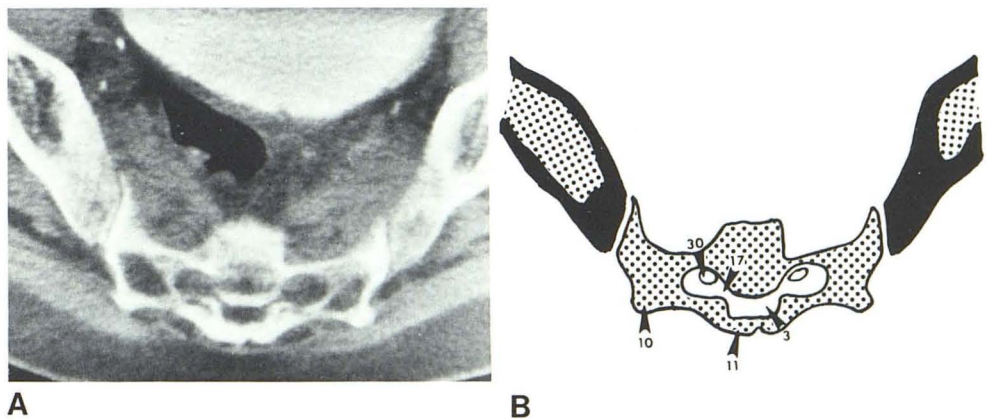


Fig. 10.—Level 10, middle S3. S3 nerve root (ventral component) (30) within sacrum after exiting intervertebral foramen (17).

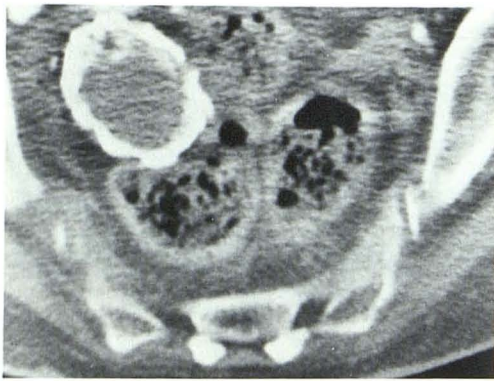

the inferior surface of the body of S5, which widens at its most inferior aspect to form a broad oval facet (28) for articulation with the coccyx.

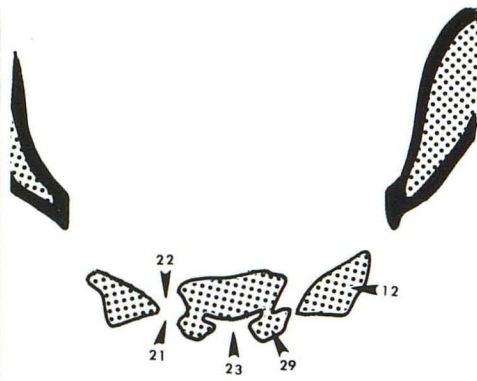
Normal CT Anatomy

The predominant CT features of the sacrum are the central sacral canal and the four paired ventral and dorsal sacral foramina. The upper sacrum is easily distinguished by the convex promontory (figs. 1–3). The central sacral canal (3)

is triangular at this level, and connects to both the ventral S1 foramina (16) and dorsal S1 foramina (15) through the intervertebral foramina (17) located in the lateral wall of the central canal (fig. 3). Both the ventral and dorsal foramina, therefore, begin posteriorly and medially near the sacral canal. The small dorsal foramina travel laterally to end shortly below its origin. The larger ventral foramina course laterally, inferiorly, and anteriorly ending at the ventral surface of the sacrum. The ventral S1 foramen (fig. 4) is

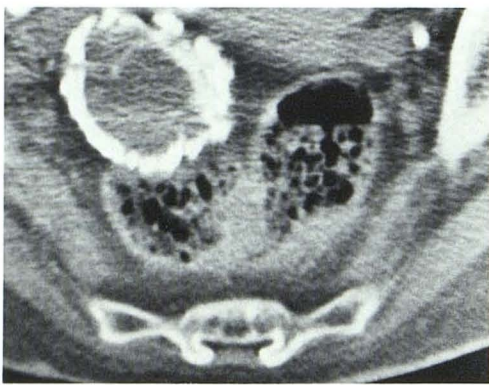


A

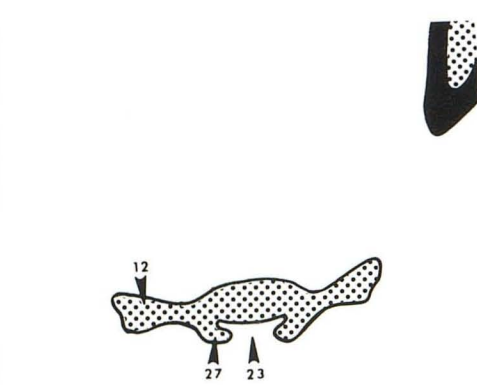


B

Fig. 11.—Level 11, lower S3. Ventral (22) and dorsal (21) foramina. Seeing both S3 foramina on one section depends on shape and size of individual sacrum. Sacroiliac joint ends at this level.

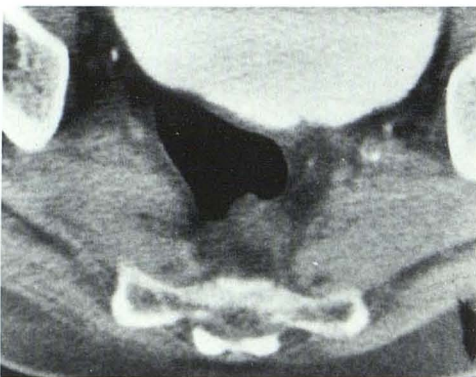

A

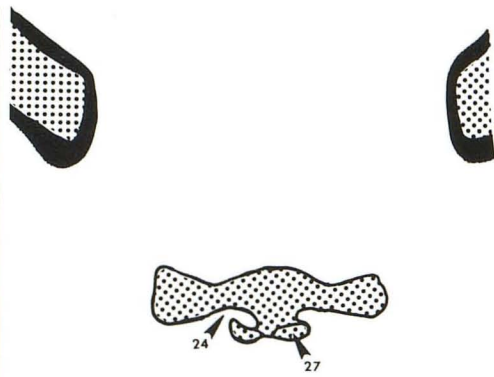


B

Fig. 12.—Level 12, S3-S4. Sacral hiatus (23) and upper sacral cornua (27).



A



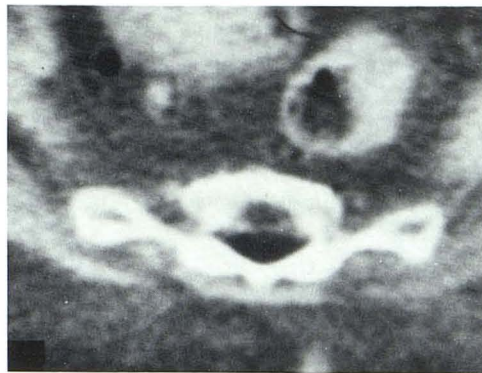
B

Fig. 13.—Level 13, upper S4. Dorsal S4 foramen (24) and sacral cornua (27). Greater sciatic notch is below sacroiliac joint.

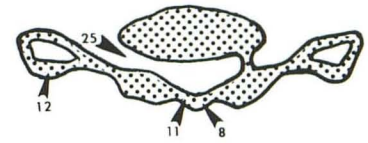
generally 10–15 mm long. Because of the ventral sacral concavity, however, the inferior surface of the foramen can be identified on a scan after the nerve has exited (fig. 5). As the S1 foramen ends, the S2 root (figs. 4 and 5) can be identified close to the central canal, which at these levels has become more elliptical. The dorsal S2 foramina can be identified in figure 6, while the large ventral S2 foramina (fig. 7) travel anteriorly, laterally, and inferiorly to end about 10 mm below their origin (fig. 8). There is marked diminution in

the anteroposterior (AP) diameter of the sacrum as well as in the size of the sacroiliac joint at the S3 level (figs. 8–11). Since the S3 and S4 nerve roots are smaller than the S1 and S2 roots and the sacral diameter is decreased at this level, both the ventral and dorsal foramina can frequently be seen on the same sections (figs. 8 and 13). Furthermore, since the ventral foramina are much smaller at the S3 and S4 levels, they can be seen ending at the pelvic brim shortly after their origin (figs. 9, 13, and 14). Although the level of

Fig. 14.—Level 14, lower S4. Ventral S4 foramen (25).

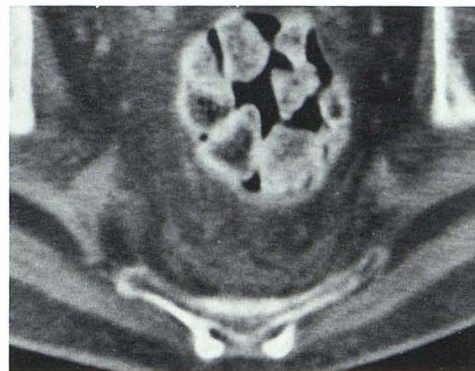

A

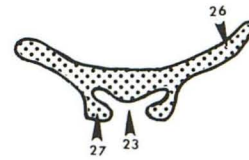


B

Fig. 15.—Level 15, lower sacrum, just below S4. Sacral hiatus (23), inferior lateral angle (26), and sacral cornua (27).

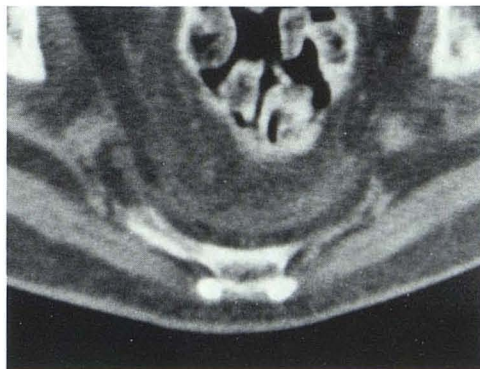

A

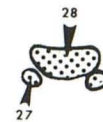

B

Fig. 16.—Level 16, sacral tip. Oval facet (28) at end of sacrum and inferior tip of sacral cornua (27).



A



B

the sacral hiatus of the sacrum (23) (fig. 12) varies with the individual, it can generally be seen at S4. The area just beneath S4 can be identified by the inferior lateral angle (26) (fig. 15), the point at which the lateral sacral surface narrows abruptly and curves medially. Finally, the tip of the sacrum can be demonstrated on CT by identifying the broad flat oval facet (28) (fig. 16) that articulates with the coccyx. Just behind the oval facet are the caudal ends of the sacral

cornua (27), which form a ligamentous attachment to the coccygeal cornua.

It is apparent that serial CT scans are ideal for detailed imaging of the curving surfaces of the sacrum. Of course, thorough knowledge of the normal CT anatomy is essential for accurate interpretation of sacral pathology. Special emphasis is given to the central sacral canal and the sacral foramina, in that careful search for changes in these nor-

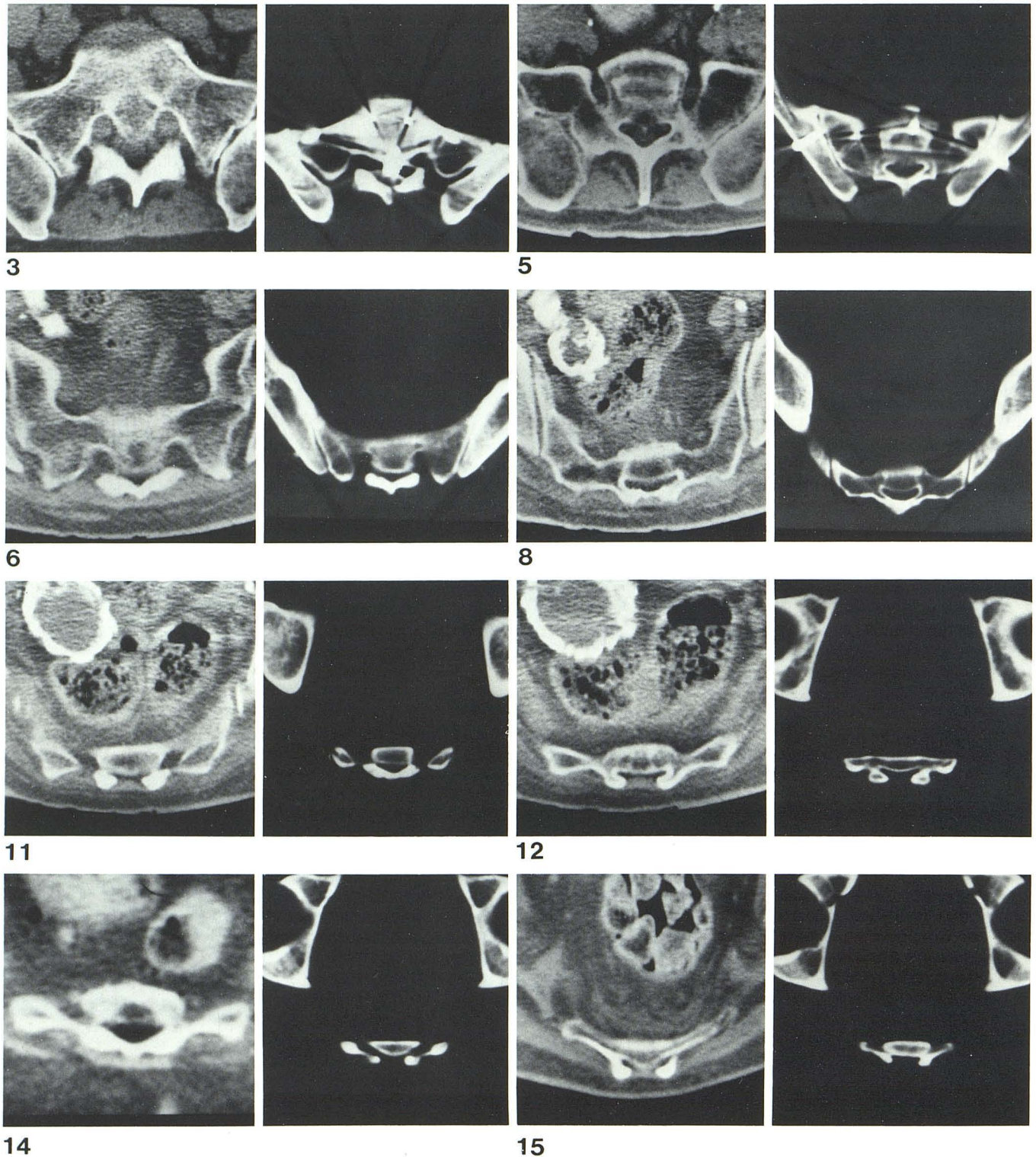


Fig. 17.—Comparison of clinical (left) and skeletal (right) scans. Clinical scans were illustrated previously (figs. 3, 5, 6, 8, 11, 12, 14, and 15, respectively).

mally symmetric structures can lead to more sensitive detection of abnormality.

REFERENCES

1. Caffey J. *Pediatric x-ray diagnosis*, 5th ed. Chicago: Year Book Medical, 1967
2. Romanes GJ, ed. *Cunningham's textbook of anatomy*, 12th ed. Oxford, England: Oxford Medical, 1981:98-100
3. Anderson JE, ed. *Grant's atlas of anatomy*, 7th ed. Baltimore: Williams & Wilkins, 1978
4. Williams PL, Warwick R. *Gray's anatomy*, 36th British ed. Philadelphia: Saunders, 1980:279-282