

BOOK REVIEW

High-Resolution Sonography of the Peripheral Nervous System (Medical Radiology/Diagnostic Imaging), 2nd ed

S. Peer and G. Bodner, eds. Springer; 2008, 208 pages, 402 illustrations, \$139.00.

Diagnostic sonography of the peripheral nervous system is a rapidly evolving and constantly expanding imaging field, which encompasses subspecialty areas of musculoskeletal imaging and neuroradiology. In the 5 years since the first edition of *High-Resolution Sonography of the Peripheral Nervous System*, advances in clinical sonography involving scanner and transducer technology, and image processing have resulted in a more profound structural delineation of the peripheral nervous system. This has made possible the diagnosis and guided treatment of disorders that were previously deemed inaccessible. The spectrum of peripheral nerve diseases that can be examined sonographically has broadened and has resulted in a better understanding of tumoral and traumatic nerve conditions. This second revised edition presents these advances well.

The authors, contributors, and editors have compiled their extensive personal experience, original research; comprehensive literature review; and collaborations with experts in the fields of anatomy, neurology, and surgery into a textbook that is well written, nicely illustrated, and effortlessly understandable. Even though some of the data presented have been previously published by the authors, this edition is better and more comprehensively presented. Many of the high-resolution images are a considerable improvement from the first edition. Particularly useful are pictorial sonographic-anatomic correlations based on cadaver cryosections and their corresponding comparative sonograms. Information is presented in 8 concise chapters, which are further numerically subclassified and allow quick reference to areas of interest.

The first chapter deals with general considerations and technical concepts in high-resolution peripheral nerve sonography and includes an overview of the historical development of these techniques beginning with the work of Bruno Fornage. This is followed by a brief discussion comparing the advantages and limitations of sonography and MR imaging in peripheral nerve evaluation and a cursory review of recommended sonographic hardware and software requirements, including compound, tissue harmonic, extended FOV, and high-resolution imaging. It is understandable that a textbook of this type must include some discussion on the topic of sonographic hardware and software, but readers might find this section perfunctory. More useful information is included in the part dealing with general technique issues of sonographic nerve evaluation, where the authors use their considerable experience to provide helpful tips.

The second chapter includes a review of regional nerve anatomy as assessed by high-resolution sonography, presented by using anatomic landmarks to pair representative regional sonographic images in typical sonographic planes,

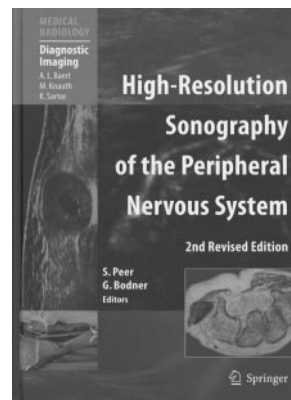
with correlative pictures of cadaveric cryosection specimens. Cutaneous and terminal nerve branches are not depicted, due to their habitual sonographic inconspicuousness in nondiseased states. Regional nerves discussed include the cranial nerves; the cervical and brachial plexuses; and nerves of the upper extremity (including the arm, forearm, wrist, and hand), lower extremity (including the groin, thigh, lower leg, and foot), and trunk. Particularly useful are photographs that demonstrate transducer positioning necessary to generate the accompanying sonographic images. A minor critique is the use of black and white photographs, particularly of the cadaveric specimens, which would have been more easily visible in color and would have provided better contrast to the corresponding gray-scale sonographic images. Also, the authors would have been more effective if they had included representative MR images of the individual regional nerves in the same imaging planes, because most of their readers are probably more familiar with that imaging technique for nerve evaluation.

The third chapter deals with the clinical presentation, etiology, diagnosis, and therapy of the most common peripheral nerve—entrapment syndromes, involving the ulnar, radial, median, peroneal, and tibial nerves. Also reviewed are standard electrodiagnostic examinations, including nerve conduction studies, recording of late responses, and needle electromyography. Although these techniques reside outside the field of radiology, those interested in the diagnosis and treatment of peripheral nervous system disorders should have a basic understanding of them, to have more efficient and productive interactions with referring clinicians.

Chapters 4, 5, and 6 will probably be the most repeatedly referenced by future readers because they present the sonographic and clinical findings of various nerve compression syndromes, traumatic nerve lesions, tumors, and tumorlike conditions. Accessory, radial, median, ulnar, iliohypogastric, saphenous, peroneal, and tibial nerve pathologies are discussed, as well as thoracic outlet syndrome and entrapment of the lateral femoral cutaneous nerve (meralgia paresthetica). Useful colored illustrations clearly depict the normal pathway of these nerves and the common sites of entrapment.

Discussion of traumatic nerve lesions in chapter 5 covers the upper and lower extremities; iatrogenic nerve lesions associated with head, neck, and orthopedic surgery; and regional anesthesia. Particularly informative is the discussion of the imaging appearance of the postoperative nerve, including normal findings, scarring, and neuroma formation.

The sixth chapter deals with some of the most frequently encountered nerve tumors and tumorlike conditions, including benign and malignant peripheral nerve tumors, non-neural tumors within the nerve sheath, and neuromas. Quality color Doppler images are provided throughout the book,



which are particularly useful in this section, but there is a notable absence of power Doppler images.

Given that sonography in certain instances is better than CT or MR imaging at detecting small soft-tissue lesions (<1 cm) and given its real-time capability, many consider it to be the best imaging technique for performing accurate interventional peripheral nerve procedures. This is addressed in chapter 7, which includes a discussion on sonographically guided regional anesthesia of upper and lower extremities; interscalene, supraclavicular, infraclavicular, and axillary perivascular brachial plexus blocks; psoas compartment block; and sciatic and pudendal nerve blocks. Therapeutic injections are examined, including the use of steroids, phenols, glycerol, and alcohol. Lacking are more images demonstrating correct needle placement as well as pre- and postinjection images, showing the injectant surrounding the nerves.

The last chapter presents a reconstructive surgeon's perspective on nerve anatomy, nerve injury and degeneration, surgical nerve repair and reconstructive techniques, and prognosis and future directions in peripheral nerve surgery. Pre-, intra-, and postoperative color photographs of different con-

ditions are included, with a discussion of optimal timing of nerve repair and iatrogenic nerve injuries.

The success of the first edition has shown that besides radiologists, this field is of interest to neurologists and orthopedic, plastic, and trauma surgeons. With almost endless future applications, particularly as a therapeutic technique, radiologists should strive to learn and master these sonographic techniques so as not to lose them in the future to the other specialties. Although at times cursory, this latest addition to the *Medical Radiology/Diagnostic Imaging* series is indispensable to those interested in using sonography to diagnose and treat peripheral nerve diseases. It provides a clinically oriented, concise, and accessible review of diagnostic sonography as it pertains to this field, including the assessment of nerve compression syndromes, traumatic lesions, tumors, postoperative complications, and sonographically guided treatment of disorders that were previously deemed inaccessible. Therefore, it should prove useful in both academic and private practice settings.

DOI 10.3174/ajnr.A1348