

## BOOK REVIEW

### CT and MRI of the Whole Body, 5th ed, 2-Vol. set

J.R. Haaga, V.S. Dogra, M. Forsting, R.C. Gilkeson, H.K. Ha, and M. Sundaram, eds. Mosby Elsevier; 2008, 2904 pages, \$359.00.

Another multiauthored 2-volume 2904-page book is available to those who want a text that encompasses the major facets of diagnostic CT and MR imaging. *CT and MRI of the Whole Body*, edited by Drs Haaga, Dogra, Forsting, Gilkeson, Ha, and Sundaram distinguishes itself by being inclusive (hence the title *Whole Body*). However, in this day and age, this reviewer continually wonders about the value of these huge/heavy books that attempt to cover all areas of radiology. More on this later in the review.

A poignant dedication at the beginning of this book to John Haaga's daughter also contains an inscription and picture, which are memorable.

There are, as one would expect in a multiauthored text, more than 100 authors, most of whom are well known in their subspecialty areas. The first 859 pages deal with neuroradiology and compose the largest part of these books. The other part includes "Imaging of the Chest" (374 pages), "Gastrointestinal Imaging" (590 pages), "Genitourinary Imaging" (322 pages), "Imaging of the Musculoskeletal System" (274 pages), and "Image Guided Intervention and Basic Science" (322 pages). This, by the way, is the first book I can recall in which the physics of CT and MR imaging are placed at the end of a book. This setup is good—start out with neuroradiology (brain, head and neck, spine) in the beginning and put the physics at the end so as not to discourage those potential buyers who are browsing through the books, deciding which to buy.

Concerning the neuroradiology, this reviewer began with the first chapter on normal anatomy. The labeled brain and spine images looked, at first glance, to be the same as those contained in any other textbook, with just the most rudimentary and obvious structures labeled; however, I was quickly startled by mislabeling. In one coronal MR image, the authors have labeled a frontal gyrus as the "middle sagittal sinus"; in an axial noncontrast spine CT scan, the authors point to an attenuation, which probably is a disk/osteophyte complex, and call it the "anterior subarachnoid space." On the next page, the authors label the back of the spinal column (or cortex of the lamina on CT) as "epidural fat" (certainly a better example of epidural fat could have been shown). Even if one could ignore the mislabelings, one soon concludes that this review of the gross anatomic structures is at most elementary and would serve as background for medical students and first-year radiology residents only.

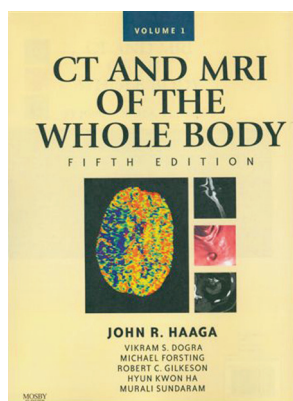
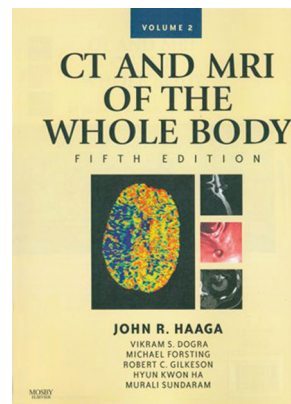
The rest of the neuroradiology portions of the book takes us to "Brain and Meninges" (chapters on intracranial neoplasms, cerebral infections and inflammation, stroke, aneurysms and cerebrovascular malformations, central nervous system trauma, neurodegenerative disorders, MR spectroscopy, meningeal processes, and leukoencephalopathies and demyelinating disease), "Imaging of the Head and Neck"

(chapters on the orbit, temporal bone, sinuses/nasopharynx/oropharynx, cervical adenopathy and neck masses, larynx, and pediatric head and neck), and "Imaging of the Spine" (chapters on spinal cord, degenerative disease, extramedullary spinal tumors, infections of the spine, and image-guided spinal interventions).

All of these chapters are treated in a format roughly equivalent to material published in other textbooks. There is an attempt to combine CT and MR imaging when dealing with brain abnormalities—this is a reasonable tact to take but, of course, the reality in most situations is that MR imaging so far supersedes CT in lesion detection and characterization that one wonders why that combination even needs to be shown in brain imaging—except perhaps with CT angiography or CT-derived metrics in stroke or to identify or confirm areas of calcification.

Those issues notwithstanding, the chapters cover the material adequately. The chapter on intracranial neoplasms is instructive, and the images selected are of good quality. A similar observation is made concerning other chapters in this section. Nonetheless, one questions some of the images selected and their descriptions. A few examples will suffice: In a case of a pilocytic astrocytoma of the optic chiasm and hypothalamus, an arrow points to a described optic nerve (left) widening, but the image is of very low quality, rendering that finding poorly defined. In that same case what is a T2-weighted (T2WI) image is called a contrast-enhanced study. In a T2WI image of a Rathke cleft cyst, the window settings are such that the cyst cannot be distinguished from the surrounding CSF. A totally incomprehensible legend describes a "ring enhancing lesion in the left parietooccipital region with abscess formation," but the figure is a noncontrast T1-weighted image of the posterior fossa. A T2WI image is termed a diffusion-weighted image, and 2 parts of the figure are never described. An unlabeled MR spectroscopic image in a case of acute necrotizing encephalitis with no useable scale on the x-axis makes such spectroscopic data useless.

The stroke chapters review the basic findings on MR imaging and CT, but the chapter is bereft of substantial new and important stroke evaluations. Specifically, there are only 2 meager paragraphs on CT perfusion evaluation of ischemic brain; one cannot learn how to implement either CT or MR perfusion by what is covered here. Certainly a text published in 2009 should have more depth to it in this important area of neuroradiology. The chapters on vascular malformations and



head trauma are standard fare. However, in “Neurodegenerative Disorders and Brain MR Spectroscopy,” the reader encounters more state-of-the-art information, and this is particularly true of Dr Pillai’s chapter on MR spectroscopy. Here the basics of spectroscopy and single-voxel, multivoxel, and metabolic maps are demonstrated.

Concerning the head and neck chapters, standard displays and explanations are given for the normal orbit, temporal bones, and sinuses and the common pathologic conditions affecting these areas. The remaining chapters on cervical adenopathy/neck masses and pediatric head and neck imaging supply brief reviews of the main pathologic processes affecting these areas. The spine chapters provide standard images and explanations. As in most of the book, authors describe the findings, illustrate them, and briefly describe the disease itself; however, missing in nearly every area is a discussion of the possible differential diagnosis—this would have been a valu-

able addition to every chapter. The inclusion of image-guided interventions is a plus for the book and is useful for a person who seeks an overview of what can be done; it in no way by itself prepares one to do such interventions.

This 2-volume set would be a good reasonable addition to a departmental library, but with the explosion of material available nowadays and the movement to more and more subspecialization, this reviewer wonders about the value and future of these mega books. They attempt to cover nearly an entire discipline but really can do no area a complete in-depth service. More specialized and focused textbooks will probably dominate in the future.

All that said, this book, especially the neuroradiology section, would make a reasonable recommended reading for a beginning resident.

DOI 10.3174/ajnr.A1609