

Are your **MRI contrast agents** cost-effective?

Learn more about generic **Gadolinium-Based Contrast Agents**.



**FRESENIUS  
KABI**

caring for life

**AJNR**

**Gray-Scale and Power Doppler Sonography  
and CT Findings of Myopericytoma of the  
Posterior Cervical Space**

S.K. Lee and S.Y. Kwon

*AJNR Am J Neuroradiol* 2009, 30 (8) 1604-1606

doi: <https://doi.org/10.3174/ajnr.A1535>

<http://www.ajnr.org/content/30/8/1604>

This information is current as  
of April 18, 2024.

# Gray-Scale and Power Doppler Sonography and CT Findings of Myopericytoma of the Posterior Cervical Space

## CASE REPORT

S.K. Lee  
S.Y. Kwon

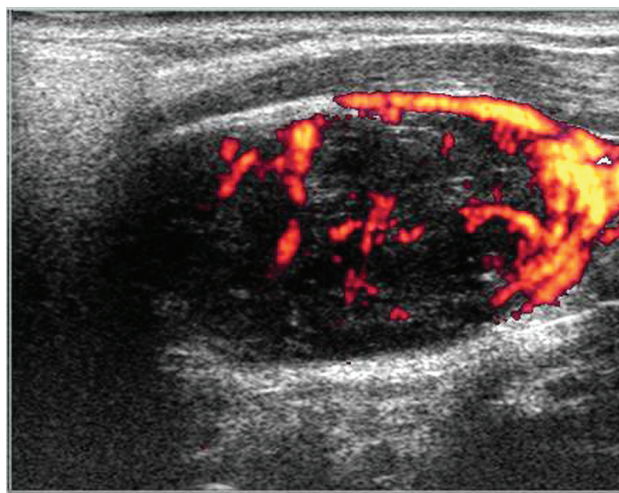
**SUMMARY:** We report the imaging, pathologic findings, and differential diagnosis of a myopericytoma presenting in the posterior cervical space of a 51-year-old man. The mass was hypervascular on power Doppler sonography and demonstrated homogeneous intense enhancement on contrast-enhanced CT. Differential diagnosis included hypervascular metastasis, Castleman disease of the hyaline vascular type, and paraganglioma of the vagus nerve. Myopericytoma should be considered in the differential diagnosis of a highly vascular soft-tissue mass of the posterior cervical space.

**M**yopericytoma is a rare recently delineated soft-tissue neoplasm characterized by a perivascular proliferation of round-to-spindle pericytic cells of myoid (ie, resembling smooth muscle) differentiation.<sup>1</sup> It has a propensity to occur in the dermis and subcutaneous layer of the extremities in middle-aged adults.<sup>2</sup> Cases of myopericytoma of the neck have been reported in the literature<sup>2-4</sup>; however, to our knowledge, the imaging findings of this entity have not been described. We report herein a case of myopericytoma of the posterior cervical space along with its imaging and pathologic findings.

### Case Report

A 51-year-old man presented with a mass at the right upper neck growing slowly for 2 months. On physical examination, a firm 3 × 3 cm ovoid mass was found at the right upper posterolateral neck. No cranial nerve deficit or cervical lymphadenopathy was present. Sonographic examination demonstrated a well-demarcated heterogeneous markedly hypoechoic solid mass of 21.3 × 38.7 × 37.5 mm within the right posterior cervical space. Prominent color signals were noted within the mass on power Doppler (PD) sonography (Fig 1). Multi-detector row CT showed a sharply defined ovoid homogeneously enhancing (as intensely enhancing as vascular structures) mass located posterolateral to the internal and common carotid arteries and internal jugular vein, which were displaced anteromedially by the mass (Fig 2). On the basis of imaging findings, presumptive preoperative diagnoses included hypervascular metastasis, Castleman disease of hyaline vascular type, and paraganglioma or schwannoma of the vagus nerve. Sonography-guided fine-needle aspiration biopsy showed scattered cellular nests, which comprised oval-to-spindle tumor cells (Fig 3).

Complete excision of the mass was performed. The mass was well demarcated and not adherent to adjacent tissue. Microscopically, the mass was well circumscribed but not encapsulated. It was composed of oval-to-spindle cells with a concentric growth pattern around small blood vessels (Fig 4). Some tumor cells showed mild cytologic atypia; however, the mitotic count was <1–2 per 10 high-power field. Necrosis or hemorrhage was not identified. Immunohistochemically, most of tumor cells revealed diffuse positivity for smooth muscle



**Fig 1.** A longitudinal PD sonographic image reveals a well-circumscribed heterogeneous markedly hypoechoic solid mass in the right posterior cervical space. The mass is hypoechoic compared with the sternocleidomastoid muscle, with prominent vascularity.

actin (SMA) and CD34 (Fig 5), but they were negative for S-100 protein, CD31, CD68, and CD21. These pathologic findings were consistent with myopericytoma. The postoperative course was uneventful, and there has been no evidence of neurologic deficit or tumor recurrence in 20 months after surgery.

### Discussion

Hemangiopericytoma was first described by Stout and Murray in 1942<sup>5</sup> as a distinctive soft-tissue neoplasm, presumably of pericytic origin, exhibiting a characteristic well-developed “staghorn” branching vascular pattern. For a period of years, this vascular pattern was considered nonspecific and was shared by numerous unrelated benign and malignant lesions. The single largest subset of lesions, formerly known as hemangiopericytoma, would currently be classified as solitary fibrous tumors. In addition, most tumors formerly diagnosed as so-called hemangiopericytoma have nothing to do with pericytes. As a consequence, hemangiopericytoma has become a diagnosis of exclusion.<sup>1,6</sup>

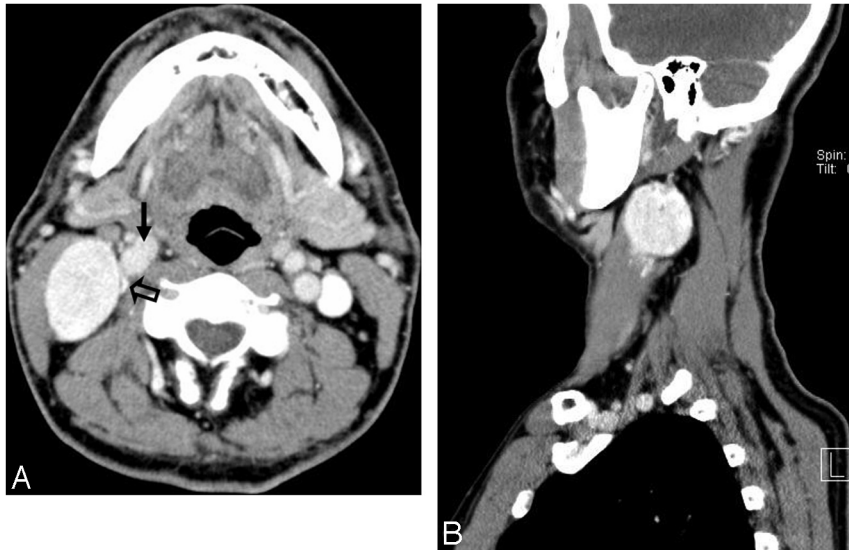
In contrast, myopericytoma is a truly pericytic neoplasm, which is being increasingly defined and represents a continuum between myofibromatosis, glomus tumor, and angioleiomyoma.<sup>1,2,6</sup> Pericytes were first described by Zimmermann<sup>7</sup> as specialized cells normally present around capillaries.

Received December 2, 2008; accepted after revision January 2, 2009.

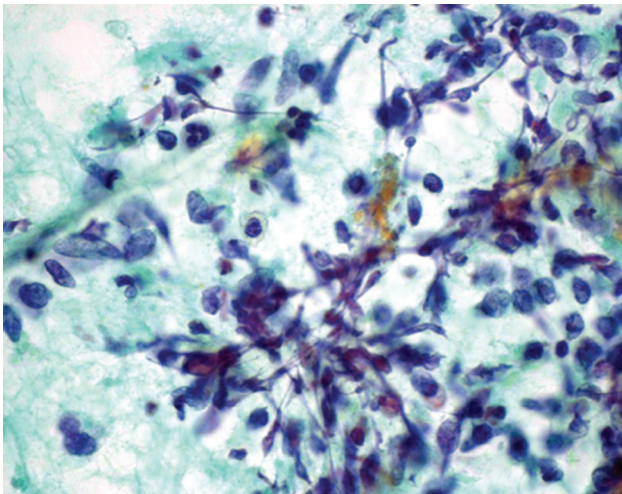
From the Departments of Radiology (S.K.L.) and Pathology (S.Y.K.), Dongsan Medical Center, Keimyung University College of Medicine, Jung-gu, Daegu, South Korea.

Please address correspondence to Sang Kwon Lee, MD, Department of Radiology, Dongsan Medical Center, Keimyung University College of Medicine, 194 Dongsan-dong, Jung-gu, Daegu 700-712, South Korea; e-mail: sklee@dsmc.or.kr

DOI 10.3174/ajnr.A1535



**Fig 2.** Axial contrast-enhanced CT (A) and sagittal contrast-enhanced reformatted (B) images reveal a well-defined ovoid mass with homogeneous intense enhancement. The degree of enhancement is as intense as that of vascular structures. The mass is located posterolateral to the internal and common carotid arteries (arrow) and the compressed internal jugular vein (open arrow). These structures are displaced anteromedially by the mass.



**Fig 3.** Photomicrograph of the cytologic examination of the specimen obtained by fine-needle aspiration biopsy of the mass demonstrates cellular nests, which comprise oval-to-spindle cells (papanicolaou stain, original magnification  $\times 1000$ ).

They were thought to be modified smooth muscle cells. Histologically, myopericytomas are recognized by the presence of a distinctive concentric perivascular proliferation of round-to-spindle pericytes with eosinophilic cytoplasm and a myoid appearance, which are arranged circumferentially around vascular lumina in an “onion skin” (multilayered) pattern.<sup>1,8</sup> These perivascular cells are characteristically reactive for muscle-specific actin and SMA, consistent with a pericytic/myoid differentiation.<sup>1,9</sup>

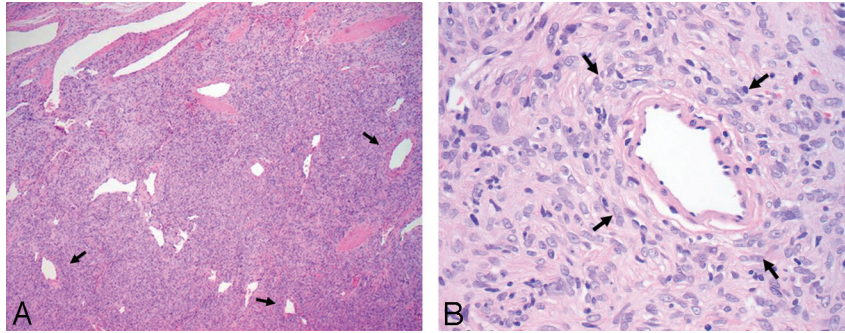
Most myopericytomas are benign lesions, though a few malignant cases have also been described.<sup>3</sup> Recurrence has been reported in 10%–20% of patients with myopericytoma. Recurrence has been hypothesized because of the extension of cords of tumor beyond the main lesion or as a reflection of multifocal disease.<sup>10</sup> Myopericytoma may be associated with

trauma.<sup>11,12</sup> Several series of myopericytoma cases of the neck have been reported, but most of them were focused on clinical and pathologic features.<sup>2–4</sup> As such, to our knowledge, imaging findings of myopericytoma of the neck have not been described. The previously documented imaging features of myopericytoma occurring other than in the neck included MR imaging of 3 cases of primary intracranial myopericytoma and sonography and MR imaging of a case occurring in the lower extremity.<sup>13,14</sup>

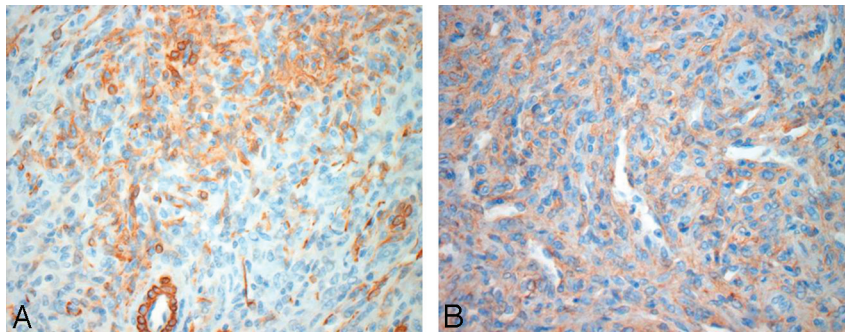
Rousseau et al<sup>13</sup> reported 3 cases of intracranial myopericytoma. Of them, 2 showed intense enhancement on contrast-enhanced T1-weighted images, and one showed heterogeneous contrast enhancement with peripheral foci of calcification. Harish et al<sup>14</sup> reported a case of myopericytoma of Kager fat pad. According to these authors, the mass was well circumscribed and hypoechoic on gray-scale sonography and demonstrated marked internal vascularity on color Doppler sonography. It was isointense to muscle on T1-weighted images, with a small hyperintense focus, which indicated hemorrhage. Apart from the hemorrhagic focus, most the mass demonstrated intense enhancement after intravenous administration of gadolinium.

The differential diagnosis of a highly vascular mass in the posterior cervical space includes hypervascular metastasis, particularly from papillary thyroid carcinoma, and Castleman disease of the hyaline vascular type. Paraganglioma of the vagus nerve in the carotid space may grow posteriorly and may appear as a highly vascular mass in the posterior cervical space. Schwannoma also should be considered in the differential diagnosis, though it may not enhance as intensely as the above-mentioned lesions.

In summary, our case showed a well-demarcated heterogeneous markedly hypoechoic solid mass on gray-scale sonography, prominent vascularity within the mass on PD sonography, and a homogeneous hypoattenuating mass with homogeneous intense (as intense as vascular structures) enhancement on CT. We suggest myopericytoma as an alterna-



**Fig 4.** A, Photomicrograph of the histologic examination of the mass at low-power field reveals numerous gaping and branching thin-walled vessels surrounded by oval-to-spindle myoid cells (arrows) (hematoxylin-eosin [HE], original magnification,  $\times 40$ ). B, At high-power field, most plump tumor cells, having oval-to-spindle nuclei, arrange around vessels (arrows). Some tumor cells show mild cytologic atypia (HE, original magnification  $\times 400$ ).



**Fig 5.** Photomicrographs show that most tumor cells demonstrate diffuse positivity for smooth muscle actin (SMA) (A, immunohistochemical stain for SMA, original magnification  $\times 400$ ) and CD34 (B, immunohistochemical stain for CD34, original magnification  $\times 400$ ) consistent with a pericytic/myoid differentiation, which are needed for the diagnosis of myopericytoma.

tive diagnostic possibility for a highly vascular soft-tissue mass of the posterior cervical space.

## References

1. Granter SR, Badizadegan K, Fletcher CD. Myofibromatosis in adults, glomangiopericytoma, and myopericytoma: a spectrum of tumours showing perivascular myoid differentiation. *Am J Surg Pathol* 1998;22:513–25
2. Mentzel T, Dei Tos AP, Sapi Z, et al. Myopericytoma of skin and soft tissues: clinicopathologic and immunohistochemical study of 54 cases. *Am J Surg Pathol* 2006;30:104–13
3. McMenamin ME, Fletcher CD. Malignant myopericytoma: expanding the spectrum of tumors with myopericytic differentiation. *Histopathology* 2002; 41:450–60
4. Dray MS, McCarthy SW, Palmer AA, et al. Myopericytoma: a unifying term for a spectrum of tumours that show overlapping features with myofibroma—a review of 14 cases. *J Clin Pathol* 2006;59:67–73
5. Stout AP, Murray MR. Hemangiopericytoma: a vascular tumor featuring Zimmerman's pericytes. *Ann Surg* 1942;116:26–33
6. Gengler C, Guillou L. Solitary Fibrous tumour and haemangiopericytoma: evolution of a concept. *Histopathology* 2006;48:63–74
7. Zimmermann KW. Der feinere Bau der Blutcapillaren. *Z Anat Entwicklungsgesch* 1923;68:29–109
8. Mikami Y, Shiomi T, Manabe T. Perivascular myoma: case report with immunohistochemical and ultrastructural studies. *Pathol Int* 2002;52:69–74
9. Variend S, Bax NM, Van Gorp J. Are infantile myofibromatosis, congenital fibrosarcoma and congenital haemangiopericytoma histogenetically related? *Histopathology* 1995;26:57–62
10. Fletcher CD. *Diagnostic Histopathology of Tumors*. 2nd ed. Edinburgh, UK: Churchill Livingstone; 2000:77–85
11. Laga AC, Tajirian AL, Islam MN, et al. Myopericytoma: report of two cases associated with trauma. *J Cutan Pathol* 2008;35:866–70
12. Scott RS, Blank KL, Proffer LH, et al. Perivascular myoma of myopericytoma and myofibromatosis-type arising in a chronic scar. *J Cutan Pathol* 2006;33: 231–35
13. Rousseau A, Kujas M, van Effenterre R, et al. Primary intracranial myopericytoma: report of three cases and review of the literature. *Neuropathol Appl Neurobiol* 2005;31:641–48
14. Harish S, O'Donnell P, Briggs TW, et al. Myopericytoma in Kager's fat pad. *Skeletal Radiol* 2007;36:165–69. Epub 2006 Mar 29