

Are your **MRI contrast agents** cost-effective?

Learn more about generic **Gadolinium-Based Contrast Agents**.



**FRESENIUS  
KABI**

caring for life

**AJNR**

## **Klippel-Feil Syndrome and Anterior Cervical Meningomyelocele: A Rare Case Report**

G. Balachandran

*AJNR Am J Neuroradiol* 2009, 30 (9) E130

doi: <https://doi.org/10.3174/ajnr.A1730>

<http://www.ajnr.org/content/30/9/E130>

This information is current as  
of April 17, 2024.

## Klippel-Feil Syndrome and Anterior Cervical Meningomyelocele: A Rare Case Report

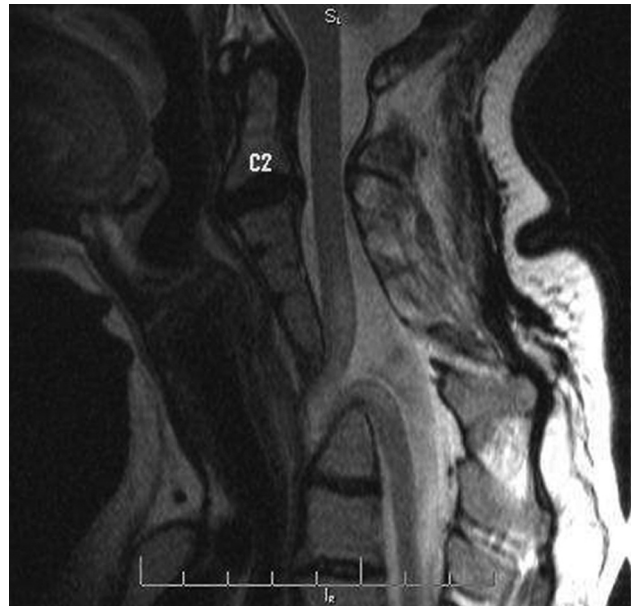We report a case of Klippel-Feil syndrome associated with an anterior cervical meningomyelocele.

A 36-year old female patient was referred for evaluation of bilateral symmetric small muscle wasting in both hands. MR images (Fig 1) showed fusion of cervical vertebrae and neural arches. There was an anterior meningomyelocele at the level of C6 and C7. The cervical spinal cord was kinked, made an anterior loop, and was dragged anteriorly within the widened posterior thecal sac, stretching the nerve roots within the thecal sac. Part of spinal cord (Fig 2) was lying within the spinal canal and part of it was lying outside the anterior vertebral bodies at the level of C6.

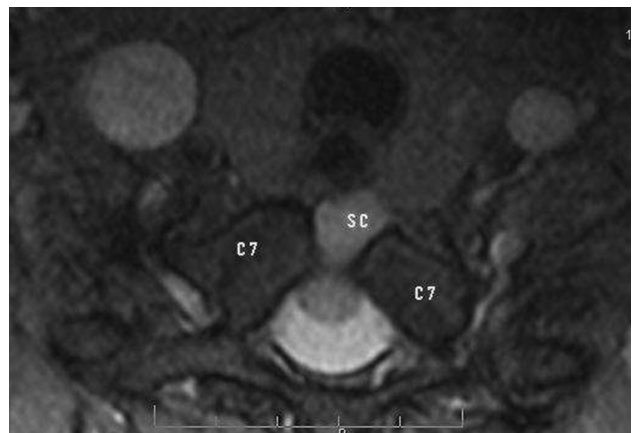
The Klippel-Feil deformity is a complex of osseous and visceral anomalies, which include low hairline, platybasia, fused cervical vertebrae with a short neck, and deafness. Associated central nervous system abnormalities include occipital cephalocele, Chiari I malformation, syrinx, microcephaly, and hydrocephalus. A meningomyelocele is a herniation of the meninges along with the cord through a foramina or defect in the vertebral column and is frequently (> 80%) located posteriorly in the lumbosacral area. An anterior meningomyelocele is rare and is generally described in the thoracic or sacral region.

G. Balachandran  
Department of Radiology  
Government General Hospital  
Pondicherry, India

DOI 10.3174/ajnr.A1730



**Fig 1.** T2-weighted sagittal view of the cervical spine shows fused cervical vertebrae and an anterior meningomyelocele.



**Fig 2.** T2-weighted transverse view of the cervical spine shows herniation of spinal cord (SC) through an anterior defect in the C7 body.