

Are your MRI contrast agents cost-effective?

Learn more about generic Gadolinium-Based Contrast Agents.



**FRESENIUS
KABI**

caring for life

AJNR

Low Incidence of Neurologic Complications during Thoracic Epidurals: Anatomic Explanation

L.E. Imbelloni and M.A. Gouveia

AJNR Am J Neuroradiol 2010, 31 (10) E84

doi: <https://doi.org/10.3174/ajnr.A2227>

<http://www.ajnr.org/content/31/10/E84>

This information is current as of April 24, 2024.

Low Incidence of Neurologic Complications during Thoracic Epidurals: Anatomic Explanation

Central neuraxial block has a low incidence of major complications, many of which resolve within 6 months.¹ During attempts to insert a spinal needle into the lumbar subarachnoid space, patients occasionally experience paresthesia, with a reported incidence of 13.6%.¹ Neurologic complications, including spinal cord injury,² may arise during administration of the epidural block because the needle or catheter may cause direct nerve trauma. Accidental dural puncture during needle insertion occurred in 0.4%–1.2% of instances in a series of 6496 thoracic epidural blocks, but none of the 48 patients developed subsequent neurologic sequelae.^{3–5}

Recently, the anatomy of the thoracic spinal canal was investigated with MR imaging in 50 patients.⁶ The space between the dura mater and spinal cord in the thoracic region measured with MR imaging was 5.19 mm at T2, 7.75 mm at T5, and 5.88 mm at T10 (Fig 1). The angle of entry between T5 and T6 (almost 50°) elongated the distance from the tip of the needle to the posterior surface of the cord. MR imaging (Fig 1) confirms that the cord and the cauda equina are touching the dura mater posteriorly in the lumbar region and anteriorly in the thoracic region (the spinal cord). This position increases the distance to a point that permits the advancement of a needle without touching the cord, such as in the case of accidental perforation of the dura mater during the administration of spinal anesthesia. This can be an explanation for the low incidence of neurologic complications during accidental perforation of the dura mater in an attempt to perform a thoracic epidural block^{3–5} and the safety of segmental spinal anesthesia when using a thoracic approach.^{7,8}

References

1. Pong RP, Gmelch BS, Bernards CM. Does a paresthesia during spinal needle insertion indicate intrathecal needle placement? *Reg Anesth Pain Med* 2009;34:29–32
2. Gibson P. Spinal cord damage following thoracic epidural anaesthesia. *Anaesth Intensive Care* 2004;32:596–97, author reply 597
3. Scherer R, Schmutzler M, Giebler R, et al. Complications related to thoracic epidural analgesia: a prospective study in 1071 surgical patients. *Acta Anaesthesiol Scand* 1993;37:370–74

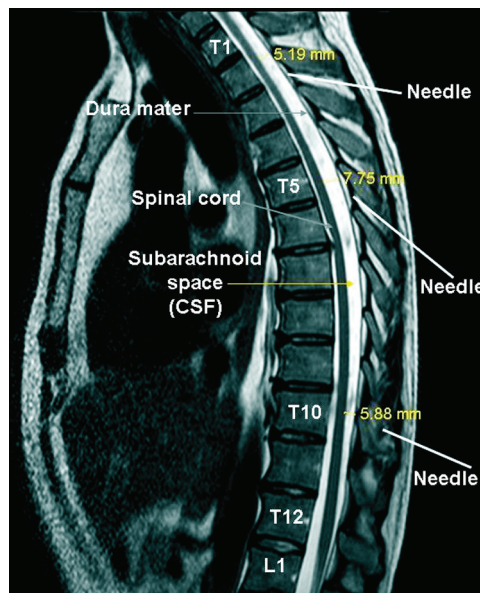


Fig 1. MR imaging of the thoracic column.

4. Giebler RM, Scherer RU, Peters J. Incidence of neurologic complications related to thoracic epidural catheterization. *Anesthesiology* 1997;86:55–63
5. Leão DG. Thoracic epidural anesthesia: analysis of 1240 cases. *Rev Bras Anestesiol* 1997;47:138–47
6. Imbelloni LE, Quirici MB, Ferraz-Filho JR, et al. The anatomy of the thoracic spinal canal investigated with magnetic resonance imaging. *Anesth Analg* 2010;110:1494–95
7. van Zundert AA, Stultiens G, Jakimowicz JJ, et al. Laparoscopic cholecystectomy under segmental thoracic spinal anaesthesia: a feasibility study. *Br J Anaesth* 2007;98:682–86. Epub 2007 Mar 19
8. Imbelloni LE, Fornasari M, Fialho JC. Combined spinal epidural anesthesia during colon surgery in a high-risk patient: case report. *Rev Bras Anestesiol* 2009;59:741–45

L.E. Imbelloni

M.A. Gouveia

Instituto de Anestesia Regional
Hospital de Base-FUNFARME
São José do Rio Preto, SP, Brazil

DOI 10.3174/ajnr.A2227