

Are your MRI contrast agents cost-effective?

Learn more about generic Gadolinium-Based Contrast Agents.



AJNR

Diffusion Tensor Imaging Detects Areas of Abnormal White Matter Microstructure in Patients with Partial Ornithine Transcarbamylase Deficiency

A.L. Gropman, B. Gertz, K. Shattuck, I.L. Kahn, R. Seltzer, L. Krivitsky and J. Van Meter

This information is current as of April 17, 2024.

AJNR Am J Neuroradiol 2010, 31 (9) 1719-1723
doi: <https://doi.org/10.3174/ajnr.A2122>
<http://www.ajnr.org/content/31/9/1719>

**ORIGINAL
RESEARCH**

A.L. Gropman
B. Gertz
K. Shattuck
I.L. Kahn
R. Seltzer
L. Krivitsky
J. Van Meter



Diffusion Tensor Imaging Detects Areas of Abnormal White Matter Microstructure in Patients with Partial Ornithine Transcarbamylase Deficiency

BACKGROUND AND PURPOSE: OTCD, an X-linked disorder, is the most common of the UCDs. Neonatal onset is associated with uniformly poor outcome. Males with late-onset OTCD show deficits in executive function, motor planning, and working memory. A broad phenotype is observed in heterozygous females. A specific neurobehavioral phenotype with white matter dysfunction and impaired attention and working memory has been described. The extent to which the deficits involve specific pathways in the brain is unknown. We hypothesized that DTI would disclose white matter microstructure in OTCD correlating with cognitive deficits.

MATERIALS AND METHODS: Nineteen adults with partial OTCD and 18 adult control subjects ages 19–59 years participated. MR imaging was performed by using a 3T whole-body scanner. Anisotropy was calculated from the eigenvalues of the diffusion tensor by using the FA metric and was compared between the study and control groups.

RESULTS: FA of the frontal white matter was significantly decreased in subjects, indicating changes in white matter microstructure. There was an inverse relationship between FA and disease severity, but not with age.

CONCLUSIONS: Findings of MR imaging in OTCD are often normal in patients with late-onset disease, heterozygotes, or in those not in hyperammonemic crisis. DTI was more sensitive than FSE T2-weighted imaging for detecting abnormalities in normal-appearing white matter. The extent of abnormality correlated with cognitive deficits. The location of the deficits in the frontal white matter is important because this area connects fibers that are vital to executive function, attention, and working memory.

ABBREVIATIONS: CTMT = Comprehensive Trail Making Test; DT = diffusion tensor; DTI = diffusion tensor imaging; EPI = echo-planar imaging; FA = fractional anisotropy index; FLAIR = fluid-attenuated inversion recovery; FSE = fast spin-echo; FSIQ = full-scale IQ; HA = hyperammonemia; Incong-Cong = incongruent-congruent; IQ = intelligence quotient; NA = not applicable; OTCD = ornithine transcarbamylase deficiency; PIQ = performance IQ; ROI = region of interest; UCD = urea cycle disorder; VIQ = verbal IQ; WM = white matter

OTCD is the most common UCD leading to hyperammonemia and substantial cognitive and motor deficits. Neonatal OTCD survivors sustain brain injury with subsequent mental retardation and cerebral palsy.¹ Males with late-onset OTCD are not as severely affected but show deficits in executive function, motor planning, and working memory. A broad phenotype is also seen in heterozygous females, with

symptoms ranging from behavioral and learning disabilities to protein intolerance, strokelike episodes, and hyperammonemic coma.^{2–7} A recent study of heterozygous females found that although the women had average IQ scores, they displayed a specific neurobehavioral phenotype consistent with a nonverbal learning disability, which is associated with white matter or subcortical dysfunction.⁸ Previous autopsy and neuroimaging studies are also consistent with a pattern of neuronal injury leading to white matter damage. However, the extent to which the deficits involve specific pathways in the brain is unknown.

Neurocognitive deficits are a major cause of significant disability in UCD. Observed cognitive changes that immediately follow HA include decreased mental flexibility, impaired attention, poor planning, problems with working memory, and increased impulsivity.⁹ Determining the extent of clinically relevant neuropathology that is associated with UCD, particularly in the milder spectrum of partial enzyme deficiency, is at present problematic. Therefore, quantifiable measures of neuropathology that can be applied to all severities of OTCD to determine the relationship between trauma and persistent disability are needed for more accurate injury-severity grading, prognosis, and treatment.

Received January 5, 2010; accepted after revision March 15.

From the Department of Neurology (A.L.G., B.G., L.K.), Children's National Medical Center, Washington, DC; George Washington University Medical School (A.L.G., B.G., I.L.K.), Washington, DC; and Center for Functional and Molecular Imaging (K.S., R.S., J.V.M.), Georgetown University, Washington, DC.

A.L.G. was supported by a National Center for Research Resources (NCRR) career development award K12RR17613. This work was also funded by grants 5M01RR020359 (NCCR) and 9U54HD061221 (National Institute of Child Health and Human Development).

Please address correspondence to Andrea L. Gropman, MD, Department of Neurology, Children's National Medical Center, 111 Michigan Ave, NW, Washington, D.C. 20010; e-mail: agropman@cnmc.org

 Indicates open access to non-subscribers at www.ajnr.org

 Indicates article with a supplemental on-line table.

DOI 10.3174/ajnr.A2122

Disruption of function can also result from more diffuse damage to white matter tracts. Such diffuse axonal injury can disrupt critical cortical-subcortical pathways and lead to widespread cognitive dysfunction.

Although there is some evidence to suggest that standard T1- or T2-weighted anatomic MR imaging shows promise for quantifying pathophysiology in many disorders of white matter integrity, it may not be as sensitive to the neuropathology of milder injuries.¹⁰

DTI provides an objective means for determining the relationship of cognitive deficits to white matter injury, even in cases where the injury was sustained years before the evaluation. The primary objective of the current investigation was to characterize white matter integrity using DTI in a cohort of patients with late-onset OTCD who were both symptomatic and asymptomatic. A secondary objective was to examine the relationship between white matter integrity and cognition. DTI is a powerful technique that allows identification of white matter tracts invisible by conventional MR imaging and provides a quantitative measure of the microscopic characteristics that are related to the directional organization of the brain. We focused on brain regions where cognitive profiling would lead us to suspect abnormalities in symptomatic heterozygous OTCD women, asymptomatic women, and late-onset hemizygous OTCD men compared with age-matched controls. We hypothesized that with DTI, we could detect evidence of white matter dysfunction in individuals with more subtle symptoms or metabolic abnormalities. We also expected our subjects with OTCD to exhibit differences in the brain areas involved in executive function and fine-motor control, according to the number of hyperammonemic episodes and the disease severity. This information can be used to identify biomarkers for OTCD and follow patients' responses to therapy and the course of the disease.

Materials and Methods

Participants

Nineteen adult patients with partial OTCD and 18 adult controls (without UCDs or neurologic symptoms) participated in this study. Subjects were recruited for the National Institutes of Health–funded Rare Diseases Clinical Research Center, established to study the natural history of UCDs. Participants ranged in age from 19 to 59 years and had IQ scores above 80 as measured by the Wechsler Abbreviated Scales of Intelligence (On-line Table).

Definition of Symptomatic/Asymptomatic OTCD Heterozygotes

The definition of symptomatic versus asymptomatic in the OTCD heterozygotes was based on biochemical, molecular genetic, and clinical criteria. The biochemical criterion was the degree of impairment of urea synthetic capacity based on stable isotope incorporation of ¹⁵N into urea. The clinical observation is that approximately 15% of women heterozygous for OTCD are symptomatic.¹¹ Subjects who had documented hyperammonemic episodes or the presence of protein intolerance, including symptoms of headaches and/or altered conscious state, were designated as symptomatic. Patients were rated by a UCD severity score adapted from a previously reported scoring system.¹¹ Only 3 subjects were undergoing treatment with nitrogen scavengers at the time of study. Rating of disease severity was based on

previously published criteria, which include the number of HA episodes and degree of coma as well as the presence or absence of increased intracranial pressure. No patient in this cohort had experienced elevated intracranial pressure, though some had repeat HA associated with coma.

Cognitive Testing

All patients underwent neurocognitive testing consisting of the CTMT, Part B, a pen and paper task that is norm-referenced and probes executive function and cognitive flexibility, as well as motor speed and visual search, which are impaired in OTCD. They also completed a computerized version of the Stroop Color and Word Test, a test of attention and executive function. We have previously found that performance on these tasks could discriminate individuals with OTCD from age-matched controls and that within the subset of subjects with late-onset OTCD, those with more substantial disease consistently perform worse on these tasks (unpublished results; A.L.G., 2010).^{8,9}

Neuroimaging

MR imaging was performed by using a 3T whole-body MR imaging scanner (Magnetom Trio; Siemens, Erlangen, Germany) and an 8-channel phased array head coil. A DTI sequence was acquired 4 times by using an EPI sequence with 2 diffusion-weighted gradients of $b = 0$ and 1000 s/mm^2 applied in 35 orthogonal directions. Fifty-five axial interleaved sections were acquired with a 2.5-mm^3 spatial resolution (TE = 100 ms, TR = 7700 ms). From the raw data, the diffusion tensor was calculated by using a singular value decomposition.^{12,13} The degree of anisotropy was calculated for each acquisition from the eigenvalues of the diffusion tensor by using the FA metric.¹⁴ Each of the 4 separate DTI scans was registered to the first DTI acquisition by using the $b = 0$ images with a 6-df linear transformation. A mean $b = 0$ image was calculated and used to derive a second-order polynomial warp registration with the Talairach atlas by using the Montreal Neurological Institute–EPI template.^{15–17} These transformations were applied to the individual FA maps, resulting in a single mean FA map in Talairach space for each subject. A 12.0-mm^3 full width at half maximum Gaussian smoothing filter was applied before statistical analyses. Image-quality control is described below. FA was quantified as the SDs of the eigenvalues of the DT normalized by the magnitudes of the 3 eigenvectors of the DT.

The normalized smoothed average images for each of the OTCD and control subjects were entered into voxelwise 2-way t tests by using Statistical Parametric Mapping 5 software (<http://www.fil.ion.ucl.ac.uk/spm>) to produce a statistical parametric map. Reported results are 1-tailed for control subjects having greater FA than OTCD subjects at a significance level of $P < .001$, uncorrected for multiple comparisons.

Quality Control

A rigorous quality-control procedure was performed to remove individual sections and scans that exhibited artifacts arising from motion, eddy currents, or other factors. This procedure included rating each individual acquisition on the basis of visual inspection of the raw diffusion-weighted images, the corresponding FA map, and the accuracy of the registration to the first $b = 0$ image. Any acquisition with >2 sections containing artifacts was eliminated from the calculation of the mean FA map. Each step of the quality-control procedure included a rating scale that was summed to derive an overall

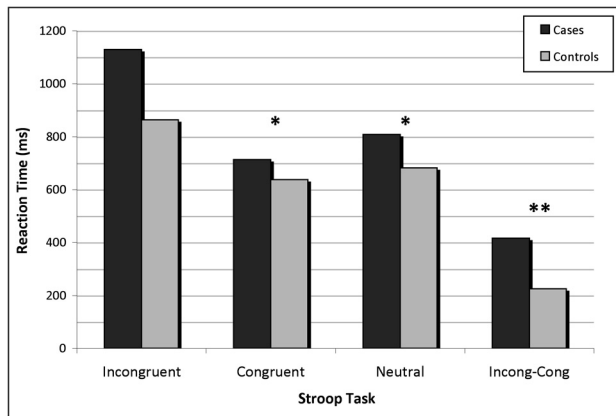


Fig 1. Group means for Stroop tasks. Asterisk indicates $P < .05$; double asterisks, $P < .01$.

quality-control rating for each subject. The summary quality-control rating was assessed to determine whether there were any differences in the overall quality of the DTI data between the populations of subjects.

Results

Patient Demographics

Demographics for OTCD subjects are depicted in the On-line Table. There were 19 subjects with OTCD. Fourteen were symptomatic subjects (21% men), with a mean age of 34 years and a range of 19–59 years, and 18 were healthy controls (39% men), with a mean age of 31 years and a range of 18–59 years.

Cognitive Testing

There was no significant difference in IQ between controls and subjects. Controls had a mean full-scale IQ of 123; subjects, 110 ± 15 . Symptomatic subjects with OTCD had a mean full-scale IQ of 109; asymptomatic subjects, 112. Mean performance IQ in the control group was 120; in subjects, 109. Symptomatic subjects had a mean performance IQ of 107 compared with 113 for asymptomatic subjects.

In measures of executive function, subjects with OTCD showed significantly worse performance. Compared with controls, they demonstrated increased reaction time on the Stroop Color and Word Test (Fig 1) and poorer performance on the CTMT (Fig 2), especially on tests 4 and 5, which are the most challenging ($P < .01$) and require a higher level of attention. Symptomatic subjects consistently showed poorer performance than asymptomatic OTCD subjects on the CTMT and a similar, though not significant, trend on the Stroop.

DTI

Statistical parametric analysis of the FA data showed regions of decreased FA in the frontal white matter in subjects compared with controls. The sum of these areas of significant difference formed our region of interest. Representative sagittal and coronal sections of the region of interest are shown in Fig 3.

Relationship between White Matter Integrity and Neuropsychological Function

To examine the relationship between white matter integrity and neuropsychological function, we conducted a series of

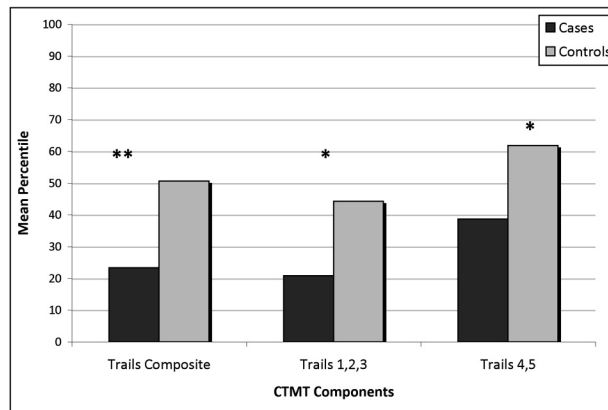


Fig 2. Group means for sections of the CTMT. Asterisk indicates $P < .01$; double asterisks, $P < .001$.

correlations for the entire group of OTCD subjects. For subjects, linear regression analysis showed positive correlations between FA in the frontal white matter and lower scores on the CTMT ($R = 0.6$, Fig 4) and longer reaction times on the Stroop ($R = 0.4$, Fig 5). For controls, there was no significant correlation between FA and performance.

Age-Related Relationships

When we explored the relationship between age and mean FA in the region of interest for each group, no correlation was found in either the controls ($R = 0.10$) or the subjects ($R = 0.09$). When further subdivided, neither the symptomatic nor the asymptomatic subjects showed significant correlations, with R values of 0.19 and 0.11, respectively.

Discussion

We found significant differences in white matter tissue organization in individuals with OTCD. Our results indicate that FA of the frontal white matter was significantly different in OTCD subjects versus control adults. Mean FA was lower in subjects with partial OTCD, indicating changes in white matter microstructure in this region. When separated into symptomatic and asymptomatic groups, both groups displayed reduced FA, with the symptomatic group more significantly different from age-matched controls. Additionally, when correlated with disease-severity scores (a measure of the number of clinically evident previous hyperammonemic events), there was an inverse relationship between FA and disease severity. Because fiber tracts connecting these regions underlie executive function and working memory, DTI provides an objective means for determining the relationship to cognitive deficits in OTCD. The finding of reduced FA in white matter tracts related to frontal lobe function suggests an anatomic correlate to our findings of deficits of executive function in OTCD heterozygotes, even those who are asymptomatic.

Even injuries classified as mild can result in persistent neurobehavioral impairment as documented by previous studies.^{8,9} White matter injury is a common finding in UCD and is presumed to contribute to outcomes but may not always be apparent by using standard neuroimaging. DTI is a more recent method of assessing axonal integrity in vivo. In addition, DTI images can provide additional quantitative MR imaging

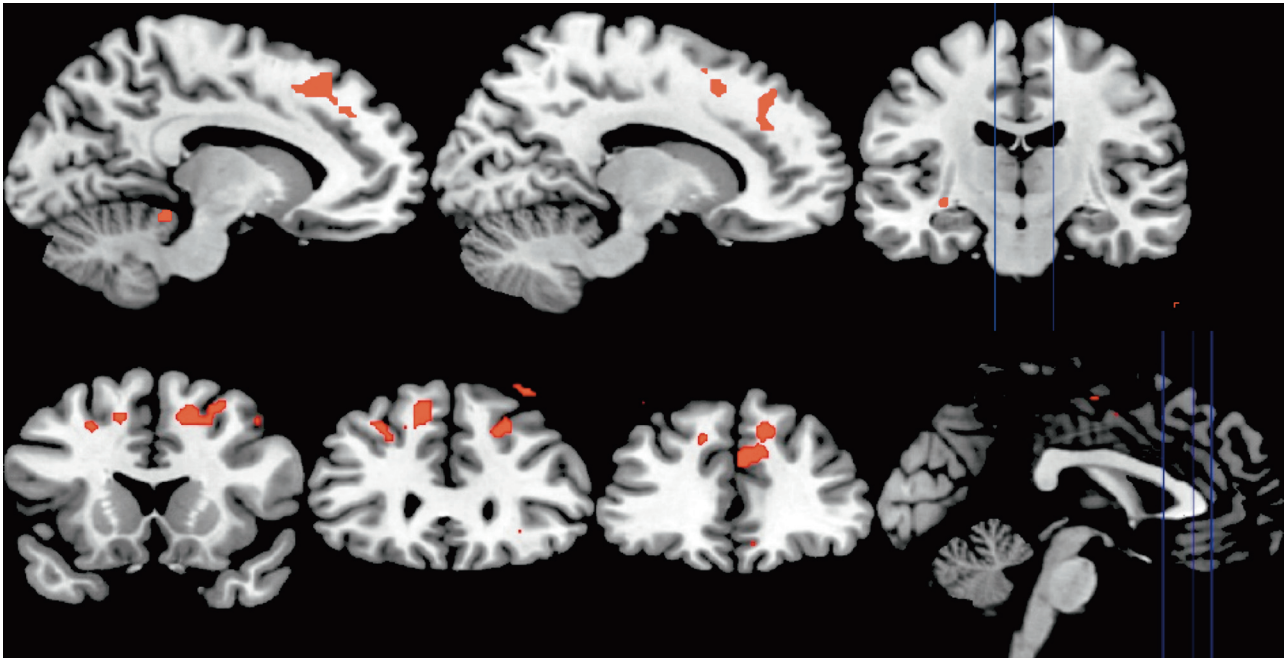


Fig 3. Region of Interest. Voxels with significantly lower FA in subjects compared with controls ($P < .001$) overlaid on a standardized brain structural MR image.

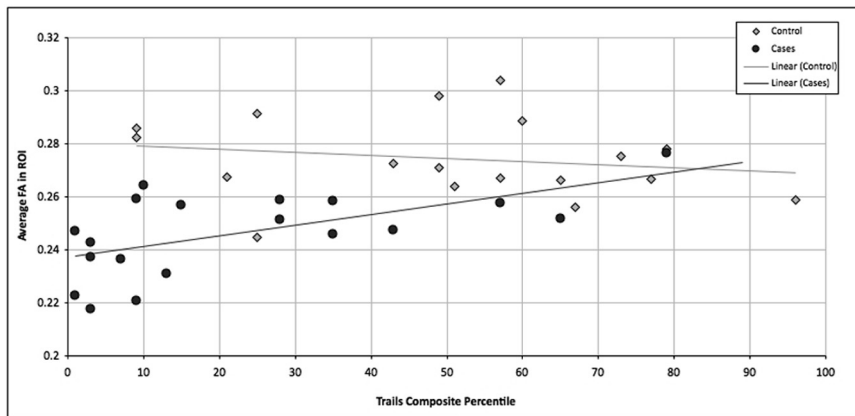


Fig 4. Scatterplot with linear regression showing average FA in the region of interest versus the CTMT composite percentile in subjects ($R = 0.6$) and controls ($R = 0.2$).

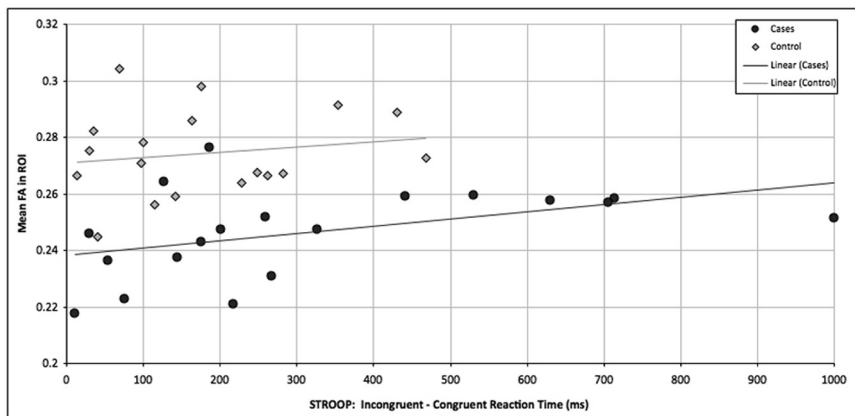


Fig 5. Scatterplot with linear regression showing average FA in the region of interest versus Stroop performance for subjects ($R = 0.4$) and controls ($R = 0.2$).

parameters for assessing and monitoring patients with time and their response to diet and therapies.

In our cohort of patients with partial OTCD, no definite abnormal signal-intensity changes were found on T2-weighted

MR images. Although these patients were treated early and many were asymptomatic, they still had abnormal findings on DTIs. In our study, DTIs were more sensitive than FSE T2-weighted images for detecting abnormalities in the nor-

mal-appearing white matter. FA is a measure of the relative ease with which water moves in tissues. Physical barriers, such as cell bodies, axons, and myelin, restrict water diffusion. If movement is restricted to a single direction, such as along attenuated bundles of axonal projections, the FA in that tissue is high. When the structural integrity of the white matter is perturbed, the FA will be lower as seen in our subjects.

Attention and working memory rely on information processing by several well-identified gray matter regions, which may explain the cognitive phenotype seen in this disorder, in which there are impairments in executive function, working memory, and fine-motor skills.

Studying the effects of damage to frontal white matter provides insights into the type of functions it serves in the intact brain. Behavior that is associated with lesions in the frontal white matter includes executive function, which allows us to detect errors, resolve stimulus conflict, and contributes to emotional instability and inattention.^{18,19}

A typical task that requires integrity of white matter pathways in frontal white matter involves eliciting some form of conflict within the participant that can potentially result in an error. We used the Stroop and CTMT tasks as tests presenting such conflict. The classic Stroop task involves naming the ink color of words that are either congruent (“RED” written in red) or incongruent (“RED” written in blue). Conflict occurs because a subject’s reading ability interferes with the attempt to correctly name the ink color of the word. In the CTMT, participants are tasked with connecting circles in order according to a rule. Conflict is introduced with distracters and increasingly complicated rules.

Conclusions

As predicted, significant associations between DTI measures and neurocognition were found in the OTCD group. While the precise microstructural correlates of FA remain unknown, DTI is capable of detecting changes in white matter that occur in OTCD, providing a marker of white matter integrity. These data provide strong evidence for frontal white matter disruptions in OTCD, which may be associated with disease-related attention and working memory abnormalities. Similar findings have been seen in other inborn errors of metabolism that affect white matter and show deficits in executive function, attention, and working memory (phenylketonuria), and these

findings suggest a comparable vulnerability, though they involve differing biochemical mechanisms.²⁰

References

1. Batshaw ML, Brusilow S, Waber L, et al. **Treatment of inborn errors of urea synthesis: activation of alternative pathways of waste nitrogen synthesis and excretion.** *N Engl J Med* 1982;306:1387–92
2. Batshaw ML, Hyman SL, Mellits ED, et al. **Behavioral and neurotransmitter changes in the urease-infused rat: a model of congenital hyperammonemia.** *Pediatr Res* 1986;20:1310–15
3. Christodoulou J, Quereshi A, McInnes RR, et al. **Ornithine transcarbamylase deficiency presenting with stroke like episodes.** *J Pediatr* 1983;122:423–25
4. Maestri NE, Brusilow SW, Clissold DB, et al. **Long-term treatment of girls with ornithine transcarbamylase deficiency.** *N Engl J Med* 1996;335:855–59
5. Maestri NE, Lord C, Glynn M, et al. **The phenotype of ostensibly healthy women who are carriers for ornithine transcarbamylase deficiency.** *Medicine (Baltimore)* 1998;77:389–97
6. Mamourian AC, Du Plessis A. **Urea cycle defect: a case with MR and CT findings resembling infarct.** *Pediatr Radiol* 1991;21:594–95
7. Pridmore CL, Clarke JT, Blaser S. **Ornithine transcarbamylase deficiency in females: an often overlooked cause of treatable encephalopathy.** *J Child Neurol* 1995;10:369–74
8. Gyato K, Wray J, Huang ZJ, et al. **Metabolic and neuropsychological phenotype in women heterozygous for ornithine transcarbamylase deficiency.** *Ann Neurol* 2004;55:80–86
9. Krivitzky L, Babikian T, Lee HS, et al. **Intellectual, adaptive, and behavioral functioning in children with urea cycle disorders.** *Pediatr Res* 2009;66:96–101
10. Kolind SH, Laule C, Vavasour IM, et al. **Complementary information from multi-exponential T2 relaxation and diffusion tensor imaging reveals differences between multiple sclerosis lesions.** *Neuroimage* 2008;40:77–85
11. Msall M, Monahan, PS, Chapanis N, et al. **Cognitive development in children with inborn errors of urea synthesis.** *Acta Paediatr* 1988;30:435–41
12. Basser PJ, Mattiello J, LeBihan D. **Estimation of the effective self-diffusion tensor from the NMR spin echo.** *J Magn Reson B* 1994;103:247–54
13. Basser PJ, Mattiello J, LeBihan D. **MR diffusion tensor spectroscopy and imaging.** *Biophys J* 1994;66:259–67
14. Basser PJ, Pierpaoli C. **Microstructural and physiological features of tissues elucidated by quantitative-diffusion-tensor MRI.** *J Magn Reson B* 1996;111:209–19
15. Talairach J, Tournoux P. **Co-planar stereotaxic atlas of the human brain: 3-dimensional proportional system—an approach to cerebral imaging.** New York: Thieme Medical Publishers; 1988
16. Woods RP, Grafton ST, Holmes CJ, et al. **Automated image registration. I. General methods and intrasubject, intramodality validation.** *J Comput Assist Tomogr* 1998;22:139–52
17. Woods RP, Grafton ST, Watson JD, et al. **Automated image registration. II. Intersubject validation of linear and nonlinear models.** *J Comput Assist Tomogr* 1998;22:153–65
18. Botvinick MM. **Conflict monitoring and decision making: reconciling two perspectives on anterior cingulate function.** *Cog Affect Behav Neurosci* 2007;7:356–66
19. Rushworth MF, Hadland KA, Paus T, et al. **Role of the human medial frontal cortex in task switching: a combined fMRI and TMS study.** *J Neurophysiol* 2002;87:2577–92
20. Anderson PJ, Leuzzi V. **White matter pathology in phenylketonuria.** *Mol Gen Metab* 2010;99(suppl 1):S3–S9