

Are your MRI contrast agents cost-effective?

Learn more about generic Gadolinium-Based Contrast Agents.



FRESENIUS
KABI

caring for life

AJNR

**Cavitating Leukoencephalopathy in a Child
Carrying the Mitochondrial A8344G
Mutation**

R. Biancheri, D. Rossi, D. Cassandrini, A. Rossi, C. Bruno
and F.M. Santorelli

This information is current as
of April 17, 2024.

AJNR Am J Neuroradiol 2010, 31 (9) E78-E79

doi: <https://doi.org/10.3174/ajnr.A2182>

<http://www.ajnr.org/content/31/9/E78>

Cavitating Leukoencephalopathy in a Child Carrying the Mitochondrial *A8344G* Mutation

Mitochondrial disorders are usually characterized by the combination of deep gray and white matter involvement on brain imaging. However, a selective white matter involvement has been reported in specific mitochondrial diseases, including Leber hereditary optic neuropathy, myoneurogastrointestinal encephalomyopathy, and mitochondrial encephalomyopathy with lactic acidosis and stroke-like syndrome as well as in isolated deficiencies of respiratory chain complexes. The presence of isolated and well-delineated cysts within the abnormal white matter has been described as suggestive of mitochondrial defects.¹

Myoclonus epilepsy with ragged-red fibers (MERRF) is a mitochondrial disease characterized by myoclonus, seizures, mental deterioration, cerebellar ataxia, and muscular weakness. Typically, it is caused by the m.8344A>G mutation of DNA.

We describe a severe cavitating leukoencephalopathy in a child carrying the 8344A>G mitochondrial DNA (mtDNA) mutation. The patient, born at term after an uneventful pregnancy, underwent ocular surgery due to bilateral cataracts at 5 months of age. He developed normally

until 17 months when he showed psychomotor regression, losing the ability to sit and stand unaided. The neurologic examination showed nystagmus, extreme irritability, generalized muscular hypertonia, bilateral Babinski sign, and swallowing and feeding difficulties, which required percutaneous gastrostomy. Findings were normal for the following studies: routine blood and urine examinations, including quantitative determination of amino acids, organic acids, and lactate (Lac); funduscopy; electromyography; nerve-conduction velocity studies; electrocardiography; and echocardiography. Brain MR imaging findings are shown in Fig 1A–E. MR spectroscopy showed increased choline (Cho)/creatinine (Cr), reduced *N*-acetylaspartate (NAA)/Cr, and the presence of Lac (Fig 1). Electroencephalography showed a slow background activity without epileptic anomalies. Enzyme histochemistry of the muscle biopsy revealed several fibers showing evidence of subsarcolemmal mitochondrial accumulation typical of ragged-red changes. Analysis of respiratory chain complex activities in a skeletal muscle homogenate showed a decrease in complexes I+III and II+III activities with residual activity approximately 27.6% and 32%, respectively, of control values when expressed relative to the activity of the matrix marker enzyme citrate synthase.

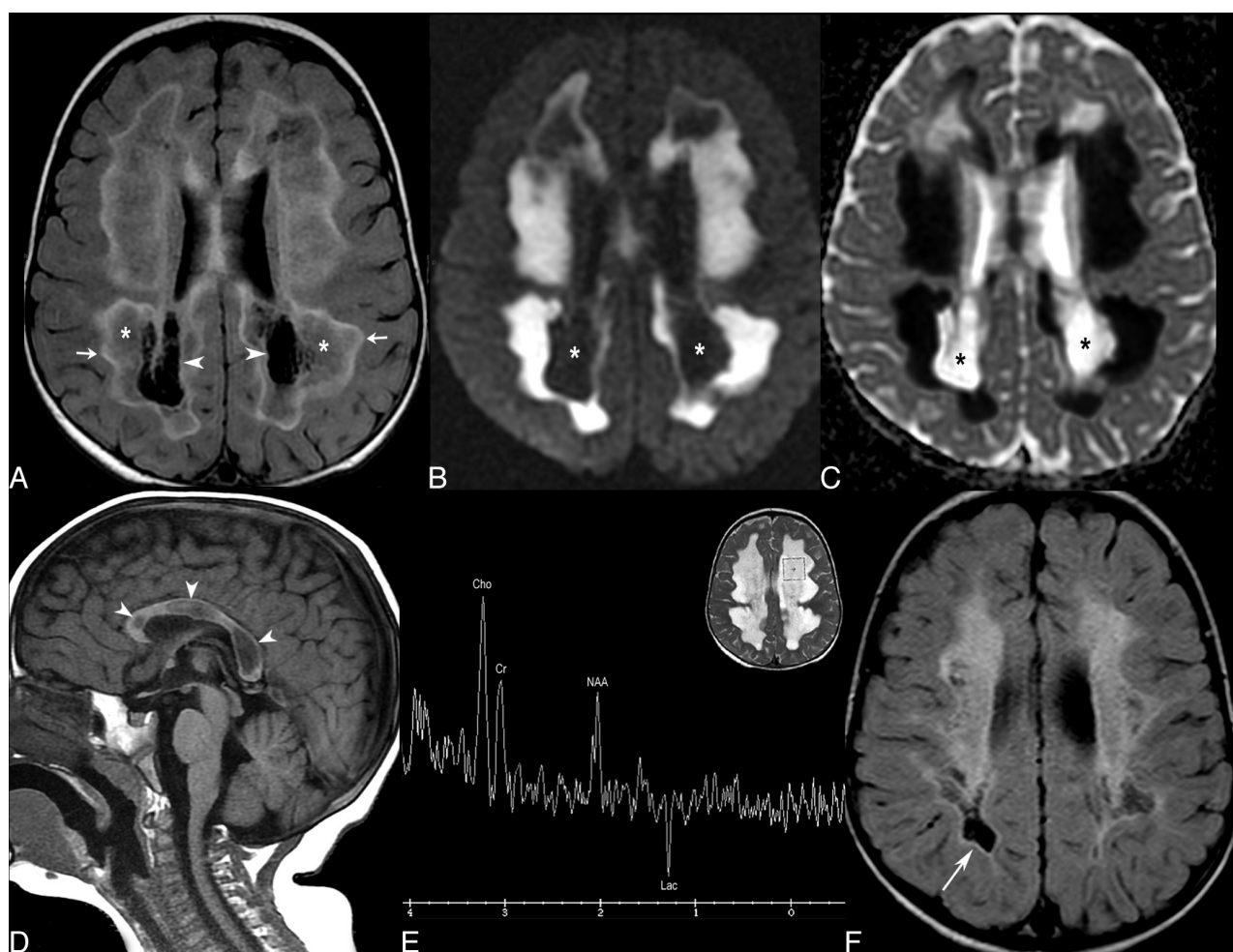


Fig 1. A–E, Brain MR images at 18 months of age. F, Follow-up MR image at 33 months of age. A, Axial fluid-attenuated inversion recovery (FLAIR) image shows a concentric pattern of leukoencephalopathy with central cavitations (arrowheads), intermediate isointensity (asterisks), and an outer hyperintense rim (arrows). The subcortical white matter is spared. B and C, Axial diffusion-weighted image (B) and corresponding apparent diffusion coefficient map (C) show extensive restriction of diffusivity in the abnormal white matter with increased diffusivity in the central cavitations (asterisks). D, Sagittal T1-weighted image shows involvement of the corpus callosum with swelling and central cavitations (arrowheads). E, Proton MR spectroscopy obtained with a single-voxel point-resolved spectroscopy sequence technique at a TE of 144 ms. Sampling of the abnormal white matter of the left frontal lobe shows increased Cho/Cr and reduced NAA/Cr ratios, and Lac at 1.44 ppm. F, Axial FLAIR image obtained in the burnt-out stage with atrophic involution of the affected white matter and collapsed cavitations (arrow). There was corresponding increased diffusivity of affected white matter (not shown).

mtDNA analyses disclosed the 8344A>G mutation, which accounted for 92%, 88%, and 87% of total mitochondrial genomes on blood, muscle specimen, and cultured fibroblasts, respectively. The mutation was not detectable in blood and urine from the healthy mother. At age 33 months, the patient showed a better reactivity to the environment, was able to pronounce a few words, though dysarthric, and could stand with support. Brain MR imaging features are shown in Fig 1F.

MERRF is usually characterized by a long-standing history of myoclonic epilepsy, proximal myopathy, sensorineural deafness, and cerebellar ataxia. The age at onset and clinical features are variable, though the onset is usually in adolescence or early adulthood. Brain MR imaging usually shows cerebral atrophy and basal ganglia, brain stem, and cerebellum involvement.

Only a few patients younger than 2 years of age carrying the m.8344A>G mutation have been reported in the literature and presentation usually includes developmental delay, hypotonia, failure to thrive, lactic acidosis, and respiratory difficulties resembling Leigh syndrome. Accordingly, neuroimaging shows basal ganglia and brain stem involvement.²

Our patient presented with an infantile onset of psychomotor regression with rapid neurologic worsening, preceded by the occurrence of bilateral cataracts. Despite the absence of lactic acidosis in blood or urine, MR imaging evidence of a severe cavitating leukoencephalopathy associated with a Lac peak on MR spectroscopy led us to consider a mitochondrial disorder.

In the differential diagnosis of white matter disorders, some special MR imaging features have a high diagnostic value. Among these, cystic white matter degeneration has been described in a limited number of conditions.¹ In childhood ataxia with central hypomyelination/vanishing white matter disease, cystic degeneration occurs diffusely and usually there are no well-delineated isolated cysts. In Alexander disease, cysts prevail in the frontal white matter. In neonatal hypoxia-ischemia, cavitations tend to be diffuse, whereas in neonatal hypoglycemia, they often affect the parieto-occipital white matter. Megalencephalic leukoencephalopathy with subcortical cysts is characterized by anterior temporal cysts and increased head circumference. Either isolated or combined deficiencies of respiratory chain complexes may show isolated and well-delineated cysts within the abnormal white matter. In particular, bilateral symmetric white matter hyperintensity with cystic vacuolation also involving the corpus callosum has been reported in 2 siblings with severe infantile encephalomyopathy caused by a mutation in *COX6B1*.³

Finally, although as yet molecularly uncharacterized, progressive cavitating leukoencephalopathy (PCL) with irregular asymmetric patchy areas of white matter abnormality evolving into cystic degeneration

has been described.⁴ The cystic changes preferentially involve the corpus callosum, cerebral and cerebellar white matter, and spinal cord. A variable degree of contrast enhancement is reported. In the terminal stages, cystic degeneration involves all of the white matter of the cortical regions and spinal cord, with a relative sparing of the U-fibers and gray matter. An abnormal peak of Lac is depicted on MR spectroscopy. MR imaging of PCL is markedly similar to that in the case described here, with the more important differences being the absence, in the present case, of cerebellar and spinal cord abnormalities and contrast enhancement.

The subacute onset of neurologic symptoms, with rapid clinical worsening is unusual in the infantile presentation of the “typical” m.8344A>G-MERRF mutation. In our case, brain MR imaging and MR spectroscopy played an important role in suggesting a possible mitochondrial encephalopathy.

In conclusion, the presence of a severe cavitating leukoencephalopathy with evidence of an elevated Lac peak at MR spectroscopy should prompt a thorough mitochondrial evaluation and lends further evidence to the spectrum of white matter lesions in mtDNA-related disorders.

References

1. Schiffmann R, van der Knaap MS. **Invited article: an MRI-based approach to the diagnosis of white matter disorders.** *Neurology* 2009;72:750–59
2. Orcesi S, Gorni K, Termine C, et al. **Bilateral putaminal necrosis associated with the mitochondrial DNA A8344G myoclonus epilepsy with ragged red fibers (MERRF) mutation: an infantile case.** *J Child Neurol* 2006;21:79–82
3. Massa V, Fernandez-Vizorra E, Alshahwan S, et al. **Severe infantile encephalomyopathy caused by a mutation in COX6B1, a nucleus-encoded subunit of cytochrome C oxidase.** *Am J Hum Genet* 2008;82:1281–89. Epub 2008 May 22
4. Naidu S, Bibat G, Lin D, et al. **Progressive cavitating leukoencephalopathy: a novel childhood disease.** *Ann Neurol* 2005;58:929–38

R. Biancheri

D. Rossi

Child Neurology and Psychiatry Unit

D. Cassandrini

Muscular and Neurodegenerative Disease Unit

A. Rossi

Pediatric Neuroradiology

G. Gaslini Pediatric Institute

Genova, Italy

C. Bruno

F.M. Santorelli

Instituto Ricovero e Cura a Carattere Scientifico

Fondazione Stella Maris

Pisa, Italy

DOI 10.3174/ajnr.A2182