

Are your MRI contrast agents cost-effective?

Learn more about generic Gadolinium-Based Contrast Agents.



AJNR

Rupture of Benign Thyroid Tumors after Radio-Frequency Ablation

J.H. Shin, S.L. Jung, J.H. Baek and J.-h. Kim

AJNR Am J Neuroradiol 2011, 32 (11) 2165-2169

doi: <https://doi.org/10.3174/ajnr.A2661>

<http://www.ajnr.org/content/32/11/2165>

This information is current as
of April 17, 2024.

CLINICAL REPORT

J.H. Shin
S.L. Jung
J.H. Baek
J.-h. Kim

Rupture of Benign Thyroid Tumors after Radio-Frequency Ablation

SUMMARY: Rupture of benign thyroid tumors after RFA is very rare. We experienced 6 cases in 4 institutions. All patients presented with abrupt neck swelling and pain between 9 and 60 days after RFA. Imaging and clinical findings of the ruptured tumors were anterior subcapsular location, mixed composition, large size, and repeated ablations. Conservative treatment was sufficient in 3 cases, whereas surgical management was required in 3.

ABBREVIATIONS: AT = active time; BTT = benign thyroid tumor; FNAB = fine-needle aspiration biopsy; IV = intravenous; MP = maximum power; RF = radio-frequency; RFA = radio-frequency ablation

RFA for malignant and benign tumors is a minimally invasive treatment tool with good outcome and low morbidity and mortality.¹⁻⁴ During the past 10 years, RFA has been increasingly used to treat liver tumors,⁵⁻¹¹ and its application has been extended to other organs, such as the lung, bone, kidney, breast, spleen, thyroid, and tongue because of easy and safe handling and excellent and consistent control of the ablation area.^{5,6,12-16} RFA of benign thyroid tumors has markedly increased along with the higher incidence of thyroid tumors, with good results.^{1,2,17,18}

Although RFA is relatively safe, it is, nevertheless, a complicated procedure and requires substantial experience. The operator needs to be fully aware of the complication spectrum. Rupture after RFA is 1 of the rare complications and has been reported in liver RFA.^{4,19} However, there have been no reported ruptures of BTTs after RFA. We present our experiences and the clinical and imaging findings, including the management, in 6 patients with BTT rupture after RFA.

Case Reports

A total of 1491 patients with benign thyroid nodules were treated with sonographically guided RFA between June 2002 and February 2010, at 4 institutions of the Korean Society of Thyroid Radiology group. Altogether 2616 ablation procedures were performed by 4 radiologists with 1–8 years of experience with thyroid RFAs. Six cases (0.2%) with rupture as a complication of RFA were retrospectively reviewed with respect to tumor characteristics, clinical and imaging findings (sonography or CT), and management.

All nodules were found to be benign by FNAB. All ablations were performed by using a RF generator (Cool-tip; Radionics; Palm Coast, Florida) and a 7-cm-length, 18-ga, 1-cm active-tip internally cooled electrode (Well-Point RF Electrode; Taewoong Medical, Soeul, Ko-

rea). Indifferent dispersive electrode pads applied to both thighs were attached to the generator, and the generator was connected to the RF needle electrode. The RF output of the generator ranged from 30 W to the maximum watt level. Patients were positioned with their necks hyperextended and injected with 2% lidocaine for local anesthesia at the puncture site. The transisthmic approach with sonographic guidance was used to insert an electrode along the short axis of the nodule, and the nodules were managed by using the moving-shot technique.^{1,17} The electrode tip was initially positioned at the deepest and most remote region of the tumor, and the electrode tip was moved to a nonablated site within the tumor after the occurrence of microbubbles at the ablation site.^{1,17} Real-time sonography was guided during treatment by using a 5- to 12-MHz linear transducer.

Acceptable post-RFA nodule features were defined as the change in the echogenicity of the tumor and the overall transient hyperechoic zones seen on sonography. Indications for repeat ablations were unsatisfactory volume reductions (<50%) of treated nodules in 3 months and the presence of the initial nontreated portion (≥30%). The definition of tumor rupture after RFA in the thyroid gland was the breakdown of the thyroid capsule and the communication between the intra- and extrathyroidal lesions.

Patient 1

A 28-year-old man presented with a cosmetic problem of a BTT. Sonography depicted a large mass with a dominant >50% cystic component, 23 × 37 × 46 mm, at the anterior portion of the left thyroid gland (Fig 1). He initially underwent RFA with an MP of 80 W for 25 minutes of AT. A second RFA was performed due to unsatisfactory volume reduction during the follow-up period with an MP of 80 W for 20 minutes of AT. He reported sudden neck swelling and pain on the left neck 50 days after the second RFA. Sonography showed the breakdown of the anterior thyroid capsule and the communication between intra- and extrathyroidal lesions at the RF site. We diagnosed rupture of the BTT after RFA. He was monitored with no invasive procedures. Twenty months' follow-up sonography after the rupture demonstrated only an ill-defined focal low echogenicity, suggesting the scar.

Patient 2

A 29-year-old woman presented with concern about having thyroid cancer. She had a BTT that was confirmed by FNAB. Sonography demonstrated a predominantly cystic mass (>50% cystic portion,

Received February 28, 2011; accepted March 18.

From the Department of Radiology and Center for Imaging Science (J.H.S.), Samsung Medical Center, Sungkyunkwan University School of Medicine, Seoul, Korea; Department of Radiology (S.L.J.), Seoul St. Mary's Hospital, Catholic University of Korea, Seoul, Korea; Department of Radiology and Research Institute of Radiology (J.H.B.), University of Ulsan College of Medicine, Asan Medical Center, Seoul, Korea; Department of Radiology and Thyroid Center (J.H.B.), Daerim St. Mary's Hospital, Seoul, Korea; and Department of Radiology (J.-h.K.), Seoul National University College of Medicine, Seoul National University Hospital, Seoul, Korea.

Please address correspondence to So Lyung Jung, MD, Department of Radiology, Seoul St. Mary's Hospital, Catholic University of Korea, 505 Banpo-Dong, Seocho-Gu, Seoul 137-701, Korea; e-mail: sljung1@catholic.ac.kr

<http://dx.doi.org/10.3174/ajnr.A2661>

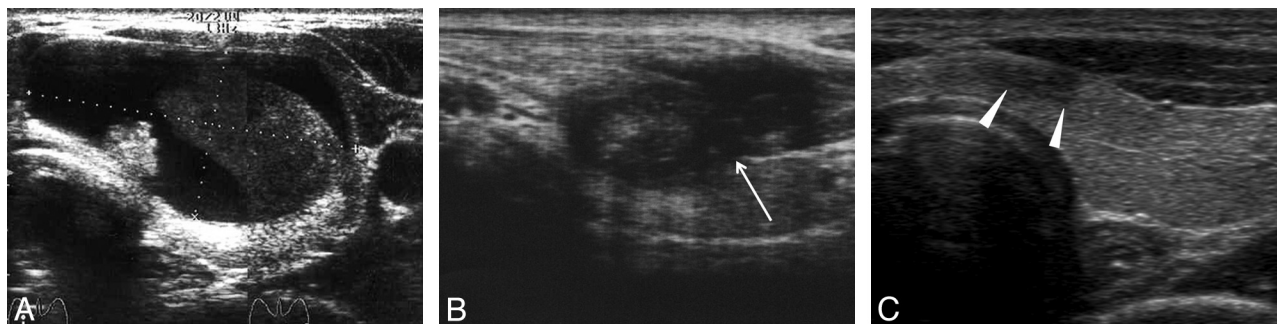


Fig 1. Patient 1. BTT of the left thyroid gland in a 28-year-old man. *A*, A mixed echoic tumor (dotted lines) of the left thyroid gland is treated with RFA twice. He had a sudden swelling and pain on the left side of his neck 50 days after the second RFA. *B*, Rupture (arrow) of the tumor is diagnosed by sonography. He was monitored with no invasive procedures. *C*, Follow-up sonogram at 20 months shows a small low echoic scar (arrowheads).

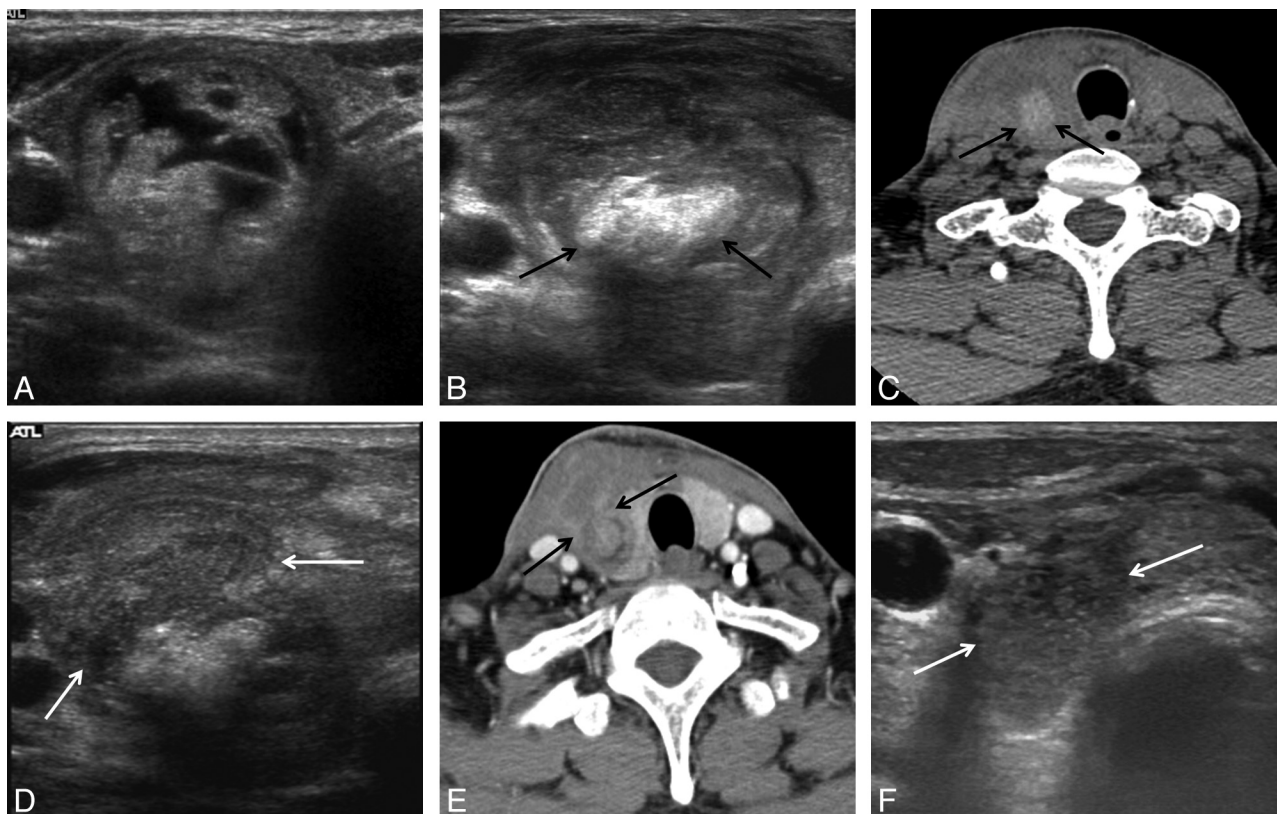


Fig 2. Patient 3. BTT of the right thyroid gland in a 60-year-old man. *A*, A mixed cystic and solid tumor is treated with RFA twice. After the second RFA, the tumor is smaller at 1-week sonography (not shown). *B* and *C*, At 25 days, sonogram (*B*) and precontrast CT (*C*) show volume expansion and new hyperechoic and high-attenuation portions (arrows) representing intranodular bleeding. He had sudden swelling and pain on the right side of his neck 1 month after the second RFA. *D* and *E*, Tumor rupture is diagnosed by sonogram (*D*, arrows) and a postcontrast CT (*E*, arrows). *F*, The patient was managed with IV antibiotics, and the lesion gradually regressed (arrow).

11 × 16 × 23 mm) in the anterior portion of the left thyroid gland. Three sessions of RFA were performed with an MP of 70 W for 20 minutes of AT, an MP of 80 W for 14 minutes of AT, and an MP of 50 W for 6 minutes of AT sequentially. She had abrupt neck pain and swelling on the RFA site 60 days after the third RFA. The BTT was ruptured via the anterior capsule of the thyroid into the anterior strap muscle, detected by sonography. The lesion ultimately disappeared without medication or intervention.

Patient 3

A 60-year-old man (Fig 2) presented with pressure symptoms of a BTT. Sonography demonstrated a large mass with dominantly cystic components (>50%, 24 × 23 × 35 mm) in the anterior portion of the right thyroid gland. He was treated with RFA twice with an

MP of 70 W for 20 minutes of AT and an MP of 90 W for 21 minutes of AT sequentially. One-week follow-up sonography after the second RFA showed decreased size of the BTT. Sonography and precontrast CT 25 days after the second RFA showed the volume expansion and new hyperechoic and high-attenuation portions, suggesting intratumoral bleeding in the treated BTT. He had sudden swelling and pain on his right neck 30 days after the second RFA. Tumor rupture via the anterior thyroid capsule was diagnosed by sonography and CT. An initial aspiration was performed for decompression and bacterial culture. A small amount of semi-solid bloody material was aspirated, and no bacterial growth was seen in the culture. An aspiration of internal contents was not helpful in relieving the symptoms because they were too semisolid to allow decompression of the volume. The patient was managed

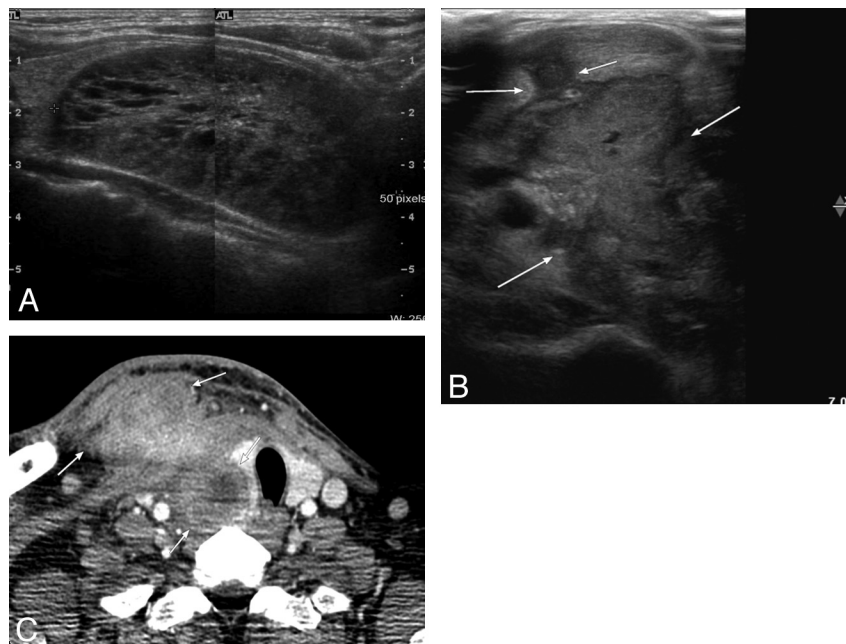


Fig 3. Patient 5. A BTT of the right thyroid gland in a 36-year-old man. A, A 6.4-cm spongiform tumor is successfully treated with RFA. The 1-month follow-up sonogram after RFA shows a decrease in the tumor volume (54.9 to 34.2 mL). When he had abrupt neck pain and swelling 2 months after RFA, sonographically guided aspiration was performed. A small 2-mL semisolid blood clot was aspirated. Skin redness and pain developed, despite the patient taking oral antibiotics. B, Sonogram shows an aspiration tract from the needle (short arrows) and the rupture site (long arrows). C, Postcontrast CT scan shows a developed abscess and the ruptured tumor (arrows) into the right anterior neck. A right lobectomy was ultimately performed.

with IV antibiotics, and the lesion gradually regressed without further treatment.

Patient 4

A 53-year-old man presented with pressure symptoms caused by a BTT. Sonography showed a large mass with predominantly solid components (>50% solid portion, 51 × 29 × 50 mm) in the anterior portion of the left thyroid gland. It compressed the trachea and was treated with 1 session of RFA. AT and MP were 40 minutes and 80 W, respectively. Initial follow-up sonography after RFA showed a decreased size of the mass. When he complained of abrupt pain and neck swelling 22 days after RFA, the rupture was diagnosed by sonography, showing the disruption of the anterior thyroid capsule and the connection between the intra- and extrathyroidal lesions. Diffuse increased echogenicity was also seen within the BTT. Precontrast CT demonstrated high attenuation in the necrotic portion of the BTT. Aspiration was performed for debulking, but it was not sufficient to remove the hematoma. There was no bacterial growth in a culture set. He was initially observed with pain control, but the pain worsened and his neck became red several days after the diagnosis of the rupture, despite receiving antibiotics. He was finally managed with incision and drainage.

Patient 5

A 36-year-old man (Fig 3) presented with the cosmetic problem of a large BTT. It measured 51 × 29 × 50 mm, showed spongiform components, and was located in the anterior portion of the right thyroid gland on sonography. He underwent 1 session of RFA with an MP of 130 W for 35 minutes of AT. He tolerated the procedure well, and the lesion size had decreased at the 1-month follow-up sonography. He had an abrupt cervical swelling and pain on the RFA site 60 days after the procedure. Sonography showed breakdown of the anterior thyroid capsule and invagination of hypoechogenicity into the anterior

strap muscle from the ruptured BTT. Approximately 2 mL of semi-solid blood clot was aspirated. No bacterial growth was identified. He revisited the emergency center with skin redness and aggravated pain during 2 weeks of medication. CT showed rupture of the BTT via the anterior thyroid capsule and associated cellulitis of the anterior neck. Unilateral lobectomy was performed.

Patient 6

A 52-year-old woman had a BTT with a cosmetic problem. Sonography showed a 25 × 15 × 32 mm solid nodule in the anterior portion of the left thyroid gland. She was treated with RFA twice. Initial RFA was performed with an MP of 80 W for 22 minutes of AT and a second RFA was performed with 100 W for 20 minutes of AT. She had abrupt neck swelling and pain 9 days after the second RFA. The rupture of the BTT via the anterior thyroid capsule was detected on postcontrast CT and sonography. Her symptoms improved for 1 week with IV antibiotics. However, she revisited with relapse of her symptoms. She was finally treated with incision and drainage.

Discussion

Treatment by using RFA has been broadened from the liver to various organs.⁵⁻¹⁶ Complications related to RFA treatment have also been reported; these reports have been mainly about patients with liver disease^{4,19} and rarely in lung RFAs.¹³ However, tumor rupture after RFA treatment is very rare, even in liver tumors. The current study is the first report in the English literature of a tumor rupture after RFA of benign thyroid nodules.^{4,19} Hepatoma rupture may occur immediately or a few hours after an RFA treatment, and it may present as an intra-peritoneal hemorrhage, which is diagnosable by using sonography and/or CT. The clinical presentation in our patients with thyroid tumor rupture after RFA included sudden neck bulging and pain at the RFA site, which developed between 9

Clinical and imaging findings and management in 6 patients with tumor rupture after RFA

No.	Sex	Age (yr)	Initial Tumor Site	Size (mm)	No. of RFAs	RF AT (min)/Max Power (W)	Rupture from Last RFA (day)	Aspiration after Rupture	Initial Treatment	Final Treatment, Follow-Up	Sonographic Mass Composition
1	M	28	Left anterior	23 × 37 × 46	2	25/80 (1st)/20/80 (2nd)	50	No	Observation	Observation	Mixed echoic, >50% cystic
2	F	29	Left anterior	11 × 16 × 23	3	20/70 (1st)/14/80 (2nd)/6/50 (3rd)	60	No	Observation	Observation	Mixed echoic, >50% cystic
3	M	60	Right anterior	24 × 23 × 35	2	20/70 (1st)/21/90 (2nd)	30	Yes	IV antibiotics	IV antibiotics	Mixed echoic, >50% solid
4	M	53	Left anterior	51 × 29 × 50	1	40/80	22	Yes	No treatment	Incision and drainage	Mixed echoic, >50% cystic
5	M	36	Right anterior	49 × 35 × 64	1	35/130	60	Yes	Oral antibiotics	Unilateral lobectomy	Mixed echoic, spongiform
6	F	52	Left anterior	25 × 15 × 32	2	22/80 (1st)/20/100 (2nd)	9	No	IV antibiotics	Incision and drainage	Solid

Note:—Max indicates maximum.

and 60 days after their last RFA. Sonography and CT confirmed a rupture of the tumor into the anterior neck muscle and/or soft tissue.

The clinical and imaging characteristics of ruptured BTT in this study were an anterior location without surrounding parenchyma, mixed composition of nodules, large size, repeated ablation, higher maximum power, and longer AT (Table). In all the patients examined in this study, the rupture occurred at the anterior wall of the thyroid gland and erupted into the anterior neck space from the naked wall. In all patients, there was no normal thyroid tissue between the thyroid tumor and thyroid capsules. Thyroid glands are surrounded by the spine posteriorly, the trachea medially, and the carotid space laterally. Strap muscles and sternocleidomastoid muscles surrounding the anterior surface of the thyroid may not be as tight as on the other side. As a result, a rupture might occur in the anterior wall of the thyroid. Superficial locations of the tumor and protruding liver capsules are also risk factors for liver tumor rupture after RFA.⁴ As opposed to pure solid nodules, mixed cystic and solid nodules can retard heat conduction and increase tumor tolerance to heat due to greater heterogeneity of tissue composition.⁹ Therefore, mixed cystic and solid nodules may tend to have a higher maximum power and a longer RFA duration, which increases the overall deposition of energy. Large tumors and multiple ablations might also increase the heat applied to a single nodule.

One mechanism of thyroid nodule rupture after RFA may be delayed bleeding because high attenuation on CT or hyperechogenicity on sonography with volume expansion was newly detected in thyroid tumors after RFA, which was the cause of the tumor rupture development (Fig 2). Bleeding may result from the following causes: microvessel leakage within the tumor leading to delayed volume expansion and rupture, tearing of the tumor wall and thyroid capsule at a weak point, or postprocedural massaging or moving of the neck. Hepatoma ruptures related to RFA treatment are usually due to serious cough or strong hiccups.⁴

There have been no established management methods for the rupture of benign thyroid nodules after RFA. We suggest conservative treatment with no additional invasive procedures

(such as puncture aspiration) for a number of reasons: First, no bacterial growth resulted in the 3 patients after we performed puncture aspiration. Second, delayed hemorrhage may be its cause. Third, 2 cases without puncture aspiration completely regressed with conservative management only. However, surgical treatment may be needed in cases in which symptoms progress. With larger nodules initially >5 cm, we found that spontaneous regression did not occur with conservative observation.

In conclusion, the rupture of BTT after RFA might occur due to volume expansion by a delayed hemorrhage or tumor wall tear. If patients with BTT have abrupt neck swelling and pain after RFA, tumor rupture can be considered. We recommend an initial conservative treatment without invasive procedures, such as a needle aspiration. However, surgical management, such as a drainage or excision, may be required if symptoms with redness and pain progress.

References

- Baek JH, Kim YS, Lee D, et al. Benign predominantly solid thyroid nodules: prospective study of efficacy of sonographically guided radiofrequency ablation versus control condition. *AJR Am J Roentgenol* 2010;194:1137–42
- Kim YS, Rhim H, Tae K, et al. Radiofrequency ablation of benign cold thyroid nodules: initial clinical experience. *Thyroid* 2006;16:361–67
- Livraghi T, Goldberg SN, Lazzaroni S, et al. Small hepatocellular carcinoma: treatment with radio-frequency ablation versus ethanol injection. *Radiology* 1999;210:655–61
- Livraghi T, Solbiati L, Meloni MF, et al. Treatment of focal liver tumors with percutaneous radio-frequency ablation: complications encountered in a multicenter study. *Radiology* 2003;226:441–51
- Dodd GD 3rd, Soulen MC, Kane RA, et al. Minimally invasive treatment of malignant hepatic tumors: at the threshold of a major breakthrough. *Radiographics* 2000;20:9–27
- Gazelle GS, Goldberg SN, Solbiati L, et al. Tumor ablation with radio-frequency energy. *Radiology* 2000;217:633–46
- Livraghi T, Goldberg SN, Lazzaroni S, et al. Hepatocellular carcinoma: radio-frequency ablation of medium and large lesions. *Radiology* 2000;214:761–68
- McGhana JP, Dodd GD 3rd. Radiofrequency ablation of the liver: current status. *AJR Am J Roentgenol* 2001;176:3–16
- Rhim H, Goldberg SN, Dodd GD 3rd, et al. Essential techniques for successful radio-frequency thermal ablation of malignant hepatic tumors. *Radiographics* 2001;21(spec no):S17–35, discussion S36–39
- Solbiati L, Goldberg SN, Ierace T, et al. Hepatic metastases: percutaneous radio-frequency ablation with cooled-tip electrodes. *Radiology* 1997;205:367–73
- Solbiati L, Ierace T, Goldberg SN, et al. Percutaneous US-guided radio-fre-

- quency tissue ablation of liver metastases: treatment and follow-up in 16 patients. *Radiology* 1997;202:195–203
12. Lencioni R, Cioni D, Bartolozzi C. Percutaneous radiofrequency thermal ablation of liver malignancies: techniques, indications, imaging findings, and clinical results. *Abdom Imaging* 2001;26:345–60
 13. Nomura M, Yamakado K, Nomoto Y, et al. Complications after lung radiofrequency ablation: risk factors for lung inflammation. *Br J Radiol* 2008;81:244–49
 14. Pavlovich CP, Walther MM, Choyke PL, et al. Percutaneous radio frequency ablation of small renal tumors: initial results. *J Urol* 2002;167:10–15
 15. Woertler K, Vestring T, Boettner F, et al. Osteoid osteoma: CT-guided percutaneous radiofrequency ablation and follow-up in 47 patients. *J Vasc Interv Radiol* 2001;12:717–22
 16. Dupuy DE, Hong R, Oliver B, et al. Radiofrequency ablation of spinal tumors: temperature distribution in the spinal canal. *AJR Am J Roentgenol* 2000;175:1263–66
 17. Jeong WK, Baek JH, Rhim H, et al. Radiofrequency ablation of benign thyroid nodules: safety and imaging follow-up in 236 patients. *Eur Radiol* 2008;18:1244–50
 18. Baek JH, Moon WJ, Kim YS, et al. Radiofrequency ablation for the treatment of autonomously functioning thyroid nodules. *World J Surg* 2009;33:1971–77
 19. Chen MH, Dai Y, Yan K, et al. Intraperitoneal hemorrhage during and after percutaneous radiofrequency ablation of hepatic tumors: reasons and management. *Chin Med J (Engl)* 2005;118:1682–87