

**ORIGINAL
RESEARCH**

J.-F. Vendrell
V. Costalat
H. Brunel
C. Riquelme
A. Bonafe



EDITOR'S
CHOICES



Stent-Assisted Coiling of Complex Middle Cerebral Artery Aneurysms: Initial and Midterm Results

BACKGROUND AND PURPOSE: Clinical outcome and initial and midterm angiographic results of EVT of complex MCA aneurysms by using the stent-assisted coiling technique were retrospectively evaluated in our center where EVT of intracranial aneurysms is the first treatment option.

MATERIALS AND METHODS: From November 2003 to October 2009, 49 patients (27 men, 22 women; mean age, 52 ± 12 years) harboring 52 complex unruptured MCA aneurysms (11 ruptured previously and coiled but recanalized and 41 unruptured) were treated by EVT by using self-expandable intracranial stents. Procedural complications, clinical outcome, and initial and midterm angiographic results were evaluated. Initial treatment status and aneurysm sac size were tested as potential risk factors for recurrence.

RESULTS: After successful stent deployment, coiling was performed in 50 aneurysms (96.2%) in 47 patients; however, 2 failures (3.8%) occurred in 2 patients. Ten intrastent clot formations (20%) observed on final control angiography induced 2 permanent moderate disabilities (GOS score = 2). Mortality and permanent neurologic morbidity were 0% and 4.3%, respectively. At a mean period of 14 ± 9 months, among 48 aneurysms in 45 patients eligible for follow-up, 34 complete (71%) and 14 partial treatments (29%) were observed, 7 recurrences (14.6%) occurred, and 5 patients (10.4%) needed retreatment. No aneurysm bleeding or symptomatic intrastent stenosis was observed. Aneurysm sac size ≥ 7 mm and incomplete initial treatment were associated with more recurrences without a statistically significant difference.

CONCLUSIONS: For complex unruptured MCA aneurysms, EVT by using a self-expandable intracranial stent was feasible, safe, and durable and could be considered as the first-option treatment.

ABBREVIATIONS: DSA = digital subtraction angiography; EVT = endovascular treatment; GOS = Glasgow Outcome Scale; MCA = middle cerebral artery; MRA = MR angiography; SAH = subarachnoid hemorrhage

Since the International Subarachnoid Aneurysm Trial, EVT of intracranial aneurysms has become a valid therapeutic alternative to neurosurgery and is now performed as the first option in many centers around the world,^{1,2} except in the MCA. This aneurysm location presents a favorable superficial anatomy for neurosurgical treatment, while EVT is often unfavorable because of complex vascular anatomy, inducing a high rate of procedure failures, clinical complications, and aneurysm recurrences.³ Consequently, the optimal therapeutic management of MCA aneurysms is still considered controversial, and surgical clipping remains the standard treatment in many institutions.⁴⁻⁷ Although MCA aneurysms were underrepresented in large EVT series,^{2,8,9} low morbidity-mortality and aneurysm-recurrence rates have recently been reported in MCA aneurysm series, underlining the potential for EVT.¹⁰⁻¹² Furthermore, self-expandable intracranial stents became available in 2003 and have been reported as safe and effective, particularly in the treatment of complex aneurysms,¹³⁻¹⁹ but without consistent data in the MCA location.

Received April 14, 2010; accepted after revision June 25.

From the Department of Neuroradiology, University Hospital Center, Gui de Chauviac Hospital, Montpellier, France.

Please address correspondence to Alain Bonafe, MD, Interventional Neuroradiology Department, University Hospital Center, Gui de Chauviac Hospital, 80 Avenue Augustin Fliche, 34295 Montpellier Cedex 5, France; e-mail: a-bonafe@chu-montpellier.fr

Indicates article with supplemental on-line tables.

DOI 10.3174/ajnr.A2272

The aim of this study was to retrospectively evaluate the clinical outcome and initial and midterm angiographic results of EVT of MCA aneurysms by using the stent-assisted coiling technique.

Materials and Methods

Patients and Aneurysms

The institutional review board of the University Hospital Center of Montpellier approved this retrospective study, and written informed consent was obtained from each patient. Patients harboring at least 1 unruptured complex MCA aneurysm or 1 ruptured and previously coiled but recanalized aneurysm underwent EVT with a self-expandable intracranial stent. Aneurysm inclusion criteria were the following: 1) aneurysm sac size ≥ 7 mm, or 2) aneurysm < 7 mm, with 1 of the following conditions: symptomatic patient, personal history of SAH from another intracranial aneurysm, familial history of SAH, or recanalization of a treated aneurysm. From November 2003 to October 2009, EVT by using the stent-assisted coiling technique was attempted on 49 patients harboring 52 complex MCA aneurysms (On-line Table 1). Thirty-six of 52 (69%) were incidental aneurysms that had never been treated, and 16 (31%) were recanalized aneurysms previously coiled by using the remodeling technique (5 unruptured [10%] and 11 ruptured [21%]). Forty-six of 49 patients had only 1 MCA aneurysm, and the 3 others had 2. Patient characteristics (number, mean age, and sex ratio) and aneurysm characteristics (number, sac, and neck size) were prospectively recorded and analyzed by members of our neurointerventional team.

Complex MCA aneurysms were defined by a particular anatomy including the following: 1) a branch vessel arising from the aneurysm sac, 2) a wide-neck aneurysm with parent vessel incorporation, 3) an MCA trifurcation, 4) a parent vessel stenosis, and 5) a sac-to-neck ratio of <2 .^{3,7,10,20,21} Initial treatment and aneurysm sac size were tested as potential factors for recurrence.^{2,8,22-26} With this possibility in mind, we classified aneurysm sac sizes into 3 groups: 1) small, <7 mm; 2) medium, 7–12 mm; and 3) large, >12 mm (On-line Table 1).^{10,27} Initial treatment status was classified as complete or incomplete (residual neck or residual aneurysm).

Aneurysm Treatment

All procedures were performed using a biplane angiographic system (Neurostar T.O.P.; Siemens, Erlangen, Germany), with the patient under general anesthesia and also receiving systemic heparinization for 24 hours. On the day before EVT, patients were premedicated with a loading dose of clopidogrel (300 mg, Plavix; Bristol-Myers Squibb, New York). At the end of the procedure, aspirin (250 mg) was administered to the patient by an intravenous route. Patients were then kept under dual antiplatelet therapy daily for 2 months (clopidogrel, 75 mg, and aspirin, 325 mg) followed by clopidogrel daily alone for 4 months. Since September 2006, platelet aggregation inhibition has been tested just before the beginning of the procedure with the VerifyNow P12Y12 assay (Accumetrics, San Diego, California), and in cases of low efficacy ($<40\%$ platelet-aggregation inhibition), aspirin (250 mg) was given to the patient during the procedure and a re-loading dose of clopidogrel (300 mg) was promptly administered at the end of EVT. All aneurysms were treated by using only 1 self-expandable intracranial stent (Neuroform stent, Boston Scientific, Natick, Massachusetts; or Enterprise self-expanding stent, Cordis, Miami Lakes, Florida) placed into the parent vessel, bridging the aneurysm neck.

Stent placement was performed either before coiling (taking advantage of the open cell design of Neuroform stents) or with the jailing technique (with Neuroform or Enterprise stents) when the size of the artery allowed safe navigation of 2 simultaneous microcatheters. In selected cases, the stent was deployed after coiling at the end of the procedure with the aim of securing the parent artery. Coiling was performed by using Matrix coils (Boston Scientific), Guglielmi detachable coils (Boston Scientific), HydroCoils (MicroVention, Aliso Viejo, California), or a combination. In the event of a periprocedural thromboembolic complication, abciximab (ReoPro) was administered intravenously as a single dose (0.25 mg/kg) followed by a 12-hour drip (0.125 $\mu\text{g}/\text{kg}/\text{mn}$).

Patient Follow-Up

The clinical outcome of patients was evaluated during the following hospitalization period and then was re-evaluated at the first angiographic control, generally performed at 6 months by MRA. Additional controls either by MRA or DSA were then scheduled as follows: 18 months (DSA) and 3 years and 5 years (MRA). In our institution, the MRA sequences (time-of-flight) were analyzed by using mainly source images^{10,28}; maximum-intensity-projection images were irrelevant due to major artifacts caused by the stents. In cases of unreliable MR imaging findings, DSA was promptly performed. One member of our neurointerventional team prospectively recorded angiographic results and GOS scores at discharge and then at each follow-up visit. Thus, morbidity-mortality rates and angiographic results were retrospectively analyzed at initial and midterm follow-ups. Using the Raymond classification scale²⁹ for comparison of initial and midterm

angiographic results, we defined a 3-level assessment profile grading scale, given the evolution of treatment¹⁰: 1) a favorable result with progression of thrombosis (aneurysms switching from class 3 to class 1 or from class 2 to class 1), 2) a stable result demonstrating no change from the initial result, or 3) an unfavorable result demonstrating any worsening from the initial result. Unfavorable results were further classified as minor or major recurrences as follows: Aneurysms switching from class 1 to class 3 or from class 2 to class 3 were considered major recurrences requiring retreatment, and aneurysms switching from class 1 to class 2 were considered minor recurrences requiring only additional angiographic controls. Two patients were not followed because of death from cervical neoplasia in 1 patient and loss to follow-up in another.

Statistical Analysis

Patient and aneurysm data, as well as angiographic results, were prospectively recorded in a maintained data base and then were retrospectively analyzed. Midterm angiographic results were defined comparing initial and late results and then were classified by using a 3-level assessment-profile grading scale based on the Raymond classification scale. Initial treatment status and aneurysm sac size were tested as potential risk factors for recurrence by using the Fisher exact test. A P value $<.05$ was considered a significant difference.

Results

Patient and Aneurysm Characteristics

A total of 49 patients having 52 MCA aneurysms were eligible for EVT by using the stent-assisted coiling technique (On-line Table 1). Fifty (96.2%) were successfully treated, whereas 2 procedure failures (3.8%) due to an inability to catheterize the parent vessel branch occurred and were referred to the neurosurgical team. Twenty-seven aneurysms (52%) with a sac size <7 mm underwent EVT because of a personal history of SAH from another intracranial aneurysm ($n = 10$, 19%), familial history of SAH ($n = 4$, 8%), symptomatic aneurysms ($n = 2$, 4%), or aneurysm recurrence after coiling alone with or without using the remodeling technique ($n = 11$, 21%). Only 1 self-expandable intracranial stent was deployed for the treatment of each aneurysm (32 Neuroform and 18 Enterprise stents). Intracranial stent placement was performed before coiling in 47 cases. In 29 of these, the aneurysm was coiled through the struts of the stent (25 Neuroform and 4 Enterprise stents), and in 18, by using the jailing technique (5 Neuroform and 13 Enterprise stents). The stent was deployed after coiling in 3 cases (6%). In these 3 cases, temporary balloon occlusion of the parent vessel was used for coiling and a stent was placed in the parent artery because of instability of the coil packing. According to the definition for complex MCA aneurysm anatomy ("Materials and Methods" section), among the 52 included aneurysms, 37 (71%) were wide-neck aneurysms with parent vessel incorporation and a sac-to-neck ratio of <2 ; seven (13%) were wide-neck with parent vessel incorporation; 5 (10%) had a sac-to-neck ratio of <2 ; one (2%) arose from an MCA trifurcation; 1 (2%) presented with parent vessel stenosis; and 1 (2%), with a branch vessel arising from the aneurysmal sac.

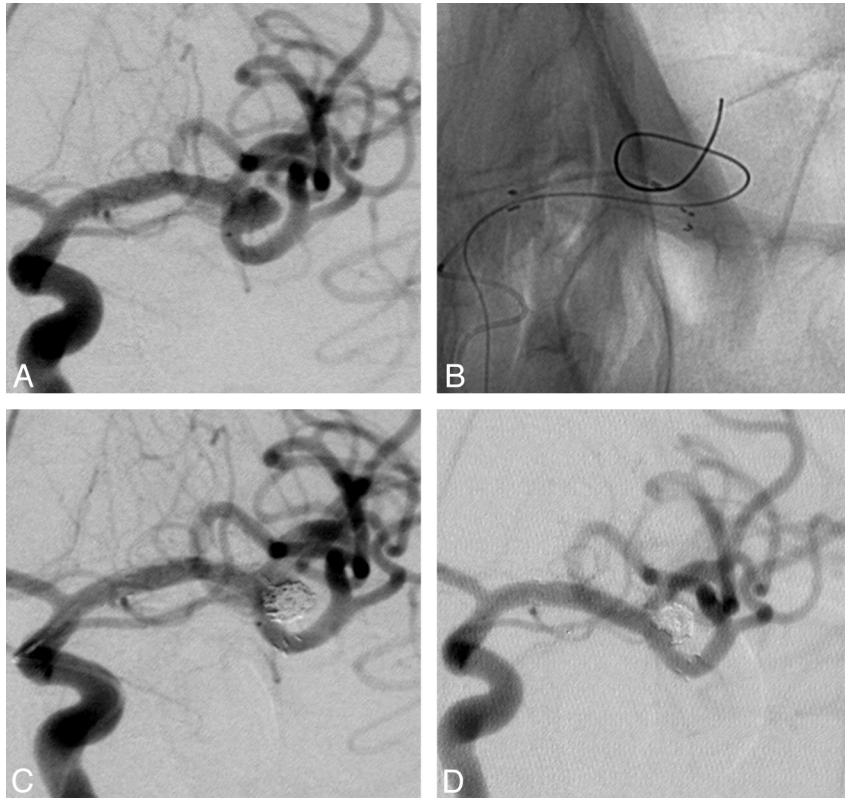


Fig 1. A, Angiogram of the left internal carotid artery shows an unruptured MCA aneurysm of the bifurcation fortuitously discovered in a 50-year-old woman. Sac and neck sizes were 7 and 5 mm, respectively. B, A self-expandable stent (Neuroform) was previously deployed before coiling through the mesh of the stent. C and D, A complete occlusion (considered as class 1) is observed on final angiographic control (C) and at 18 months (D).

Complications and Clinical Outcome

On final angiographic control in the acute phase, 10 intrastent clot formations occurred in 50 procedures (20%). Even though abciximab was promptly administered in each case, 4 symptomatic patients (8.5%) were recorded and classified as having minor stroke (GOS < 3). At 6-month follow-up, 43 of 45 patients (95.6%) were treated without clinical complication (GOS = 1), 2 had recovered (GOS = 1), and 2 others presented with minor disabilities (GOS = 2) (On-line Table 2). At midterm, mortality and permanent neurologic morbidity were 0% and 4.3%, respectively. No aneurysm perforation or aneurysm bleeding was observed.

Angiographic Results at Midterm

Among 47 patients, 45 with 48 treated MCA aneurysms were eligible for follow-up by using either MRA ($n = 20$, 42%) or DSA ($n = 28$, 58%) at a mean period of 14 ± 9 months. More than half of the patients (28/45) had an angiographic control at >12 months. A blurring effect of the stent disturbed MRA interpretation in 3 cases for which DSA was promptly performed. At midterm, 34 complete treatments (71%), 8 residual aneurysms (17%), and 6 residual necks (12%) were observed. Finally, when we compared initial and midterm results, 20 of 48 angiographic results remained stable (as shown in 2 representative cases illustrated in Figs 1 and 2), 21 showed improvement due to a progressive thrombosis, and 7 showed recanalization (14.6%) (Table 1). Two patients presented with an asymptomatic intrastent stenosis.

Recurrence Analysis

Forty-one of 48 aneurysms (85%) were successfully treated at midterm follow-up. Among the 7 recanalized aneurysms, 5 were considered major recurrences (10.4%) and were re-treated. Six of these 7 aneurysms had an initial suboptimal coil packing ($P = .4$), 4 medium-sized and 3 small-sized aneurysms ($P = .57$) (Table 2). None of the results were statistically significant.

Discussion

EVT of MCA aneurysms remains controversial in many centers around the world⁴⁻⁶ because of favorable surgical results with low morbidity-mortality and recurrence rates at follow-up. However, low morbidity-mortality (5.4%–12.4%) and aneurysm-recurrence rates (9.5%–10.5%) were observed at mid- and long-term in recent EVT series by using a simple coiling or balloon-remodeling technique.^{10-12,21,30} In our institution, 1492 aneurysms were treated by EVT, including 234 MCA aneurysms (15.7%) with a high proportion of complex anatomy cases. From our previous experience, we considered that the complex anatomy of MCA aneurysms remains a challenge in EVT, and we hypothesized that the improvement of embolization techniques such as stent-assisted coiling could enhance feasibility, safety, and efficacy of EVT of MCA aneurysms.¹⁰ Thus, this study provided clinical, angiographic, and technical results in patients having complex unruptured MCA aneurysms treated by using a self-expandable intracranial stent.

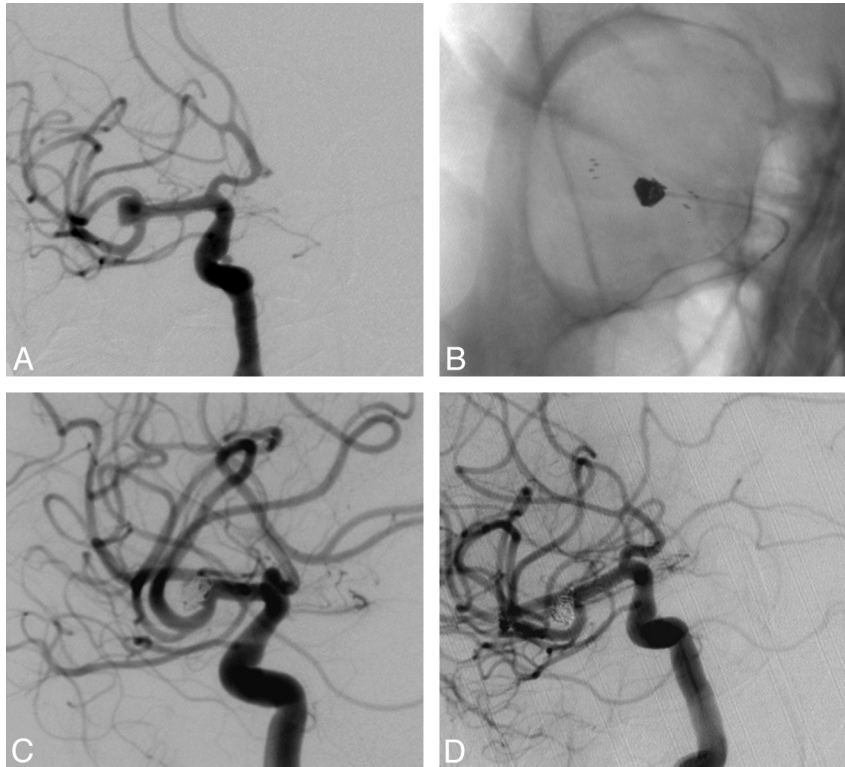


Fig 2. A, Angiogram of the right internal carotid artery shows an unruptured MCA aneurysm of the bifurcation fortuitously discovered in a 47-year-old woman. B, Intracranial stent placement (Enterprise) was performed before coiling through the mesh of the stent. C and D, A complete occlusion (considered as class 1) is observed on final angiographic control and at 14 months.

Table 1: Angiographic evolution at midterm follow-up^a

	Initial (n = 50)	Midterm (n = 48)
Complete treatment (class 1) ^b	18 (36)	34 (71)
Residual neck (class 2)	14 (28)	6 (12)
Residual aneurysm (class 3)	18 (36)	8 (17)
Recurrence		7 (14)

^a Numbers in parentheses represent percentages.

^b Raymond classification.²⁹

Table 2: Aneurysm recurrence analysis at midterm^a

Characteristic	No Recurrence (n = 41)	Recurrence (n = 7)	P Value
Aneurysm sac-size			
<7 mm	23 (48)	3 (6)	Not significant
≥7 mm	18 (38)	4 (8)	
Initial treatment status			
Complete	15 (32)	1 (2)	Not significant
Incomplete	26 (54)	6 (12)	

^a Numbers in parentheses represent percentages.

Overall, despite the antiplatelet therapy given to the patient and the test of clopidogrel resistance before the procedure, a high rate of intrastent clot formation was observed, but morbidity-mortality rates remained low as a result of prompt abciximab administration and included only 2 moderate permanent disabilities. Morbidity-mortality rates were in accordance with previous results of an unruptured MCA aneurysm series, using coiling with or without a remodeling technique, which ranged from 2.2% to 9.8%.^{10-12,31} In addition, the complex MCA aneurysm recurrence rate observed at midterm in our series (14.6%) was lower compared with that in other

MCA aneurysm series (20%–27%)^{10,11} or with that in series including all aneurysm locations (15%–33%),^{8,22,32,33} while rates of major recurrences (10.4%) needing retreatment were similar (5%–17%) to the rates in our series.^{10-12,23,32,33} Our results clearly indicate that complex unruptured MCA aneurysms can benefit from stent-assisted coiling in terms of feasibility, safety, and midterm anatomic reconstruction. Stent-assisted coiling could be applied to a larger range of MCA aneurysms with a simple coiling or remodeling technique. A sac-to-neck ratio of <2 has been challenged by Brinjikji et al,³⁴ even if it remains popular among neurointerventional teams. However, their series did not include MCA aneurysms, which often present with a wide neck and parent vessel incorporation. Also, that series did not take into account the mid- and long-term recurrence risk associated with a simple coiling or remodeling technique.

In cases of aneurysmal regrowth, stent placement combined with concomitant double antiplatelet therapy and subsequent coiling may improve mid- and long-term angiographic and clinical results. In our study, rates of procedural adverse events and complications were not enhanced following stent deployment; they were either similar to those reported or even lower, due to standardized antiplatelet therapy.^{13-18,35,36} As described, stent placement before coiling was predominantly used in our series^{17,19,37-40} without inducing high complication rates,¹⁵ but technical difficulties in reaching the aneurysm pouch through the struts of the stent accounted for poor initial anatomic results. However, midterm stable or favorable anatomic results stressed that a high rate of complete occlusion was observed regardless of the aneurysm and neck sizes and could be related to the stent arterial-flow diversion

and neointimal growth along scaffolding arterial wall reconstruction. In our series, aneurysm size and initial treatment status were not relevant predictors of recurrence.

In this study, we used mostly Neuroform stents because they were available 2 years before Enterprise stents (2003). In this example, because of the difference in terms of mean follow-up, the comparison between the 2 types of stents was irrelevant. Another limitation of the study was the absence of comparison between our results from the stent-assisted coiling technique and those from neurosurgical clipping, due to a lack of surgical reports concerning the MCA aneurysm topography.

Conclusions

Regardless of the complexity of MCA aneurysms, our results confirm the safety, efficacy, and particularly the feasibility of the stent-assisted coiling technique in most cases. EVT of complex unruptured MCA aneurysms could be considered as the treatment of choice.

Acknowledgments

We thank Gregoire Mercier, MD, for his assistance in the statistical analysis.

References

1. Molyneux A, Kerr R, Stratton I, et al, for the International Subarachnoid Aneurysm Trial (ISAT) Collaborative Group. **International Subarachnoid Aneurysm Trial (ISAT) of neurosurgical clipping versus endovascular coiling in 2143 patients with ruptured intracranial aneurysms: a randomised trial.** *Lancet* 2002;360:1267–74
2. Molyneux AJ, Kerr RS, Yu LM, et al. **International Subarachnoid Aneurysm Trial (ISAT) of neurosurgical clipping versus endovascular coiling in 2143 patients with ruptured intracranial aneurysms: a randomized comparison of effects on survival, dependency, seizures, rebleeding, subgroups, and aneurysm occlusion.** *Lancet* 2005;366:809–17
3. Dashti R, Rinne J, Hernesniemi J, et al. **Microneurosurgical management of proximal middle cerebral artery aneurysms.** *Surg Neurol* 2007;67:6–14
4. Heros RC, Fritsch MJ. **Surgical management of middle cerebral artery aneurysms.** *Neurosurgery* 2001;48:780–86
5. Doerfler A, Wanke I, Goericke SL, et al. **Endovascular treatment of middle cerebral artery aneurysms with electrolytically detachable coils.** *AJNR Am J Neuroradiol* 2006;27:513–20
6. Regli L, Dehdashti AR, Uske A, et al. **Endovascular coiling compared with surgical clipping for the treatment of unruptured middle cerebral artery aneurysms: an update.** *Acta Neurochir Suppl* 2002;82:41–46
7. Stoodley MA, Macdonald RI, Weir BK. **Surgical treatment of middle cerebral artery aneurysms.** *Neurosurg Clin N Am* 1998;9:823–34
8. Raymond J, Guilbert F, Weill A, et al. **Long-term angiographic recurrences after selective endovascular treatment of aneurysms with detachable coils.** *Stroke* 2003;34:1398–403
9. CARAT Investigators. **Rates of delayed rebleeding from intracranial aneurysms are low after surgical and endovascular treatment.** *Stroke* 2006;37:1437–42. Epub 2006 Apr 20
10. Vendrell JF, Menjot N, Costalat V, et al. **Endovascular treatment of 174 middle cerebral artery aneurysms: clinical outcome and radiological results at long-term follow-up.** *Radiology* 2009;253:1–8
11. Iijima A, Piotin M, Mounayer C, et al. **Endovascular treatment with coils of 149 middle cerebral artery berry aneurysms.** *Radiology* 2005;237:611–19
12. Suzuki S, Tateshima S, Jahan R, et al. **Endovascular treatment of middle cerebral artery aneurysms with detachable coils: angiographic and clinical outcomes in 115 consecutive patients.** *Neurosurgery* 2009;64:876–78
13. Sedat J, Chau Y, Mondot L, et al. **Endovascular occlusion of intracranial wide-necked aneurysms with stenting (Neuroform) and coiling: mid-term and long-term results.** *Neuroradiology* 2009;51:401–09
14. Liang G, Gao X, Li Z, et al. **Neuroform stent-assisted coiling of intracranial aneurysms: a 5 year single-center experience and follow-up.** *Neurol Res* 2010; 32:721–27
15. Biondi A, Vallabh J, Jeffrey MK, et al. **Neuroform stent-assisted coil embolization of wide-neck intracranial aneurysms: strategies in stent deployment and midterm follow-up.** *Neurosurgery* 2007;61:460–68
16. Mocco J, Snyder KV, Albuquerque FC, et al. **Treatment of intracranial aneurysms with the Enterprise stent: a multicenter registry.** *J Neurosurg* 2009;110:35–39
17. Akpek S, Arat A, Morsi H, et al. **Self-expandable stent-assisted coiling of wide-neck intracranial aneurysms: a single-center experience.** *AJNR Am J Neuroradiol* 2005;26:1223–31
18. Katz JM, Tsiouris AJ, Biondi A, et al. **Advances in endovascular aneurysm treatment: are we making a difference?** *Neuroradiology* 2005;47:695–701
19. Lee YJ, Kim DJ, Suh SH, et al. **Stent-assisted coil embolization of intracranial wide-necked aneurysms.** *Neuroradiology* 2005;7:680–89
20. Horowitz M, Gupta R, Gologorsky Y, et al. **Clinical and anatomic outcomes after endovascular coiling of middle cerebral artery aneurysms: report on 30 treated aneurysms and review of the literature.** *Surg Neurol* 2006;66:167–71
21. Quadros RS, Gallas S, Noudel R, et al. **Endovascular treatment of middle cerebral artery aneurysms as first option: a single-center experience of 92 aneurysms.** *AJNR Am J Neuroradiol* 2007;28:1567–72
22. Cognard C, Weill A, Spelle L, et al. **Long-term angiographic follow-up of 169 intracranial berry aneurysms occluded with detachable coils.** *Radiology* 1999;212:348–56
23. Campi A, Ramzi N, Molyneux AJ, et al. **Retreatment of ruptured cerebral aneurysms in patients randomized by coiling or clipping in the International Subarachnoid Aneurysm Trial (ISAT).** *Stroke* 2007;38:1538–44
24. Fernandez Zubillaga A, Guglielmi G, Vinuela F, et al. **Endovascular occlusion of intracranial aneurysms with electrically detachable coils: correlation of aneurysm neck size and treatment results.** *AJNR Am J Neuroradiol* 1994;15:815–20
25. Murayama Y, Nien YL, Duckwiler G, et al. **Guglielmi detachable coil embolization of cerebral aneurysms: 11 years' experience.** *J Neurosurg* 2003;98: 959–66
26. Tamatani S, Ito Y, Abe H, et al. **Evaluation of the stability of aneurysms after embolization using detachable coils: correlation between stability of aneurysms and embolized volume of aneurysms.** *AJNR Am J Neuroradiol* 2002;23:762–67
27. Wiebers DO, Whisnant JP, Huston J 3rd, et al. **Unruptured intracranial aneurysms: natural history, clinical outcome, and risks of surgical and endovascular treatment.** *Lancet* 2003;362:103–10
28. Costalat V, Lebars E, Sarry L, et al. **In vitro evaluation of 2D-digital subtraction angiography versus 3D-time-of-flight in assessment of intracranial cerebral aneurysm filling after endovascular therapy.** *AJNR Am J Neuroradiol* 2006;27: 177–84
29. Roy D, Milot G, Raymond J. **Endovascular treatment of unruptured aneurysms.** *Stroke* 2001;32:1998–2004
30. Oishi H, Yoshida K, Shimizu T, et al. **Endovascular treatment with bare platinum coils for middle cerebral artery aneurysms.** *Neurol Med Chir (Tokyo)* 2009;49:287–93
31. Vanzin JR, Mounayer C, Piotin M, et al. **Endovascular treatment of unruptured middle cerebral artery aneurysms [in French].** *J Neuroradiol* 2005;32:97–108
32. Gallas S, Pasco A, Cottier JP, et al. **A multicenter study of 705 ruptured intracranial aneurysms treated with Guglielmi detachable coils.** *AJNR Am J Neuroradiol* 2005;26:1723–31
33. Gallas S, Januel AC, Pasco A, et al. **Long-term follow-up of 1036 cerebral aneurysms treated by bare coils: a multicentric cohort treated between 1998 and 2003.** *AJNR Am J Neuroradiol* 2009;30:1986–92
34. Brinjikji W, Cloft H, Kallmes DF, et al. **Difficult aneurysms for endovascular treatment: overdue or undertall.** *AJNR Am J Neuroradiol* 2009;30:1513–17
35. dos Santos Souza MP, Agid R, Willinsky RA, et al. **Microstent-assisted coiling for wide-necked intracranial aneurysms.** *Can J Neurol Sci* 2005;32:71–81
36. Piotin M, Blanc R, Spelle L, et al. **Stent-assisted coiling of intracranial aneurysms: clinical and angiographic results in 216 consecutive aneurysms.** *Stroke* 2010;41:110–15
37. Alfke K, Straube T, Dornier L, et al. **Treatment of intracranial broad-neck aneurysms with a new self-expanding stent and coil embolization.** *AJNR Am J Neuroradiol* 2004;25:584–91
38. Benitez RP, Silva MT, Klem J, et al. **Endovascular occlusion of wide-necked aneurysms with a new intracranial microstent (Neuroform) and detachable coils.** *Neurosurgery* 2004;54:1359–68
39. Fiorella D, Albuquerque FC, Deshmukh VR, et al. **Usefulness of the Neuroform stent for the treatment of cerebral aneurysms: results at initial (3–6-mo) follow-up.** *Neurosurgery* 2005;56:1191–202
40. Wanke I, Doerfler A, Schoch B, et al. **Treatment of wide-neck intracranial aneurysms with a self-expanding stent system: initial clinical experience.** *AJNR Am J Neuroradiol* 2003;24:1192–99