

Are your **MRI contrast agents** cost-effective?

Learn more about generic **Gadolinium-Based Contrast Agents**.



**FRESENIUS
KABI**

caring for life

AJNR

Anomalous Extraocular Muscles with Strabismus

M.D. Dobbs, L.A. Mawn and S.P. Donahue

AJNR Am J Neuroradiol 2011, 32 (9) E167-E168

doi: <https://doi.org/10.3174/ajnr.A2291>

<http://www.ajnr.org/content/32/9/E167>

This information is current as
of April 20, 2024.

CASE REPORT

M.D. Dobbs
L.A. Mawn
S.P. Donahue

Anomalous Extraocular Muscles with Strabismus

SUMMARY: An 8-month-old boy with Gorlin syndrome presented with a large right-face turn and constant exotropia of the left eye. Eight-millimeter recession of the left lateral rectus muscle was performed at 23 months of age without complete postoperative improvement. Orbital imaging revealed bilateral anomalous extraocular muscles inferolateral to the optic nerves. Surgical resection of the tissue confirmed the accessory musculature with postoperative correction of the strabismus. To our knowledge, this appears to be the first reported case in the radiologic literature.

An 8-month-old boy with a history of Gorlin syndrome (basal cell nevus syndrome) presented to pediatric ophthalmology with a large right-face turn (to compensate for left eye deviation). He was observed for nearly a year without change in his ocular mobility and was thought to have type II Duane syndrome. He underwent a large left lateral rectus recession at 23 months of age, which produced a moderate improvement in adduction and the face turn. The movements of the right eye were normal. However, as he became older, a limitation of elevation of the left eye with marked globe retraction became clearly evident, which prompted imaging to assess for any congenital accessory orbital structures. An orbital CT was performed.

Case Report

Orbital unenhanced CT revealed bilateral anomalous tissue within the intraconal regions inferolateral to the optic nerves, medial to the lateral rectus, and superior to the inferior rectus muscles, larger on the left side (Figs 1 and 2). This tissue had CT attenuation similar to that of muscle and had the visual appearance of a taut muscular structure. The tissue extended from the posterior orbital apex near the annulus of Zinn and inserted directly on the posterior globe. This tissue did not insert or originate from any of the surrounding normal extraocular muscles. All of the remaining extraocular muscles were present with normal size and location, with no other intraconal or extraconal abnormalities. The findings were thought to represent bilateral accessory extraocular muscles. The patient underwent surgery the following month. During surgery, the ophthalmologists placed a radiopaque string around what was thought to be the anomalous muscle tissue and performed an intraoperative CT scan to confirm that the correct tissue was resected.

Frozen and formalin-fixed sections of skeletal muscle stained with hematoxylin-eosin, Gomori trichrome, adenosine triphosphatase (pH 9.4 and 4.2), and nicotinamide adenine dinucleotide (diphosphopyridine nucleotide) showed preservation of fascicular architecture with no increase in connective tissue and no evidence of inflammation or vasculitis. There was mild variation in fiber sizes and a slight increase in the internal nuclei; both features are expected for extraocular muscle.

Following surgery, the patient's ocular deviation improved

Received July 6, 2010; accepted after revision July 15.

From the Departments of Radiology (M.D.D.), Ophthalmology (L.A.M., S.P.D.), Neurosurgery (L.A.M.), Pediatrics (S.P.D.), and Neurology (S.P.D.), Vanderbilt University Medical Center, Nashville, Tennessee.

L.A. Mawn is funded by a grant from Research to Prevent Blindness, New York, New York.

Please address correspondence to Matthew Dobbs, MD, Department of Radiology, Vanderbilt University Medical Center, 1161 Medical Center Dr, Medical Center North, CCC-1106, Nashville, TN 37232; e-mail: matthew.dobbs@vanderbilt.edu

<http://dx.doi.org/10.3174/ajnr.A2291>

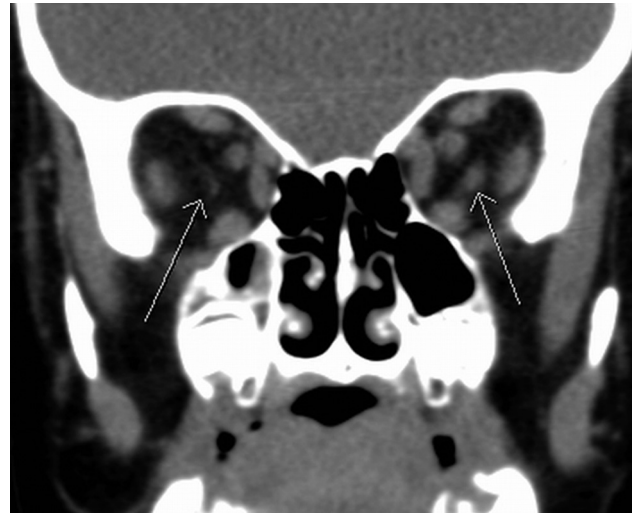


Fig 1. Coronal unenhanced CT scan of the orbits at the level of the ethmoid sinuses demonstrates bilateral accessory extraocular muscles (arrows) medial to the lateral rectus muscles, superior to the inferior rectus muscles, and inferolateral to the optic nerves. Attenuation is similar to that of surrounding extraocular muscles. The structure is much larger on the left side.

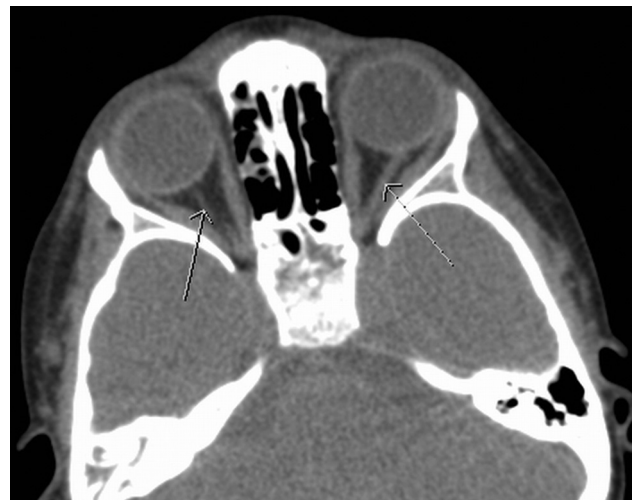

Fig 2. Axial unenhanced CT scan of the orbits at the level of the greater sphenoid wing demonstrates accessory extraocular muscles (arrows) medial to the lateral rectus muscles and lateral to the optic nerves (not shown on this image) that arise from the orbital apex at the annulus of Zinn and insert directly on the posterior globe, with no bridging connection or assimilation into the surrounding muscles.

markedly. The thin sliver of tissue within the contralateral right orbit was not resected because it did not cause any clinical abnormality.

Discussion

Accessory extraocular muscles are very rare, having only been described in scattered case reports. The true prevalence is unknown due to the rare presentation. A few similar cases have been reported in the ophthalmic and pathologic literature.^{1,2} To our knowledge, there are no reports in the radiologic literature.

Three broad types of accessory extraocular tissue have been reported including anomalous bands of muscle bridging 2 muscles; fibrous tissues adjacent to the muscles, which may attach to the globe; and muscles arising from the posterior orbit and inserting on the globe or extraocular muscles.¹

An interesting hypothesis of accessory musculature was proposed by Whitnall in 1911,³ asserting that these fibromuscular bands of tissue may represent an atavistic retractor bulbi muscle. This is a muscle found normally in reptiles, amphibians, and some ruminants but not in *Homo sapiens*, allowing retraction of the globe into the orbital cavity for protection.

Our patient did show retraction of the globe with attempted extraocular movements. Rather than an atavistic retractor bulbi muscle, our patient's findings could be considered as an accessory lateral rectus muscle. One argument against an accessory lateral rectus muscle is that this anomalous muscle did not appear radiographically to originate on the lateral rectus as described by Narasimhan et al.⁴ The anomalous muscle seen in our patient originated at the orbital apex at the optic foramen. Surgically, the muscle was extremely taut and inserted directly into the posterior globe, slightly inferolateral to the optic nerve.

An argument against this muscle being a vestigial retractor bulbi muscle is that it was an isolated distinct muscle and did not have pathologic features suggestive of skeletal muscle but rather had features typical of extraocular muscle.⁵ The described atavistic retractor bulbi muscles have either a cone shape or multiple tendon slips that surround the optic nerve region.⁶ Our patient lacked these findings.

We believe that this accessory muscle resulted from a disturbance of the mesodermal development of the extraocular muscles. Releasing this anomalous muscle from the globe relieved the globe retraction and significantly improved the exotropia.

Our patient coincidentally has Gorlin syndrome, which is due to a mutation at chromosome location 9q22.3-q31.⁷ This mutation causes loss of function of the *PTCH1* receptor, of

which sonic hedgehog protein is the ligand.^{8,9} Gorlin syndrome is associated with subsequent excessive hedgehog signaling, one of the pathways that directs development during embryogenesis, and is associated with the increased risk of basal cell carcinoma and medulloblastoma seen in patients with this syndrome.⁹ No association has been made between Gorlin syndrome and accessory extraocular muscles, but animal research shows induction and promotion of muscle development due to hedgehog signaling.¹⁰⁻¹³ One recent report found a patient presenting with exotropia similar to that in our patient, but the underlying cause was found to be an odontogenic keratocyst (a classic finding in Gorlin syndrome) of the alveolar ridge causing outward deviation of the globe.¹⁴

This case provides an example of a rare anatomic anomaly that has significant clinical pertinence. Awareness of such an entity can improve the search pattern of radiologists evaluating patients with atypical strabismus because this anomaly is amenable to surgical resection.

References

1. Lueder GT. **Anomalous orbital structures resulting in unusual strabismus.** *Surv Ophthalmol* 2002;47:27-35
2. Kirkham TH. **Accessory extraocular muscle.** *Br J Ophthalmol* 1970;54:276-77
3. Whitnall SE. **An instance of the retractor bulbi muscle in man.** *J Anat Physiol* 1911;46:36-40
4. Narasimhan A, Tychsen L, Poukens V, et al. **Horizontal rectus muscle anatomy in naturally and artificially strabismic monkeys.** *Invest Ophthalmol Vis Sci* 2007;48:2576-88
5. Porter JD, Baker RS, Ragusa RJ, et al. **Extraocular muscles: basic and clinical aspects of structure and function.** *Surv Ophthalmol* 1995;39:451-84
6. von Ludinghausen M. **Bilateral supernumerary rectus muscles of the orbit.** *Clin Anat* 1998;11:271-77
7. Farndon PA, Del Mastro RG, Evans DG, et al. **Location of gene for Gorlin syndrome.** *Lancet* 1992;339:581-82
8. Johnson RL, Rothman AL, Xie J, et al. **Human homolog of patched, a candidate gene for the basal cell nevus syndrome.** *Science* 1996;272:1668-71
9. Epstein EH. **Basal cell carcinomas: attack of the hedgehog.** *Nat Rev Cancer* 2008;8:743-54
10. Duprez D, Fournier-Thibault C, Le Douarin N. **Sonic hedgehog induces proliferation of committed skeletal muscle cells in the chick limb.** *Development* 1998;125:495-505
11. Duprez D, Lapointe F, Edom-Vovard F, et al. **Sonic hedgehog (SHH) specifies muscle pattern at tissue and cellular chick level, in the chick limb bud.** *Mech Dev* 1999;82:151-63
12. Li X, Blagden CS, Bildsoe H, et al. **Hedgehog can drive terminal differentiation of amniote slow skeletal muscle.** *BMC Dev Biol* 2004;4:9
13. Feng X, Adiarde EG, Devoto SH. **Hedgehog acts directly on the zebrafish dermomyotome to promote myogenic differentiation.** *Dev Biol* 2006;300:736-46. Epub 2006 Aug 30
14. Hall J, Johnston KA, McPhillips JP, et al. **Nevoid basal cell carcinoma syndrome in a black child.** *J Am Acad Dermatol* 1998;38:363-65