

Are your MRI contrast agents cost-effective?

Learn more about generic Gadolinium-Based Contrast Agents.



FRESENIUS
KABI

caring for life

AJNR

Can We Perform Spinal ^1H -MR Spectroscopy in Daily Clinical Practice?

L.C. Hygino da Cruz, Jr

AJNR Am J Neuroradiol 2013, 34 (12) E128-E129

doi: <https://doi.org/10.3174/ajnr.A3809>

<http://www.ajnr.org/content/34/12/E128>

This information is current as of April 16, 2024.

Can We Perform Spinal ¹H-MR Spectroscopy in Daily Clinical Practice?

I read with great interest the review article by Hock et al¹ and agree with the authors that ¹H-MR spectroscopy can be of great value in the assessment of a variety of spinal cord diseases. The difficulty in determining a specific diagnosis of these lesions is a challenge in their management. It is necessary to predict an appropriate treatment and avoid an unnecessary invasive intervention, such as biopsy or surgery. Thus, a reliable differential diagnosis can be obtained by using functional MR imaging techniques, which have been used for a long time to evaluate brain lesions. Technical limitations due to a low signal-to-noise ratio and the proximity to the bone and CSF interface have been described as important limitations to the use of functional MR images in the evaluation of spinal cord lesions.

We describe a case of a 79-year-old man with systemic non-Hodgkin lymphoma, with a solitary, solid, enhancing lesion in the cervical spine (Fig 1). Single-voxel ¹H-MR spectroscopy was performed in a 1.5T MR imaging clinical scanner (Fig 2). Saturation bands, to reduce CSF pulsation artifacts and to suppress signals from outside the voxel, were placed surrounding the voxel. We did not use electrocardiography or respiratory triggering or gating. The voxel size used was 10 × 10 × 20 mm³. TE was 30 ms and TR was 1500 ms; the number of averages was 160, resulting in a total scanning time of 4 minutes.

To our knowledge and on the basis of the extended review of the literature shown by Hock et al,¹ no previous publication described the MR spectroscopy changes observed in a spinal cord lymphoma. Intramedullary spinal lymphoma is a very rare neoplasm that accounts for approximately 3.3% of all CNS lymphomas, which consist of only 1% of all lymphomas in the body.² Most are solitary lesions located in the cervical spine.

Previous reports used ¹H-MR spectroscopy to evaluate brain lymphoma and basically found elevated lipid peaks, a high choline/creatine ratio, and a low *N*-acetylaspartate/creatine ratio.³ ¹H-MR spectroscopy findings of spinal lesions were similar to

those described in the brain. In this particular case, we also performed diffusion-weighted MR imaging. The lesion demonstrated restricted diffusion, which has been described as related to the high cellularity and a high nuclear-cytoplasmic ratio, characteristic findings of lymphoma.³ On the basis of these findings and with the clinical history of the patient, we made a presumptive diagnosis of spinal cord lymphoma, avoiding an invasive diagnostic intervention.

We demonstrated the feasibility and the potential of applying MR spectroscopy to assess spinal cord lesions in daily clinical practice, even though some technical obstacles can be observed. We used a clinical 1.5T MR imaging scanner to obtain reliable MR spectra and in less than the average scanning time presented by Hock et al¹; this scanning time, in our view, can be reliably used in clinical practice. Thus, one may conclude that it is not totally necessary to perform the examination in a 3T MR imaging scanner with a long scanning time.

In conclusion, we propose that by exploiting the higher SNR available with new 1.5T scanners with multichannel coils, MR spectra can be obtained in a 1.5T scanner with a scanning time as short as 4 minutes, without compromising quality. The clinical accuracy of this technique needs to be investigated in a broader clinical setting in patients with spinal cord lesions.

REFERENCES

1. Hock A, Henning A, Boesiger P, et al. ¹H-MR spectroscopy in the human spinal cord. *AJNR Am J Neuroradiol* 2013;34:1682–89
2. Koeller KK, Rosenblum RS, Morrison AL. Neoplasms of the spinal cord and filum terminale: radiologic-pathologic correlation. *Radiographics* 2000;20:1721–49
3. Haldorsen IS, Espeland A, Larsson EM. Central nervous system lymphoma: characteristic findings on traditional and advanced imaging. *AJNR Am J Neuroradiol* 2011;32:984–92

L.C. Hygino da Cruz Jr
Clinicas CDPI and IRM
Federal University of Rio de Janeiro
Rio de Janeiro, Brazil

<http://dx.doi.org/10.3174/ajnr.A3809>

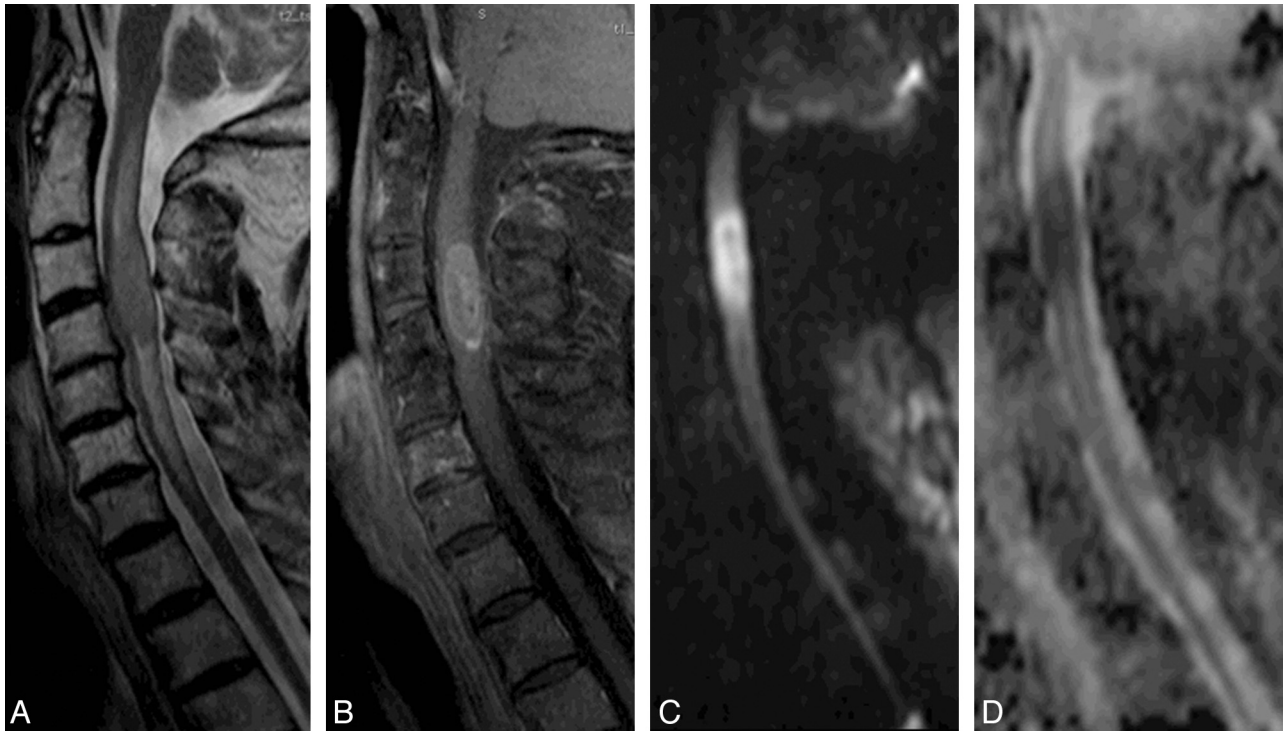

FIG 1. A solid spinal cord expansion lesion is demonstrated in a 79-year-old man with non-Hodgkin lymphoma. Sagittal T2-weighted image (A) shows an expansive hypointense lesion, surrounded by edema, which enhances after the intravenous contrast administration in the sagittal T1-weighted image (B). The lesion also has restricted diffusion on DWI (C), confirmed on the ADC map (D).

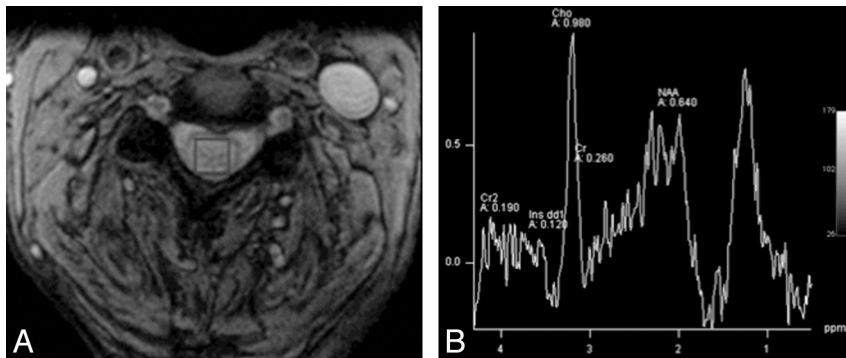


FIG 2. ^1H -MR spectroscopy was performed by placing the voxel within the lesion (A) and demonstrates characteristic findings of lymphoma: elevated lipid peaks, a high choline/creatine ratio, and a low *N*-acetylaspartate/creatine ratio (B).