Are your MRI contrast agents cost-effective?
Learn more about generic Gadolinium-Based Contrast Agents.
FRESENIUS KABI
caring for life

AJNR

Subdural Hygromas in Abusive Head Trauma: Pathogenesis, Diagnosis, and Forensic Implications

D. Wittschieber, B. Karger, T. Niederstadt, H. Pfeiffer and M.L. Hahnemann

This information is current as of April 18, 2024.

AJNR Am J Neuroradiol 2015, 36 (3) 432-439
doi: https://doi.org/10.3174/ajnr.A3989
http://www.ajnr.org/content/36/3/432

Subdural Hygromas in Abusive Head Trauma: Pathogenesis, Diagnosis, and Forensic Implications

D. Wittschieber, B. Karger, T. Niederstadt, H. Pfeiffer, and M.L. Hahnemann

ABSTRACT

SUMMARY: Are subdural hygromas the result of abusive head trauma? CT and MR imaging represent important tools for the diagnosis of abusive head trauma in living infants. In addition, in-depth understanding of the pathogenesis of subdural hygromas is increasingly required by neuroradiologists, pediatricians, and forensic physicians. Therefore, the current knowledge on subdural hygromas is summarized and forensic conclusions are drawn. The most important diagnostic pitfalls, benign enlargement of the subarachnoid space, and chronic subdural hematoma, are discussed in detail. Illustrative cases from forensic practice are presented. Literature analysis indicates that subdural hygromas can occur immediately or be delayed. If other infrequent reasons can be excluded, the presence of subdural hygromas strongly suggests a posttraumatic state and should prompt the physician to search for other signs of abuse. To differentiate subdural hygromas from other pathologies, additional MR imaging of the infant's head is indispensable after initial CT scan.

ABBREVIATIONS: AHT = abusive head trauma; BESS = benign enlargement of subarachnoid space; BV = bridging vein; cSDH = chronic subdural hematoma; SDH = subdural hematoma; SDHy = subdural hygroma

Child abuse represents a very heterogeneous, unfortunately still present, and therefore well-established research field within the forensic sciences.[1-6] According to the Committee on Child Abuse and Neglect of the American Academy of Pediatrics, abusive head trauma (AHT), also referred to as nonaccidental head injury, is still the leading cause of child abuse fatalities.[7-9] The incidence of AHT in children under 1 year of age ranges between 14 and 28 per 100,000 live births in Western countries.[10-15] Direct blunt force to the head and the so-called Shaken Baby syndrome are currently assumed to be the main etiologic factors of AHT.[9,16-18] The full-blown clinical picture of Shaken Baby syndrome is characterized by the triad of subdural hematomas (SDHs), retinal hemorrhages, and encephalopathy. In some cases, metaphyseal fractures, rib fractures, or small hematomas on arms or thorax may be encountered.[18-22] The caregiver's explanation provided for the injuries is frequently inadequate or inconsistent.[9,18]

The diagnosis and dating of AHT in living infants predominantly relies on neuroimaging by means of CT and/or MR imaging.[23-30] An important indicator for AHT is the presence of SDHs attributed to defects of the bridging veins (BVs). Moreover, in some cases suspected for AHT, radiologists are confronted with almost homogeneous fluid collections within the subdural space, which appear isodense/isointense or nearly isodense/isointense to CSF. These collections are then interchangeably termed as subdural hygromas (SDHys), chronic subdural hematomas (cSDHs), or a terminologic mixture of both: chronic hygromas. This radiologic diagnosis has often resulted in difficulties with regard to the medicolegal assessment of such cases because the exact pathogenesis, diagnosis, and significance of SDHys are still a matter of debate and uncertainty, particularly in infants.[31,32] However, these issues can be decisive in court, for example, when SDHys are considered as evidence for the age of injury.

Therefore, the present review addresses the following questions:

1. What are SDHys?
2. What are the current theories regarding the pathogenesis of SDHy?
3. Which alternative explanations and differential diagnoses have to be considered?
4. What forensic implications arise concerning AHT?

From the Departments of Forensic Medicine (D.W., B.K., H.P.) and Clinical Radiology (T.N.), University Hospital Münster, Münster, Germany; and Department of Diagnostic and Interventional Radiology and Neuroradiology (M.L.H.), University Hospital Essen, Essen, Germany.

Please addresss correspondence to Daniel Wittschieber, MD, Department of Forensic Medicine, University Hospital Münster, Röntgenstraße 23, 48149 Münster, Germany; e-mail: daniel.wittschieber@ukmuenster.de

Indicates open access to non-subscribers at www.ajnr.org

http://dx.doi.org/10.3174/ajnr.A3989

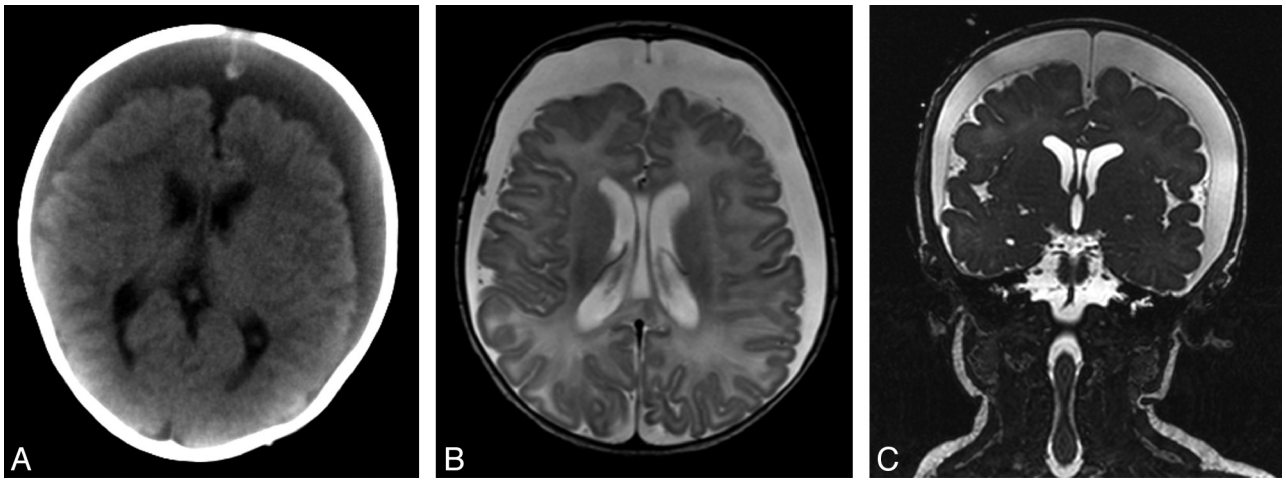

FIG 1. Two-month-old boy with huge hypodense, CSF-like, subdural collections lacking encapsulating membranes (*A*, cranial CT). MR imaging confirmed the diagnosis of frontoparietal SDHys on both sides (*B*, axial T2-weighted image; *C*, coronal T2-weighted image).

What are Subdural Hygromas?

Pathology is always based on anatomy. Under physiologic conditions, the subdural space does not exist in humans. It does not open until the dura-arachnoid interface is mechanically separated, for instance due to brain shrinking, trauma, or neurosurgical interventions.[33-35] This opening is actually regarded as a cleaving of the so-called dural border cell layer—the innermost zone of the dura mater—and therefore also referred to as intradural lesion.[33,36] Nevertheless, in this article, the traditional term subdural is used to describe accordant pathologies within that space such as SDHy.

SDHys can be regarded and examined from 2 different points of view: first, the traditional perspective of the neuropathologist, forensic pathologist, or neurosurgeon who directly investigate or treat colorful 3D pathologies in the human head; and second, the perspective of the neuroradiologist who indirectly evaluates and interprets 2D black-and-white cross-sectional images from CT, MR imaging, or sonography.

With respect to the traditional macroscopic perspective, the term *Hygroma durae matris* (hygrós [gr.] = wet, moist) was first introduced by Rudolph Virchow in 1856.[37] Many other terms, such as subdural hydroma, *Meningitis serosa traumatica*, traumatic subdural effusion, or simply subdural fluid accumulation have also been used.[33,38-42] SDHys are classically described as protein-rich, clear, pink-tinged, or xanthochromic fluid collections within the subdural space.[22,37,42-47] Likewise, if the principal component of a subdural collection appears to be CSF-like, the term SDHy is used.[44,48-50] A mixture of blood and CSF is referred to as hematohygroma.[51-54]

The heterogeneous appearances of SDHys prompted Unterharnscheidt[37] to differentiate between 2 general morphologic types:

1. Cystic and often multichambered formations encapsulated by a membrane.
2. "Free" fluid collections without any capsule.

In radiology, the definition of SDHy is more difficult, and the terminology is very heterogeneous. While acute SDH, representing 1 of the leading indicators for Shaken Baby syndrome, can be reliably diagnosed by means of CT and MR imaging, other pathologic fluid collections are often termed interchangeably as SDHys, cSDHs, subdural effusions, chronic hygromas, or simply subdural collections.

The term subdural collection is used as an unspecific umbrella term for pathologically formed subdural fluid, whereas the term chronic hygromas should be principally avoided as it is a very imprecise and pathogenetically insufficient description. If there is a mass of proteinaceous liquid within the subdural space that appears to be associated with bacterial meningitis, it is generally spoken of as a subdural effusion.[54-56]

But what about SDHy versus cSDH? A current neuroradiologic textbook by Osborn[55] defines SDHys as "hypodense, CSF-like, crescentic extraaxial collections that consists purely of CSF, have no blood products, lack encapsulating membranes, and show no enhancement following contrast administration" (Fig 1). This description is strikingly similar to the second morphologic type of SDHy suggested above by Unterharnscheidt.[37] However, this CSF-like appearance is also the reason why SDHys harbor a high potential to be confused with cSDHs.[57] According to Osborn,[55] cSDHs may be defined as "encapsulated collections of sanguineous or serosanguineous fluid confined within the subdural space." This description, on the other hand, closely resembles the first of Unterharnscheidt's[37] morphologic types of SDHy suggesting that cSDHs diagnosed by radiologists can also be termed as SDHys. In fact, the terms cSDH (in the meaning of old SDH) and SDHy are frequently used as synonyms in radiologic reports as well as in recent scientific literature.[34] Thereby, it is implied that SDHys solely indicate remnants of SDHs.

But is this simplification true? This may become an important issue for the forensic expert in court. Once the radiologic diagnosis of SDHy is made, the forensic expert will likely be confronted with 2 questions: Does the SDHy represent a result of AHT? And if yes, does it indicate recent injury, old injury, or, when in combination with other types of subdural collections, the presence of multiple injuries that occurred at different times? Therefore, it is important to understand how SDHys develop or what they originate from.

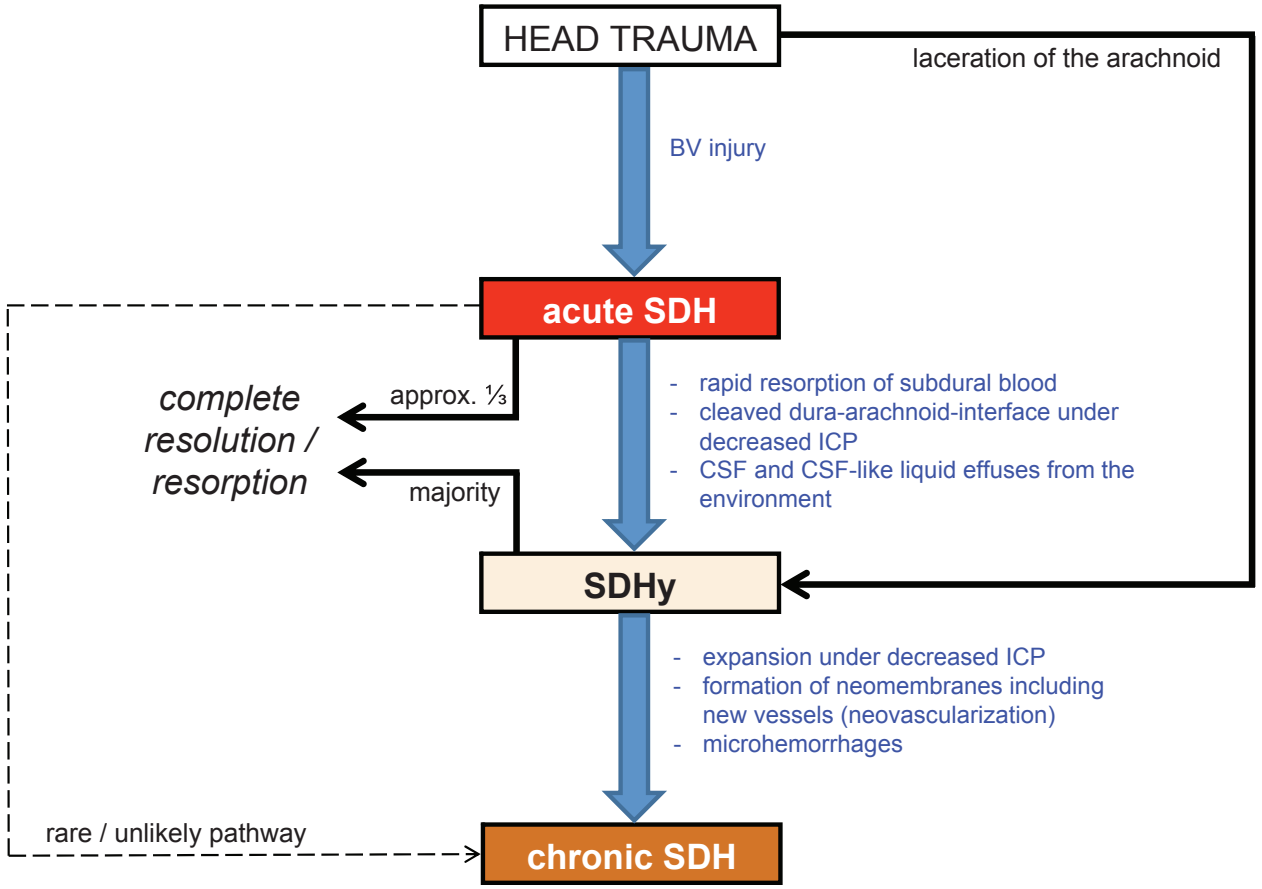

FIG 2. Simplified schematic drawing of the pathogenetic pathways of the origin and fate of SDHys. ICP indicates intracranial pressure.

The Pathogenesis of Subdural Hygromas: An Ongoing Odyssey

Among neurotraumatologists it is generally known that SDHys usually derive from head injuries and represent rare posttraumatic complications that may coexist with epidural or subdural hematomas.[33,42,43,57-60] Unfortunately, the causes of SDHys cannot always be read directly from the CT or MR images. Numerous scientists from different disciplines sought to address this problem in the last decades. Particularly in infants, SDHys are not well described and only little understood. Children were even excluded in a recent radiologic SDHy study because their pathogenetic aspects were considered a priori as different from adults.[61]

Hereafter, the 2 current basic concepts of SDHy formation with their different medicolegal implications, as well as important alternative explanations, are presented.

Concept 1: Delayed Formation of Subdural Hygromas

It appears to be widely presumed that SDHys represent liquefied and/or deposited remnants of a previous acute SDH[52,62-65,82] suggesting that, in a case of suspected child abuse, the baby could have been abused weeks ago. In 1857, Rudolph Virchow considered SDHys as "final stages of subdural hemorrhages."[37] But are SDHys really direct remnants of acute SDHs?

An advanced approach was developed considering additional aspects of SDHy formation. The suggested process describes the conversion of acute SDH into cSDH via SDHy as an intermediate stage (blue pathway in Fig 2).[47,66] Because most acute SDHs resolve rapidly, reflecting the high levels of tissue thromboplastin in brain tissue and CSF,[67] this approach has been refined by other authors. During the dissolving of the acute SDH, especially if decreased intracranial pressure is present, the cleaved dura-arachnoid interface is assumed to remain as persistent posttraumatic space. Liquid remnants of the acute SDH or CSF might then pass into that opened space by effusion from surrounding vessels or even the subarachnoid space, forming the SDHy.[50,52] It should be noticed that in this approach, the SDHy is considered as a consequence of the SDH but not as a directly transformed remnant of it.

Alternatively, Mack et al[36] suggested that CSF could physiologically move from the subarachnoid space into interstitial spaces of the dura mater and subsequently via the dural venous plexus into the dural sinuses. CSF might therefore be present in small amounts in the dura at all times. In any cases of alteration of this CSF absorption pathway—for instance from bleeding into the dural layers—a disruption of the transport mechanism may result in delayed accumulation of CSF within the subdural space producing imaging findings of SDHy. Approximately 30 years earlier, it was hypothesized that concurrent traumatic subarachnoid hemorrhages, that are frequently found together with SDHy, may secondarily predispose to defective CSF resorption leading to enlargement of subdural CSF collections as well.[43,68,69] In the end, SDHys represent a subsequent result of acute SDHs.

Following the concept of delayed SDHy formation, the pres-

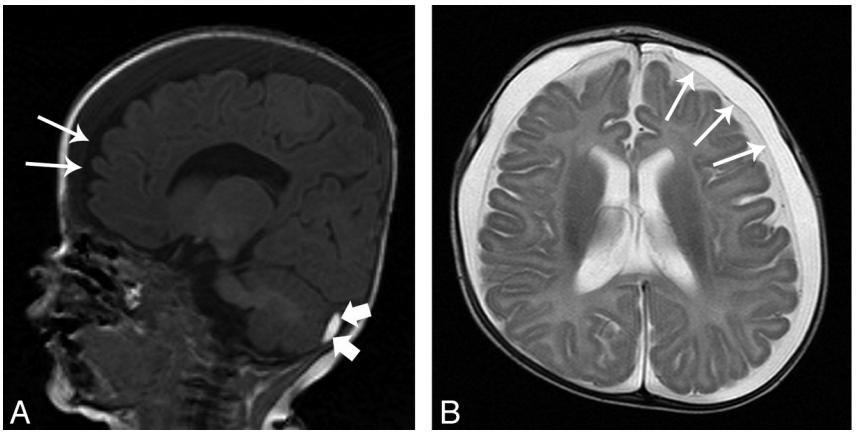

FIG 3. MR imaging scan of a 5-month-old female infant who showed a sudden increase of head circumference (from 50th to 97th percentile within 1 month). Frontoparietal SDHys (maximum width of 11 mm) as well as enlarged subarachnoid spaces (maximum width of 4 mm) were found on both sides (*A*, sagittal T1-weighted image; *B*, axial T2-weighted image; *thin arrows* indicate position of the subarachnoid membrane). In addition, a small subacute SDH was diagnosed in the left posterior cranial fossa beneath the tentorium cerebelli (*A*, *small thick arrows* indicate subdural blood). In the preceding months, periodic sonography scans of the head did not ever show any abnormalities with respect to the subdural or subarachnoidal space. Ophthalmologic examination revealed sub- and epiretinal hemorrhages distributed over the whole fundus area of both eyes. These retinal hemorrhages were not present yet in a check-up examination 1 month after birth. As further clinical diagnostics have ruled out coagulopathies, neoplastic diseases, and metabolic disorders, the presence of SDH and retinal hemorrhage prove substantial (sub)acute head trauma and therefore strongly suggest child abuse (AHT). The enlarged subarachnoid spaces, found after the trauma diagnosis, have rather to be regarded as consequence and not as source (see "BESS" section). Hence, the SDHy in this well-documented case can be regarded as a result of acute injury.

ence of SDHy may be medicolegally interpreted as later consequence of AHT that occurred some days or a few weeks before.

Concept 2: Rapid Formation of Subdural Hygromas

This theory suggests SDHy to be caused by a laceration in the arachnoid.[33,37-39,49-51,53,70-72] Hence, SDHy can result from trauma and from cranial operations in which the arachnoid membrane is opened, leading to CSF transfer into the subdural space.[33] For this, the term acute SDHy has been suggested.[52] A ball-valve mechanism of the arachnoid is assumed to prevent a backflow of CSF into the subarachnoid space.[33,72]

In regard to a 74-year-old woman with acute SDHy and subarachnoid hemorrhage after accidental head injury, Kamezaki et al[73] discussed a tear of the arachnoid membrane as possible reason for the SDHy. Radiotracer and cisternography studies performed in infants with SDHy were able to show that radioisotopes (eg, indium-111) injected into the subarachnoid space move into the subdural compartment.[44,53] In addition, the CSF-specific β-trace protein and other proteins have been found up to 100% of SDHys,[74,75] indicating that there really is CSF in the subdural space.

Zouros et al[53] reported on 5 infants with suspected AHT showing acute hematohygromas. Encapsulating neomembranes, possibly indicating the presence of cSDH (see below: "Differential Diagnoses of Subdural Hygromas"), were not found either on MR imaging or at surgery. In addition, free CSF communication between subarachnoid and subdural space was proved in all cases by radiotracer injection. The authors proposed a mechanism whereby SDHy directly originates from shaking the baby: during acceleration and deceleration of the brain, acute shear strains between arachnoid and dura may disrupt both the BVs and the weak arachnoid attachments to the parasagittal dura (Pacchioni granulations). Thereby, a mixture of CSF and blood products can flow into the traumatically opened subdural space resulting in an acute subdural hematohygroma.[53]

This is not only a plausible explanation for the known mixed-density appearance of subdural collections frequently seen in AHT cases. The injured arachnoid granulations also explain the often-described occurrence of enlarged subarachnoid spaces because of suboptimal CSF absorption.

Following this concept of rapid formation, SDHys must not be considered automatically as direct remnants or delayed consequence of acute SDHs but SDHy and acute SDH may develop simultaneously as exemplified in Figure 3. Medicolegal expert opinions should therefore consider the possibility of an rapid formation of SDHy as an additional symptom indicating AHT.

Alternative Explanations

Besides the 2 main theories introduced above, additional theories regarding the formation of SDHys are discussed. In terms of forensic issues, 2 in particular are noteworthy:

1. Glutaric aciduria type I: this hereditary disease is caused by a deficiency of the enzyme glutaryl CoA-dehydrogenase and leads to increased urinary excretion of glutaric and 3-hydroxy-glutaric acid.[76] Clinically, macrocephalia and extrapyramidal movement disorders are described. In neuroradiology, frontotemporal atrophy as well as SDHys and/or SDHs are diagnosed.[77,78] Glutaric aciduria type I should therefore be diagnostically excluded in infants with SDHy, because misdiagnosing as AHT may occur in exceptional cases.[79,80]
2. Rupture of pre-existing arachnoid cysts: arachnoid cysts are congenital or acquired intra-arachnoidal CSF collections occurring infrequently. These may rupture because of minor, but identifiable, head trauma, or sudden temporary rise in intracranial pressure.[48,81] Ruptures result in SDHys rather than in SDHs.[48] However, this phenomenon has not been described in infants yet. A review of the literature by Gelabert-González et al[81] demonstrated ages of occurrence ranging from 5 to 25 years. It seems conceivable that arachnoid cysts also rupture in infants and are not yet acknowledged as such. However, as long as scientific data do not support this possibility, this remains mere speculation.

Differential Diagnoses of Subdural Hygromas

Chronic Subdural Hematoma. Surgeons and pathologists know cSDH as subdural liquid with a dark brown "crank case oil" ap-

pearance.[47] Many cSDHs also contain a mixture of both CSF and blood, such as breakdown products of hemoglobin or other proteins.[55,82] Furthermore, multiple hemorrhages of different ages are supposed to be common (so-called mixed-age SDH).[55] This may sometimes also lead to an attenuation approximating that of CSF.

The pathogenesis of cSDH is not yet clear. cSDHs were observed to evolve directly from acute SDHs in only very few cases (reviewed in[52]). Moreover, experimental studies failed to reproduce cSDH from acute subdural blood.[83,84] It has also been reported that, based on histopathology[85] and CT,[66] chronic and acute SDH should actually be regarded as different entities. cSDH might therefore not be (at least not directly) the last stage of an old acute SDH.

A direct transformation from remnants of an acute SDH into a cSDH is therefore not plausible in all cases. Instead, a more complex pathomechanism must be assumed. As mentioned above (Fig 2), cSDHs were commonly shown, at least in adult trauma cases (mostly traffic crashes), to derive from SDHys with incidence rates between 8% and 58%.[33,47,58,59] Thus, the fate of SDHy is either resolution or cSDH formation.[33,59,75] Under a normal pressure situation, the SDHy resolves. If the decreased intracranial pressure that had led to SDHy formation continues, the SDHy may expand.[50,52] This can enlarge the intradural cleavage (= subdural space filled with SDHy) up to the opposite brain side opening a subdural space even above the falx cerebri. Accordingly, SDHys were frequently observed not to be restricted to the brain side of the "original pathology" (eg, acute SDH).[45]

SDHy can then develop neomembranes from the proliferating dural border cells that are principally able to proliferate in any pathologic process with cleavage of the dural borderzone tissues.[50] Forming of neomembranes is accompanied by neovascularization. Spontaneous microhemorrhages from these fragile new vessels may then occur and lead to a mixture of CSF and blood.[86,87] Therefore, it has been suggested that repeated microhemorrhages possibly convert an SDHy into an expanding cSDH.[33,50,52,57,66]

These pathogenetic considerations show why it is important for the forensic expert to differentiate between cSDH and SDHy. While cSDHs appear to be very rare and delayed consequences of subdural collections, SDHys can apparently develop delayed or rapidly. However, differentiation can be impossible for the radiologist in cases of cSDH appearing CSF-like in CT or MR imaging. These cSDHs are particularly vulnerable to be accidentally referred to as SDHys. Consequently, the terms cSDH and SDHy are often used as synonyms in practice.

Some authors describe the differences between cSDH and SDHy as follows: SDHys are thought to be less than 3 weeks old, static or decreasing, and do not or rarely produce a mass effect, whereas cSDHs are thought to be older than 3 weeks, enlarging, and may cause a mass effect.[50,51,88] However, all these smooth differencing criteria should be handled with care. "Three weeks" cannot be a strict borderline, and most of the aforementioned pathophysiologic data regarding cSDH rely on studies in adults. Thus, it remains at least questionable whether these results can be applied to infants at all.

As SDHys mostly lack neomembranes, this aspect could be another morphologic criterion for differentiation. Neomembranes are usually present in cSDHs and encapsulate the subdural collection as a result of tissue response and may even subdivide it into different chambers.[34,50,55] Although neomembranes are described as becoming visible to the naked eye after approximately 10 days[34] and were shown to aid in dating injuries,[89] diagnosing such membranes in CT or MR imaging can be very challenging.

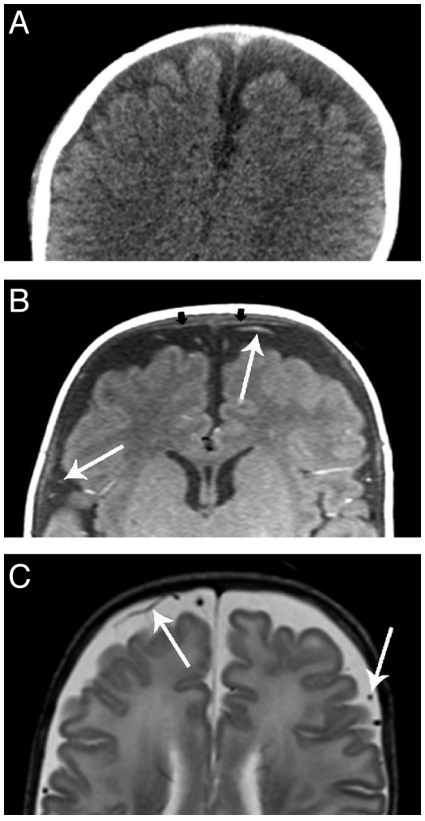

FIG 4. Benign enlargement of the subarachnoid space. While in CT (*A*), BESS could be misdiagnosed as SDHy, MR imaging (*B*, T1-weighted image; *C*, T2-weighted image) clearly demonstrates the presence of BESS. Note the vessels (*thin arrows*) spanning through the subarachnoid space. The small black arrows in *B* point at the subarachnoid membrane.

Benign Enlargement of the Subarachnoid Space. The benign enlargement of the subarachnoid space (BESS) represents an important differential diagnosis for both SDHy and cSDH (Fig 4).[48,51,52,90] These subarachnoid fluid collections are frequently observed and often termed confusingly as "benign hygromas of infancy." BESS probably results from immaturity of the arachnoid villi leading to a transient form of communicating or external hydrocephalus.[52] Infants concerned are usually neurologically uneventful without evidence of prior brain injury.[91] Nowadays, BESS can clearly be distinguished from SDHy (Fig 5), particularly because of improvements in MR imaging technology. In the presence of BESS, the vessels, which run through the subarachnoid space, are localized away from the brain. On the other hand, in the presence of a subdural fluid collection, the vessels can be found near the surface of the brain.

Forensically, it is important to know that long-term observations of infants with BESS as well as a finite element study indicated no increased risk for developing SDH.[92-95] The hypothesis

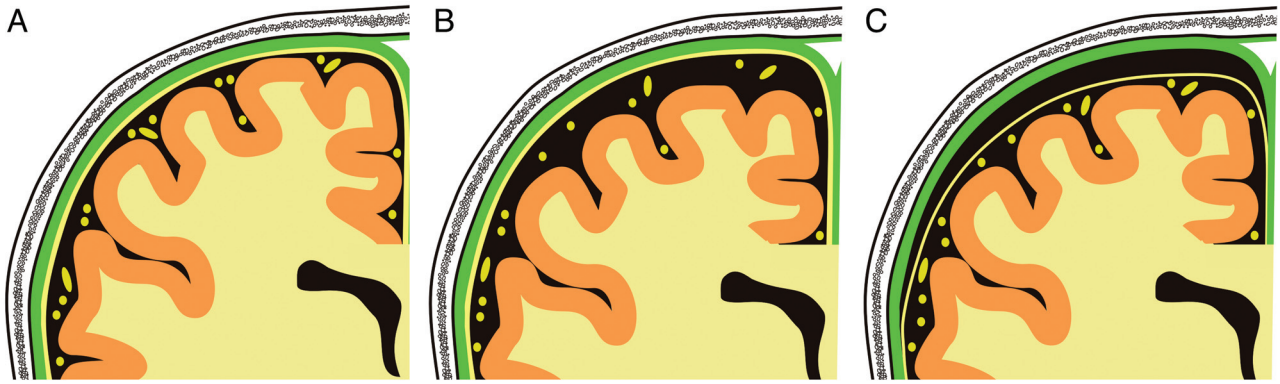

FIG 5. Schematic drawing of the right parietal region as seen in the coronal view imaging. Note the position of the subarachnoid membrane and the subarachnoid vessels (both in yellow). The dura mater is presented in green. *A*, normal situation; *B*, enlarged subarachnoid spaces and *C*, subdural hygroma.

was that stretching of the BV due to enlargement of the subarachnoid space may result in a predisposition to developing SDH. Accordingly, it has been reported that SDHs may occur either spontaneously or as a result of minor trauma in infants with BESS.[96] By contrast, it has been frequently discussed that enlarging of the head circumference because of external hydrocephalus is rather a consequence and not the cause of bleeding, for instance, due to impaired CSF absorption caused by subarachnoid pus, cells, or hemorrhage, or by SDH.[51,54,95]

Besides BESS, it is essential to know that, in general, the subarachnoid spaces are relatively larger in the first 2 years of life than in older children or adults.[52,82,87] According to Libicher and Tröger,[97] head sonography of 89 healthy American infants revealed the distances between the inner calvarian table and the cerebral cortex to range from 0.3 to 6.3 mm (upper limit proposed based on the 95th percentile: 4 mm).The infants' head circumferences of that study were found to be between the 3rd and 97th percentile. In addition, cerebral atrophy, for example, as a result of AHT, may also lead to the impression of enlarged subarachnoid spaces.[52,82]

CONCLUSIONS

SDHy and cSDH are often difficult to distinguish from each other and are often used synonymously in daily case work. While cSDHs in infants are rare and rather implicate a delayed and nonacute process, SDHys may develop rapidly or be delayed. Accordingly, early hypodensity in infantile SDH has also been observed by others[51,98-100] arguing against an overhasty diagnosis of a chronic process but suggesting a significant role of CSF.

On one hand, SDHys are classically considered as remains of a previous SDH, directly or indirectly, which strongly suggests a trauma of cortical BVs and a delayed formation of SDHys (see Concept 1 section). On the other hand, acute pathogenesis of SDHys has been verified by traumatically induced tears in the arachnoid membrane (see Concept 2 section). In all probability, multiple mechanisms exist and also coexist. Accordingly, it is not adequate to state different ages of injuries when SDH and SDHy are present concomitantly.

Both concepts presented have 1 thing in common: if other infrequent reasons and differential diagnoses have been excluded, the presence of SDHy strongly suggests trauma, or more precisely: a posttraumatic state. The presence of SDHy in infants therefore represents compelling reason to search for other signs of AHT such as retinal hemorrhages, fractures, bruises, or inadequate explanations for trauma.

The usage of SDHy for age estimation of head trauma is difficult and should not be considered as the most important factor in determining the time of injury.[53] Hence, as already proposed by Vezina,[51] in initial CT investigations, it is best to describe subdural collections only in terms of density (hypo-, hyper-, isodense, or mixed) and strongly avoid labels such as "acute" or "chronic."

If additional presurgical MR imaging scans of the head exist, further assessment is possible. MR imaging is clearly more sensitive to the presence of SDH, BESS, neomembranes, and injuries of the cerebrum, brain stem, or upper cervical cord. Furthermore, temporal development of intracranial hemorrhages by means of MR imaging is well studied.[51,52]

To conclude, evaluation of SDHy cases should ideally be done in close cooperation between neuroradiology, pediatrics, and forensic medicine. The initial neuroradiologic evaluation is of particular importance and indispensable for correct medicolegal conclusions.

REFERENCES

1. Jacobi G, Dettmeyer R, Banaschak S, et al. **Child abuse and neglect: diagnosis and management.** *Dtsch Arztebl Int* 2010;107:231–39
2. Friedrich K, Becker K, Rothschild MA, et al. **Child abuse inflicted by small children.** *Int J Legal Med* 2013;127:627–30
3. Bilo RAC, Robben SGF, van Rijn RR. **General aspects of fractures in child abuse.** In: Bilo RAC, Robben SGF, van Rijn RR, eds. *Forensic Aspects of Paediatric Fractures. Differentiating Accidental Trauma From Child Abuse*. New York: Springer-Verlag; 2010:1–13
4. Trübner K, Schubries M, Beintker M, et al. **Genital findings in boys suspected for sexual abuse.** *Int J Legal Med* 2013;127:967–70
5. Modelli ME, Galvão MF, Pratesi R. **Child sexual abuse.** *Forensic Sci Int* 2012;217:1–4
6. Schulte B, Rothschild MA, Vennemann M, et al. **Examination of (suspected) neonaticides in Germany: a critical report on a comparative study.** *Int J Legal Med* 2013;127:621–25
7. Duhaime AC, Christian CW, Rorke LB, et al. **Nonaccidental head injury in infants–the "shaken-baby syndrome."** *N Engl J Med* 1998;338:1822–29
8. American Academy of Pediatrics: Committee on Child Abuse and

Neglect. **Shaken baby syndrome: rotational cranial injuries—technical report.** *Pediatrics* 2001;108:206–10
9. Herrmann B. **Nichtakzidentelle kopfverletzungen und schütteltrauma–klinische und pathophysiologische aspekte.** *Rechtsmedizin* 2007;18:9–16
10. Jayawant S, Rawlinson A, Gibbon F, et al. **Subdural haemorrhages in infants: population based study.** *BMJ* 1998;317:1558–61
11. Barlow KM, Minns RA. **Annual incidence of shaken impact syndrome in young children.** *Lancet* 2000;356:1571–72
12. Keenan HT, Runyan DK, Marshall SW, et al. **A population-based study of inflicted traumatic brain injury in young children.** *JAMA* 2003;290:621–26
13. Hobbs C, Childs AM, Wynne J, et al. **Subdural haematoma and effusion in infancy: an epidemiological study.** *Arch Dis Child* 2005; 90:952–55
14. Talvik I, Metsvaht T, Leito K, et al. **Inflicted traumatic brain injury (ITBI) or shaken baby syndrome (SBS) in Estonia.** *Acta Paediatr* 2006;95:799–804
15. Fanconi M, Lips U. **Shaken baby syndrome in Switzerland: results of a prospective follow-up study, 2002–2007.** *Eur J Pediatr* 2010;169:1023–28
16. Christian CW, Block R, Committee on Child Abuse, et al. **Abusive head trauma in infants and children.** *Pediatrics* 2009;123:1409–11
17. Gill JR, Goldfeder LB, Armbrustmacher V, et al. **Fatal head injury in children younger than 2 years in New York City and an overview of the shaken baby syndrome.** *Arch Pathol Lab Med* 2009;133:619–27
18. Matschke J, Herrmann B, Sperhake J, et al. **Shaken baby syndrome: a common variant of non-accidental head injury in infants.** *Dtsch Arztebl Int* 2009;106:211–17
19. Matschke J, Püschel K, Glatzel M. **Ocular pathology in shaken baby syndrome and other forms of infantile non-accidental head injury.** *Int J Legal Med* 2009;123:189–97
20. Martrille L, Cattaneo C, Dorandeu A, et al. **A multicentre and prospective study of suspected cases of child physical abuse.** *Int J Legal Med* 2006;120:73–78
21. Herman BE, Makoroff KL, Corneli HM. **Abusive head trauma.** *Pediatr Emerg Care* 2011;27:65–69
22. Squier W. **The "shaken baby" syndrome: pathology and mechanisms.** *Acta Neuropathol* 2011;122:519–42
23. Fernando S, Obaldo RE, Walsh IR, et al. **Neuroimaging of nonaccidental head trauma: pitfalls and controversies.** *Pediatr Radiol* 2008;38:827–38
24. Hedlund GL, Frasier LD. **Neuroimaging of abusive head trauma.** *Forensic Sci Med Pathol* 2009;5:280–90
25. Choudhary AK, Bradford RK, Dias MS, et al. **Spinal subdural hemorrhage in abusive head trauma: a retrospective study.** *Radiology* 2012;262:216–23
26. Ringl H, Stiassny F, Schima W, et al. **Intracranial hematomas at a glance: advanced visualization for fast and easy detection.** *Radiology* 2013;267:522–30
27. Kemp AM, Rajaram S, Mann M, et al. **What neuroimaging should be performed in children in whom inflicted brain injury (iBI) is suspected? A systematic review.** *Clin Radiol* 2009;64:473–83
28. Kemp AM, Jaspan T, Griffiths J, et al. **Neuroimaging: what neuroradiological features distinguish abusive from non-abusive head trauma? A systematic review.** *Arch Dis Child* 2011;96:1103–12
29. Di Pietro MA, Brody AS, Cassady CI, et al. **Section on radiology; American Academy of Pediatrics. Diagnostic imaging of child abuse.** *Pediatrics* 2009;123:1430–35
30. Sieswerda-Hoogendoorn T, Boos S, Spivack B, et al. **Abusive head trauma part II: radiological aspects.** *Eur J Pediatr* 2012;171:617–23
31. Debertin AS, Sperhake JP. **Untersuchung und dokumentation des nichtakzidentellen schädel-hirn-traumas im säuglings- und kleinkindalter.** *Rechtsmedizin* 2008;18:17–22
32. Bajanowski T, Neuen-Jacob E, Schubries M, et al. **Nichtakzidentelles schädel-hirn-trauma und schütteltrauma.** *Rechtsmedizin* 2008;18:23–28
33. Lee KS. **The pathogenesis and clinical significance of traumatic subdural hygroma.** *Brain Inj* 1998;12:595–603
34. Squier W, Mack J. **The neuropathology of infant subdural haemorrhage.** *Forensic Sci Int* 2009;187:6–13
35. v. Düring M, Dermietzel, Drenckhahn D. **Hirnhäute, ventrikelauskleidung, liquor cerebrospinalis.** In: Benninghoff A, Drenckhahn D, eds. *Anatomie, Band 2.* 16th ed. München: Urban&Fischer/Elsevier; 2004:266–83
36. Mack J, Squier W, Eastman JT. **Anatomy and development of the meninges: implications for subdural collections and CSF circulation.** *Pediatr Radiol* 2009;39:200–10
37. Unterharnscheidt F. **Subdurales hydrom oder hygrom.** In: Doerr W, Seifert G, eds. *Spezielle Pathologische Anatomie, Band 13/VI.A Traumatologie von Hirn und Rückenmark–Traumatische Schäden des Gehirns* (*Forensische Pathologie*). Berlin Heidelberg: Springer-Verlag;1993: 312–22
38. Dandy WE. **Chronic subdural hydroma and serous meningitis (pachymeningitis serosa; localized external hydrocephalus).** In: Lewis D, ed. *Practice of Surgery*. Hagerstown, Maryland: WF Proir Co.; 1932:306–09
39. Dandy WE. **Chronic subdural hydroma and serous meningitis (pachymeningitis serosa; localized external hydrocephalus).** In: Lewis D, ed. *Practice of Surgery.* Hagerstown, Maryland: WF Proir Co.; 1955:291–93
40. Payr E. **Meningitis serosa bei und nach schädelverletzungen (traumatica).** *Med Klin* 1916;12:841–46
41. McConnell AA. **Traumatic subdural effusions.** *J Neurol Neurosurg Psychiatry* 1941;4:273–74
42. Oka H, Motomochi M, Suzuki Y, et al. **Subdural hygroma after head injury. A review of 26 cases.** *Acta Neurochir (Wien)* 1972;26:265–73
43. Stone JL, Lang RG, Sugar O, et al. **Traumatic subdural hygroma.** *Neurosurgery* 1981;8:542–50
44. Hoff J, Bates E, Barnes B, et al. **Traumatic subdural hygroma.** *J Trauma* 1973;13:870–76
45. French BN, Cobb CA III, Corkill G, et al. **Delayed evolution of post-traumatic subdural hygroma.** *Surg Neurol* 1978;9:145–48
46. Wetterling T, Demierre B, Rama B, et al. **The clinical course of surgically treated post-traumatic subdural hygromas.** *Acta Neurochir (Wien)* 1986;83:99–104
47. Lee KS, Bae WK, Park YT, et al. **The pathogenesis and fate of traumatic subdural hygroma.** *Br J Neurosurg* 1994;8:551–58
48. Punt J. **Mechanisms and management of subdural hemorrhage.** In: Minns RA, Brown JK, eds. *Shaking and Other Non-Accidental Head Injuries in Children.* London: Mac Keith Press; 2005:290–313
49. Livingston JH, Childs AM. **The epidemiology of non-accidental head injury.** In: Minns RA, Brown JK, eds. *Shaking and Other Non-Accidental Head Injuries in Children.* London: Mac Keith Press; 2005:147–53
50. Case ME. **Inflicted traumatic brain injury in infants and young children.** *Brain Pathol* 2008;18:571–82
51. Vezina G. **Assessment of the nature and age of subdural collections in nonaccidental head injury with CT and MRI.** *Pediatr Radiol* 2009;39:586–90
52. Hymel KP, Jenny C, Block RW. **Intracranial hemorrhage and rebleeding in suspected victims of abusive head trauma: addressing the forensic controversies.** *Child Maltreat* 2002;7:329–48
53. Zouros A, Bhargava R, Hoskinson M, et al. **Further characterization of traumatic subdural collections of infancy. Report of five cases.** *J Neurosurg* 2004;100(5 Suppl):512–18
54. Hedlund GL. **Subdural hemorrhage and abusive head trauma: challenges and controversies.** Paper presented at: 98th Scientific Assembly and Annual Meeting of the Radiological Society of North America (RSNA), November 25–30, 2012; McCormick Place, Chicago, Illinois.
55. Osborn AG. **Part one: trauma.** In: Osborn AG, ed. *Osborn's Brain: Imaging, Pathology, and Anatomy*. 2nd ed. Salt Lake City: Amirsys; 2013:1–72

56. Hedlund G, Bale JF, Barkovich AJ. **Infections of the developing and mature nervous system.** In: Barkovich AJ, Raybaud, eds. *Pediatric Neuroimaging*. 5th ed. Philadelphia: Lippincott Williams & Wilkins; 2012:954–1050
57. Lee KS, Bae WK, Doh JW, et al. **Origin of chronic subdural haematoma and relation to traumatic subdural lesions.** *Brain Inj* 1998; 12:901–10
58. Ohno K, Suzuki R, Masaoka H, et al. **Chronic subdural haematoma preceded by persistent traumatic subdural fluid collection.** *J Neurol Neurosurg Psychiatry* 1987;50:1694–97
59. Lee KS, Bae WK, Bae HG, et al. **The fate of traumatic subdural hygroma in serial computed tomographic scans.** *J Korean Med Sc* 2000;15:560–68
60. Lee KS. **Natural history of chronic subdural haematoma.** *Brain Inj* 2004;18:351–58
61. Zanini MA, de Lima Resende LA, de Souza Faleiros AT, et al. **Traumatic subdural hygromas: proposed pathogenesis based classification.** *J Trauma* 2008;64:705–13
62. Maxeiner H. **Subduralblutungen: ursachen, arten, folgen und forensische aspekte.** *Rechtsmedizin* 2009;19:111–28
63. Tutsch-Bauer E, Meyer HJ, Monticelli F. **Schütteltrauma.** *Rechtsmedizin* 2005;15:399–408
64. Punt N. **Glossary of terms.** In: Minns RA, Brown JK, eds. *Shaking and Other Non-Accidental Head Injuries in Children*. London: Mac Keith Press; 2005:479–97
65. Minns RA, Jones PA, Barlow KM. **Outcome and prognosis of non-accidental head injury in infants.** In: Minns RA, Brown JK, eds. *Shaking and Other Non-Accidental Head Injuries in Children*. London: Mac Keith Press; 2005:364–414
66. Lee KS, Doh JW, Bae HG, et al. **Relations among traumatic subdural lesions.** *J Korean Med Sci* 1996;11:55–63
67. Astrup T. **Assay and content of tissue thromboplastin in different organs.** *Thromb Diath Haemorrh* 1965;14:401–16
68. Kapila A, Trice J, Spies WG, et al. **Enlarged cerebrospinal fluid spaces in infants with subdural hematomas.** *Radiology* 1982;142: 669–72
69. Orrison WW, Robertson WC, Sackett JF. **Computerized tomography in chronic subdural hematomas (effusions) of infancy.** *Neuroradiology* 1978;16:79–81
70. Naffziger HC. **Subdural fluid accumulations following head injury.** *JAMA* 1924;82:1751–52
71. Todorow S, Happe M. **Traumatic subdural hygromas.** *Neurochirurgia (Stuttg)* 1981;24:131–36
72. Borzone M, Capuzzo T, Perria C, et al. **Traumatic subdural hygromas: a report of 70 surgically treated cases.** *J Neurosurg Sci* 1983;27:161–65
73. Kamezaki T, Yanaka K, Fujita K, et al. **Traumatic acute subdural hygroma mimicking acute subdural hematoma.** *J Clin Neurosci* 2004;11:311–13
74. Kristof RA, Grimm JM, Stoffel-Wagner B. **Cerebrospinal fluid leakage into the subdural space: possible influence on the pathogenesis and recurrence frequency of chronic subdural hematoma and subdural hygroma.** *J Neurosurg* 2008;108:275–80
75. Wetterling T, Demierre B, Rama B, et al. **Protein analysis of subdural hygroma fluid.** *Acta Neurochir (Wien)* 1988;91:79–82
76. Hoffmann GF, Trefz FK, Barth PG, et al. **Glutaryl-coenzyme A dehydrogenase deficiency: a distinct encephalopathy.** *Pediatrics* 1991; 88:1194–203
77. Osaka H, Kimura S, Nezu A, et al. **Chronic subdural hematoma, as an initial manifestation of glutaric aciduria type-1.** *Brain Dev* 1993;15:125–27
78. Drigo P, Burlina AB, Battistella PA. **Subdural hematoma and glutaric aciduria type 1.** *Brain Dev* 1993;15:460–61
79. Muntau AC, Röschinger W, Pfluger T, et al. **Subdurale hygrome und hämatome im säuglingsalter als initialmanifestation der glutarazidurie typ I.** *Monatsschr Kinderheilkd* 1997;145:646–51
80. Bishop FS, Liu JK, McCall TD, et al. **Glutaric aciduria type 1 presenting as bilateral subdural hematomas mimicking nonaccidental trauma. Case report and review of the literature.** *J Neurosurg* 2007;106(3 Suppl):222–26
81. Gelabert-González M, Fernández-Villa J, Cutrín-Prieto J, et al. **Arachnoid cyst rupture with subdural hygroma: report of three cases and literature review.** *Childs Nerv Syst* 2002;18:609–13
82. Kleinman PK, Barnes PD. **Head trauma.** In: Kleinman PK, ed. *Diagnostic Imaging of Child Abuse*. 2nd ed. St. Louis: Mosby; 1998:285–342
83. Goodell CL, Mealey J Jr. **Pathogenesis of chronic subdural hematoma. Experimental studies.** *Arch Neurol* 1963;8:429–37
84. Watanabe S, Shimada H, Ishii S. **Production of clinical form of chronic subdural hematoma in experimental animals.** *J Neurosurg* 1972;37:552–61
85. Poljaković Z, Petrusić I, Kalousek M, et al. **Correlative pathology of subdural hematoma with computerized tomography.** *Neurol Croat* 1991;41:21–32
86. Sargent S, Kennedy JG, Kaplan JA. **"Hyperacute" subdural hematoma: CT mimic of recurrent episodes of bleeding in the setting of child abuse.** *J Forensic Sci* 1996;41:314–16
87. Caré MM. **Neuroradiology.** In: Frasier L, Rauth-Farley K, Alexander R, et al, eds. *Abusive Head Trauma in Infants and Children–A Medical, Legal, and Forensic Reference*. St. Louis: G.W. Medical Publishing; 2006:73–98
88. Barnes PD, Krasnokutsky M. **Imaging of the central nervous system in suspected or alleged nonaccidental injury, including the mimics.** *Top Magn Reson Imaging* 2007;18:53–74
89. Walter T, Meissner C, Oehmichen M. **Pathomorphological staging of subdural hemorrhages: statistical analysis of post-traumatic histomorphological alterations.** *Leg Med (Tokyo)* 2009;11(Suppl 1):S56–62
90. Alper G, Ekinci G, Yilmaz Y, et al. **Magnetic resonance imaging characteristics of benign macrocephaly in children.** *J Child Neurol* 1999;14:678–82
91. Prassopoulos P, Cavouras D, Golfinopoulos S, et al. **The size of the intra- and extraventricular cerebrospinal fluid compartments in children with idiopathic benign widening of the frontal subarachnoid space.** *Neuroradiology* 1995;37:418–21
92. Briner S, Bodensteiner J. **Benign subdural collections of infancy.** *Pediatrics* 1981;67:802–04
93. Robertson WC Jr, Chun RW, Orrison WW, et al. **Benign subdural collections of infancy.** *J Pediatr* 1979;94:382–86
94. Hamza M, Bodensteiner JB, Noorani PA, et al. **Benign extracerebral fluid collections: a cause of macrocrania in infancy.** *Pediatr Neurol* 1987;3:218–21
95. Raul JS, Roth S, Ludes B, et al. **Influence of the benign enlargement of the subarachnoid space on the bridging veins strain during a shaking event: a finite element study.** *Int J Legal Med* 2008; 122:337–40
96. McNeely PD, Atkinson JD, Saigal G, et al. **Subdural hematomas in infants with benign enlargement of the subarachnoid spaces are not pathognomonic for child abuse.** *AJNR Am J Neuroradiol* 2006; 27:1725–28
97. Libicher M, Tröger J. **US measurement of the subarachnoid space in infants: normal values.** *Radiology* 1992;184:749–51
98. Dias MS, Backstrom J, Falk M, et al. **Serial radiography in the infant shaken impact syndrome.** *Pediatr Neurosurg* 1998;29:77–85
99. Vinchon M, Noulé N, Tchofo PJ, et al. **Imaging of head injuries in infants: temporal correlates and forensic implications for the diagnosis of child abuse.** *J Neurosurg* 2004;101:44–52
100. Bradford R, Choudhary AK, Dias MS. **Serial neuroimaging in infants with abusive head trauma: timing abusive injuries.** *J Neurosurg Pediatrics* 2013;12:110–19