

Are your **MRI contrast agents** cost-effective?

Learn more about generic **Gadolinium-Based Contrast Agents**.



**FRESENIUS
KABI**

caring for life

AJNR

**Transdural Blood Supply in Cerebral
Arteriovenous Malformations: A Systematic
Evaluation of Angioarchitecture**

K.-P. Stein, C. Moeninghoff, A. Kneist, I.E. Sandalcioglu,
M. Forsting and U. Sure

This information is current as
of April 18, 2024.

AJNR Am J Neuroradiol 2018, 39 (12) 2307-2312

doi: <https://doi.org/10.3174/ajnr.A5881>

<http://www.ajnr.org/content/39/12/2307>

Transdural Blood Supply in Cerebral Arteriovenous Malformations: A Systematic Evaluation of Angioarchitecture

 K.-P. Stein,  C. Moeninghoff,  A. Kneist,  I.E. Sandalcioglu,  M. Forsting, and  U. Sure

ABSTRACT

BACKGROUND AND PURPOSE: Arterial transdural blood supply is a rare angiographic phenomenon in cerebral AVMs. This study aimed to evaluate angiographic transdural blood supply characteristics and to describe the clinical peculiarities of these lesions.

MATERIALS AND METHODS: A prospective AVM data base of 535 patients, enrolled from 1990 to 2016, was analyzed retrospectively. Clinical information was reviewed through patients' medical charts and radiologic studies. Patients with previous AVM treatment were excluded ($n = 28$).

RESULTS: Patients with ($n = 32$, male/female ratio = 10:22; mean age, 46 ± 15 years; range, 13–75 years) and without transdural blood supply ($n = 475$, male/female ratio = 260:215; mean age, 40 ± 18 years; range, 2–87 years) did not show significant differences in clinical presentation (age, hemorrhage, seizures, chronic headache). The predominant nidus size in patients with transdural blood supply was ≥ 30 mm, with significantly more patients with large AVMs (>60 mm, $P = .001$). To describe the transdural blood supply, we used 3 grades based on the angiographic transdural blood supply proportion and intensity of AVM nidus perfusion (I–III). Fifty-seven percent of patients with chronic headache had a strong and substantial transdural nidus perfusion (III) and a high-flow transdural blood supply.

CONCLUSIONS: Cerebral AVMs with transdural blood supply represent a rare and heterogeneous subgroup. Lesions can be graded by quantifying the transdural blood supply of the nidus and by capturing hemodynamic characteristics. The broad spread of angiographic features and comparable clinical patterns of patients with or without transdural blood supply raises questions about the relevance of the transdural blood supply to the natural history risk of an AVM and the intention for treatment.

ABBREVIATIONS: ECA = external carotid artery; TDBS = transdural blood supply

Arterial transdural blood supply (TDBS) by branches of the external carotid artery (ECA) is an uncommon angiographic characteristic in cerebral AVMs. The rate of TDBS in AVMs is reported inconsistently. Previous reports described a prevalence of up to 50%, mainly due to preselection of patients or inclusion of distinct pathologies such as dural arteriovenous fistulas.^{1–3} In contrast, recent publications emphasized a prevalence of 7% and 6.6%, confirming the assumption of a rare phenomenon.^{4,5} Little is known about the impact of the TDBS on clinical presentation and biologic behavior, with only a few publications trying to capture the clinical and pathophysiologic aspects of these particular

AVMs.^{3,5,6} A systematic angiographic evaluation of TDBS characteristics so far has not been attempted, though transdural feeding patterns might influence surgical and endovascular treatment strategies.⁷ This study aims to systematically evaluate angiographic TDBS characteristics and to describe the clinical peculiarities of this rare subgroup among cerebral AVMs.

MATERIALS AND METHODS

A prospective data base of AVMs was examined, and a consecutive series of 535 patients, enrolled between 1990 and 2016, was analyzed retrospectively. Clinical information (basic demographic data, clinical presentation, vascular architecture) was reviewed through patients' medical charts and radiologic studies.

Because prior and partial AVM treatments potentially influence the natural course and formation of TDBS, patients with previous AVM treatment were not analyzed.⁶

Hemorrhage was defined as the acute onset of clinical and neurologic symptoms, combined with detection of blood on CT or MR imaging. Seizures and chronic headache were only as-

Received March 30, 2018; accepted after revision October 2.

From the Departments of Neurosurgery (K.-P.S., A.K., U.S.) and Diagnostic and Interventional Radiology and Neuroradiology (C.M., M.F.), University Hospital Essen, University Duisburg-Essen, Essen, Germany; and Department of Neurosurgery (K.-P.S., I.E.S.), Klinikum Region Hannover Hospital Nordstadt, Hannover, Germany. Please address correspondence to Klaus-Peter Stein, MD, Department of Neurosurgery, University Hospital Essen, University Duisburg-Essen, Hufelandstr 55, 45122 Essen, Germany; e-mail: Klaus-peter.stein@uk-essen.de

<http://dx.doi.org/10.3174/ajnr.A5881>

Table 1: Suggested grading of TDBS, depending on the proportion and intensity of nidus perfusion

	TDBS Grade		
	I	II	III
Proportion of nidus perfusion	Marginal (<5%)	Partial (5%–50%)	Substantial (>50%)
Intensity of nidus perfusion	Weak	Distinct	Strong

sumed to be predominant symptoms when unrelated to hemorrhage. Chronic headache was defined as ≥ 15 days/month for at least 3 months, following the International Classification of Headache Disorders.⁸ Thus, patients with sporadic headache or migraine were not incorporated in this subgroup. Patients with incidental lesions as well as patients with intermittent neurologic deficits or nonspecific symptoms leading to the diagnosis of the AVM were summarized in 1 group (Other).

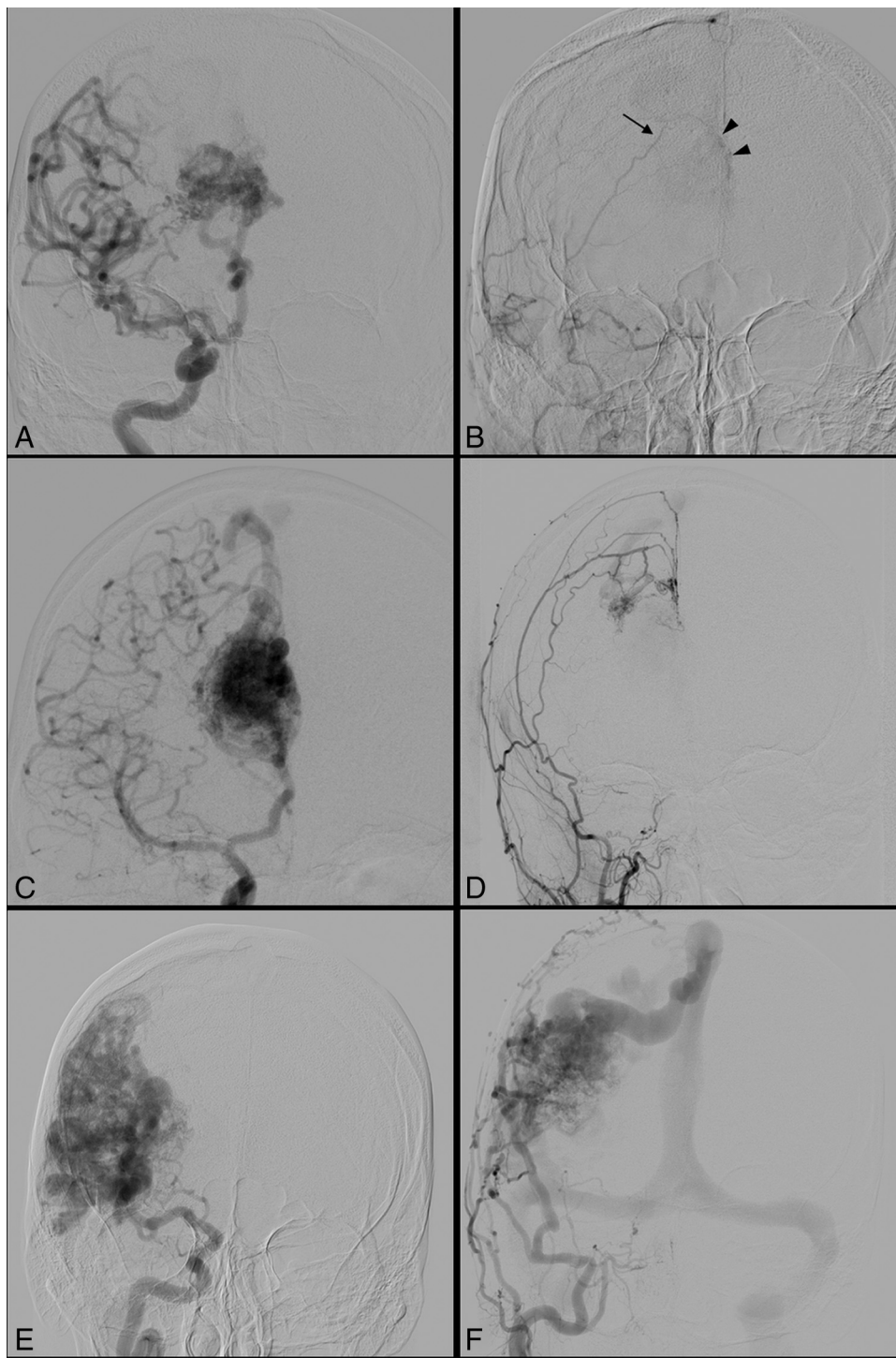


FIG 1. Representative angiograms of the 3 applied TDBS grades (left side ICA, right side ECA). A and B, TDBS I with weak and marginal contrast of the nidus (*arrowheads*) by a single meningeal feeder (*arrow*). C and D, TDBS II with distinct and partial ECA supply. E and F, TDBS III with a strong and substantial nidal filling from the ECA branches.

Table 2: Clinical presentation of 507 patients with cerebral AVMs

	TDBS (No.) (%)	No TDBS (No.) (%)	Multinomial Logistic Regression	
			P Value	Odds Ratio
All patients (<i>n</i> = 535)	39	496		
Previous AVM treatment	7 (18)	21 (4)		
Enrolled patients (<i>n</i> = 507)	32	475		
Male	10 (31)	260 (55)	.004	3.433
Hemorrhage	9 (28)	225 (47)	.3	0.968
Seizures	8 (25)	79 (17)	.4	1.672
Headache	7 (22)	44 (9)	.06	3.024
Other	8 (25)	127 (27)		
Age (<i>U</i> test) (yr)				
Mean	46 ± 14	40 ± 18	.07	
Range	13–75	2–87		

Table 3: Angiographic characteristics in 507 patients with cerebral AVMs

	TDBS (No.) (%)	No TDBS (No.) (%)	Multinomial Logistic Regression	
			P Value	Odds Ratio
All patients	32	475		
Location				
Supratentorial	27 (84)	399 (84)		
Infratentorial	5 (16)	76 (16)		
Size				
<30 mm	7 (22)	253 (53)	<.0001	117.703
>30–60 mm	17 (53)	199 (42)		
>60 mm	8 (25)	23 (5)	.001	16.852
Eloquence	24 (75)	252 (53)	.08	4.001
Venous drainage				
Deep	12 (38)	175 (37)	.2	2.268
Spetzler-Ponce class				
A	9 (28)	250 (53)	.04	0.042
B	13 (41)	137 (29)		
C	10 (31)	88 (18)	.03	0.099

Radiologic Evaluation

Depending on the clinical presentation and condition, patients were examined with CT and/or MR imaging followed by DSA. Following a standardized protocol, a complete angiography was performed (frame rate, 6 frames/s) with bilateral and selective injection into the vertebral artery, the internal carotid artery, and ECA on admission or before treatment. Radiologic findings were categorized following the guidelines from the Joint Writing Group for the Reporting Terminology for Brain Arteriovenous Malformation and Clinical and Radiographic Features for Use in Clinical Trials.⁹ AVMs were classified according to Spetzler and Ponce.¹⁰

To capture the heterogeneity of TDBS characteristics, we graded the proportion and intensity of AVM nidus perfusion, maintained by feeders of the ECA. Patients were divided into 3 groups following the distribution of angiographic peculiarities and adapting recently suggested thresholds to quantify interventional AVM embolization volumes (Table 1 and Fig 1).¹¹ In case of an overlap of different perfusion patterns or distinct feeding varieties in 1 individual, the following grade was applied. Furthermore, flow rates for both the ICA and ECA supply were classified as suggested by Koo et al.⁵ The flow rate was classified as high if the draining vein was seen at the same time or 1 frame after visualization of the nidus. A low flow was assumed if the draining vein was seen on/after frame 2. Special attention was directed to the predominant ECA feeders.

Statistical Analyses

All statistical analyses were performed using SPSS software (Version 22; IBM, Armonk, New York). Categorical data (clinical presentation, angiographic characteristics) were studied using a multinomial logistic regression analysis. Continuous data were analyzed using unpaired *U* tests (2-tailed) after examining the homogeneity of variances by means of the Levene test. A *P* value < .05 indicated statistical significance.

RESULTS

Patient Demographics and Clinical Presentation

The clinical characteristics of patients with and without TDBS are summarized in Table 2. Overall, 28 patients were excluded from further analysis due to prior AVM treatment. Treatment modalities in these cases included either radiation therapy (*n* = 13) or endovascular embolization (*n* = 5) or a combination of modalities, including partial surgical resection (*n* = 10). Among these patients, 12 individuals (TDBS, *n* = 3; no TDBS, *n* = 9) previously underwent proton beam therapy in the 1980s and early 1990s.

Angiographic Characteristics

Angiographic AVM characteristics are shown in Table 3. The predominant nidus size in patients with TDBS was ≥30 mm, with significantly more patients having large AVMs (>60 mm). Together with a high (though not statistically significant) number of eloquent locations, these large AVMs in this subgroup were classified Spetzler-Ponce class C in a substantial number of patients.

TDBS Grading

When we applied the suggested TDBS grading, 11 patients had a weak and marginal (I, 34%), 10 patients had a distinct and partial (II, 32%), and 11 patients had a strong and substantial (III, 34%) perfusion of the AVM nidus through feeders of the ECA. Due to the small number of cases, a statistical analysis was not performed. The distribution of clinical symptoms is shown in Fig 2.

The clinical presentation in relation to the nidal flow patterns is shown in Fig 3. Forty-seven percent (*n* = 15) of all patients had high-flow nidal perfusion, either by the ICA and/or ECA branches. Among those, 8 patients (25%) had a high-flow TDBS. Flow patterns in correlation to the suggested TDBS grading are shown in Fig 4.

Typing of ECA Supply

When we defined the predominant arterial ECA feeders, 3 phenotypes of TDBS could be identified (Fig 5):

Temple type (*n* = 21, 65%): mainly distinct feeders, including

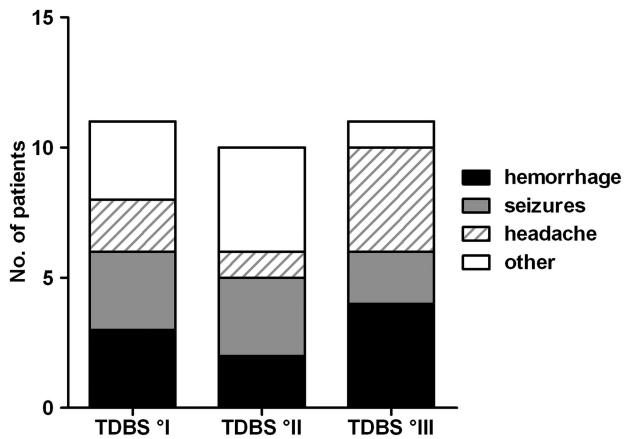


FIG 2. Clinical symptoms in 32 patients with TDBS according to the suggested grading.

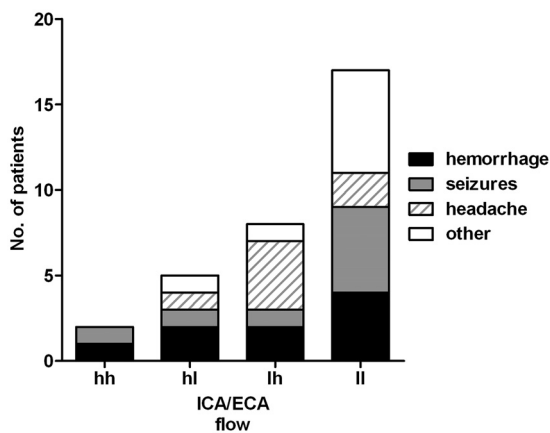


FIG 3. Clinical symptoms of 32 patients in relation to ICA/ECA flow patterns (low [l] versus high [h]).

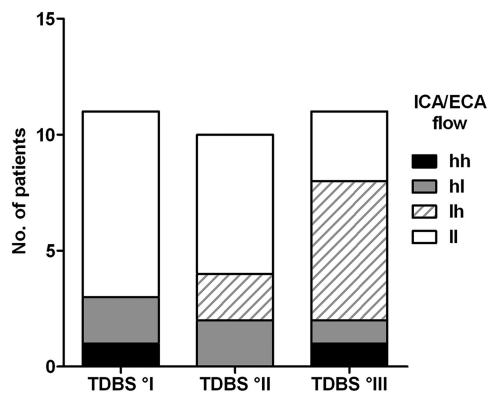


FIG 4. Flow patterns in 32 patients in correlation with the applied TDBS grading.

all branches of the middle meningeal artery (anterior and posterior branch) and the superficial temporal artery.

Occipital type ($n = 5$, 16%): including all branches of the occipital artery and the posterior auricular artery.

Transbasal type ($n = 6$, 19%): often diffuse, involving the terminal branches of the ECA and the facial artery, the maxillary artery, and the ascending pharyngeal artery, including the posterior meningeal artery.

The side of dural transition was always directly adjacent to the AVM nidus. In those cases of temple type TDBS, all AVMs had a nidus partially or in total involving the surface of the cerebral ($n = 20$) or cerebellar ($n = 1$) convexity. AVM nidi of the transbasal type were either located infratentorially ($n = 3$; brain stem, $n = 2$) or included those brain areas facing the temporal or frontal skull base ($n = 3$). Lesions with an occipital-type TDBS could be found superficially in the cerebellum ($n = 1$) or in the occipital and parietal lobes ($n = 4$). Most interesting, no primary TDBS from the anterior meningeal artery could be found in our cohort. The distribution of clinical symptoms within the 3 subtypes is shown in Fig 6.

DISCUSSION

TDBS Grading and Clinical Presentation

Our suggested grading represents a systematic analysis of angiographic characteristics in the subgroup of patients with brain AVMs with TDBS. Due to the immense heterogeneity of angiographic features and small numbers, we chose a descriptive semi-quantitative approach. The applied grading system, apart from quantitative capture, also considered hemodynamic aspects, which is illustrated in a high rate of high-flow ECA supply in patients with TDBS III (55%). Thus, certain aspects of the clinical presentation within these groups are remarkable:

1) We did not recognize a difference among these groups in terms of hemorrhagic presentation. In general, patients with or without TDBS had (statistically) comparable clinical patterns (age at first diagnosis, hemorrhage, seizures, chronic headache). These findings are different from those in previous reports, emphasizing higher rates of nonhemorrhagic symptoms and patients with TDBS being older.^{4,5} In contrast and as described in the literature, we likewise saw a significantly larger number of Spetzler-Ponce class B and C AVMs with TDBS as a logical consequence of predominantly large AVMs.^{4,5}

2) Fifty-seven percent of patients with chronic headache were graded TDBS III. Although well-recognized, the association of AVMs and nonhemorrhagic headache is poorly understood. Explanations for potential mechanisms include cerebral ischemia, increased intracranial pressure, cortical spreading depressions, and activation of trigeminovascular nerve afferents.¹² In case of AVMs with TDBS, meningeal irritation or cerebral hyperemia, due to additional ECA blood shunt volume, is likewise conceivable.

3) Fifty-seven percent of patients with chronic headache as chief symptom had a high-flow TDBS. These findings could underline the role of hemodynamics and shear stress across the meningeal transition zone.

Limitations of TDBS Grading

Mainly due to the immense number of angiographic varieties, the implementation of the applied TDBS grading was limited in several aspects: 1) Small and heterogeneous samples only allowed a descriptive approach. 2) The retrospective analysis of patients' radiologic studies prevented a volumetric determination of proportional nidus perfusion. 3) Dividing the groups descriptively into marginal/weak, partial/distinct, and substantial/strong certainly constituted an approximation of thresholds. 4) Our classi-

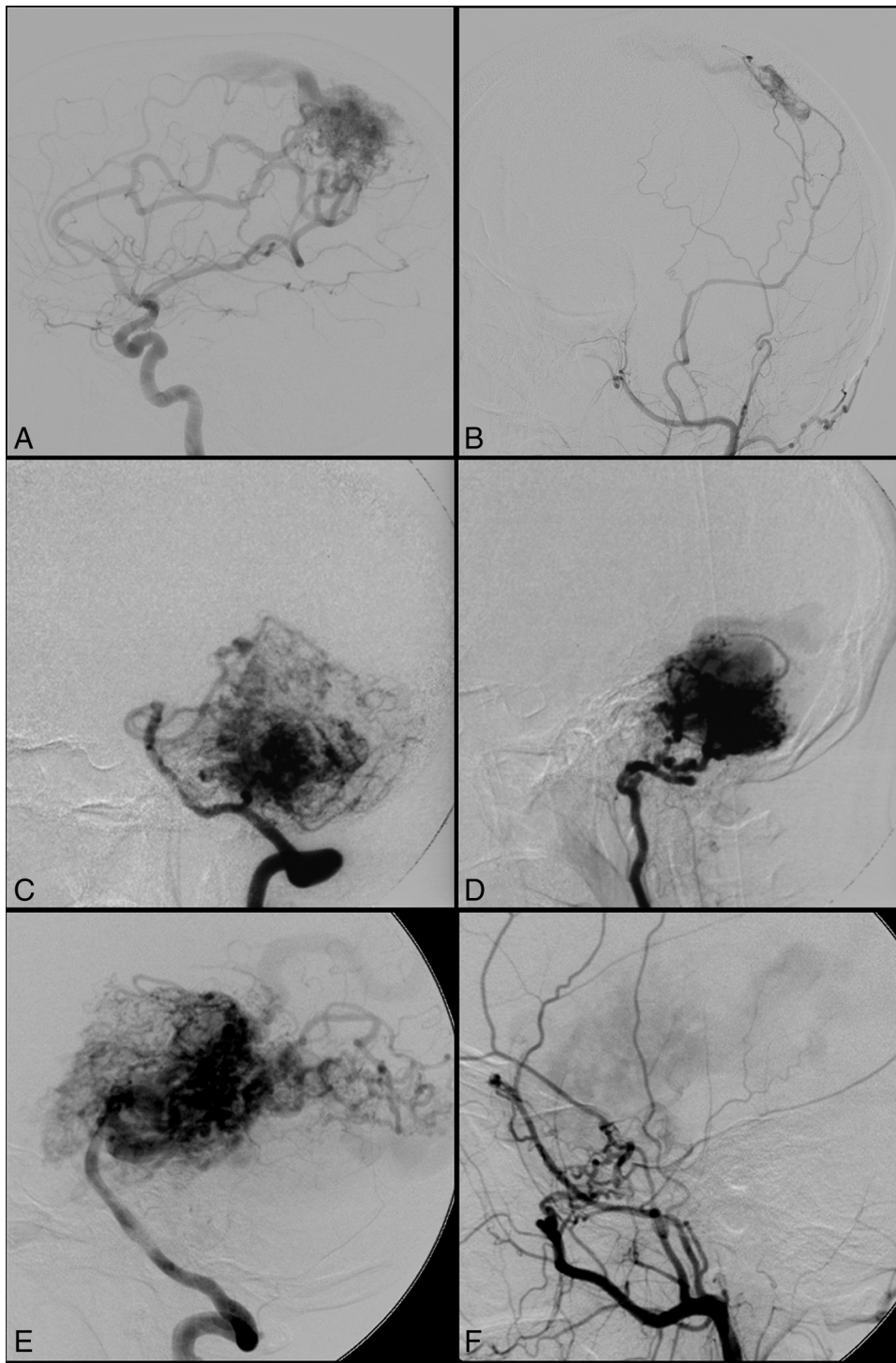


FIG 5. Representative angiograms of the 3 identified vascular phenotypes of TDBS (left side ICA, right side ECA). *A* and *B*, Temple type. *C* and *D*, Occipital type. *E* and *F*, Transbasal type.

fication did not capture every aspect of TDBS, such as the number of ECA feeders or an overlap of diverse vascular patterns within 1 individual, especially when multiple nidus compartments could be found.

Typing of ECA Supply

In all patients with TDBS, the dural transition zone directly adjoined the nidus of the AVM. Bervini et al⁴ previously described

this phenomenon. The same authors extensively discussed potential pathophysiologic mechanisms of TDBS formation, including increased angiogenesis, due to local hypoxia or wall shear stress, as well as ECA feeders developing from pre-existing small bridging arteries. We agree with the assumption of a multifactorial angiogenic genesis, which can be triggered by additional stimuli such as transarterial embolization or radiation therapy.^{6,13,14} The high rate of pretreated, though excluded, patients with TDBS in our

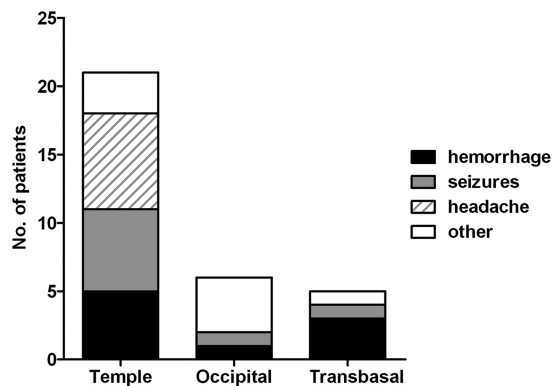


FIG 6. Clinical symptoms in 32 patients with TDBS, according to the 3 ECA phenotypes.

cohort underlines this assumption. Therefore, TDBS reflects a secondary vascular recruitment rather than a congenital vascular supply of the AVM.^{1,4}

In the same context, the described vascular phenotypes in our cohort more likely represent a property of anatomic location and neighborhood. Most patients (74%) with seizures were associated with the temple type because frontal, temporal, and parietal locations are known predictors of initial presentation of epilepsy.¹⁵ In contrast, chronic headache, often accompanying AVMs in the occipital lobe, was exclusively found within the temple type group (100%) and not within the occipital type group.^{15,16}

CONCLUSIONS

Cerebral AVMs with TDBS represent a rare and heterogeneous subgroup. Despite their immense variety of angiographic characteristics, these lesions can be graded by quantifying the ECA blood supply of the AVM nidus and by capturing hemodynamic properties. The broad spread of angiographic features and comparable clinical patterns of patients with or without TDBS raises questions about the relevance of TDBS to AVM natural history risk and the intention for treatment.

ACKNOWLEDGMENTS

The authors thank Mike Sucker for assistance in preparing the figures.

REFERENCES

- Miyachi S, Negoro M, Handa T, et al. **Contribution of meningeal arteries to cerebral arteriovenous malformations.** *Neuroradiology* 1993;35:205–09 CrossRef Medline
- Newton TH, Cronqvist S. **Involvement of dural arteries in intracranial arteriovenous malformations.** *Radiology* 1969;93:1071–78 CrossRef Medline
- Willinsky R, Lasjaunias P, Terbrugge K, et al. **Brain arteriovenous malformations: analysis of the angio-architecture in relationship to hemorrhage (based on 152 patients explored and/or treated at the hopital de Bicêtre between 1981 and 1986).** *J Neuroradiol* 1988; 15:225–37 Medline
- Bervini D, Morgan MK, Stoodley MA, et al. **Transdural arterial recruitment to brain arteriovenous malformation: clinical and management implications in a prospective cohort series.** *J Neurosurg* 2017;127:51–58 CrossRef Medline
- Koo HW, Jo KI, Yeon JY, et al. **Clinical features of superficially located brain arteriovenous malformations with transdural arterial communication.** *Cerebrovasc Dis* 2016;41:204–10 CrossRef Medline
- Söderman M, Rodesch G, Lasjaunias P. **Transdural blood supply to cerebral arteriovenous malformations adjacent to the dura mater.** *AJNR Am J Neuroradiol* 2002;23:1295–300 Medline
- Faria MA Jr, Fleischer AS. **Dual cerebral and meningeal supply to giant arteriovenous malformations of the posterior cerebral hemisphere.** *J Neurosurg* 1980;52:153–61 CrossRef Medline
- Headache Classification Committee of the International Headache Society (IHS). **The International Classification of Headache Disorders, 3rd edition (beta version).** *Cephalalgia* 2013;33:629–808 CrossRef Medline
- Atkinson RP, Awad IA, Batjer HH, et al; Joint Writing Group of the Technology Assessment Committee American Society of Interventional and Therapeutic Neuroradiology; Joint Section on Cerebrovascular Neurosurgery a Section of the American Association of Neurological Surgeons and Congress of Neurological Surgeons; Section of Stroke and the Section of Interventional Neurology of the American Academy of Neurology. **Reporting terminology for brain arteriovenous malformation clinical and radiographic features for use in clinical trials.** *Stroke* 2001;32:1430–42 CrossRef Medline
- Spetzler RF, Ponce FA. **A 3-tier classification of cerebral arteriovenous malformations: clinical article.** *J Neurosurg* 2011;114: 842–49 CrossRef Medline
- Rivera R, Sordo JG, Echeverria D, et al. **Quantitative evaluation of arteriovenous malformation hemodynamic changes after endovascular treatment using parametric color coding: a case series study.** *Interv Neuroradiol* 2017;23:650–55 CrossRef Medline
- Ellis JA, Mejia Munne JC, Lavine SD, et al. **Arteriovenous malformations and headache.** *J Clin Neurosci* 2016;23:38–43 CrossRef Medline
- Sandalcioglu IE, Asgari S, Wende D, et al. **Proliferation activity is significantly elevated in partially embolized cerebral arteriovenous malformations.** *Cerebrovasc Dis* 2010;30:396–401 CrossRef Medline
- Asgari S, Bassiouni H, Gizewski E, et al. **AVM resection after radiation therapy: clinico-morphological features and microsurgical results.** *Neurosurg Rev* 2010;33:53–61 CrossRef Medline
- Tong X, Wu J, Lin F, et al. **The effect of age, sex, and lesion location on initial presentation in patients with brain arteriovenous malformations.** *World Neurosurg* 2016;87:598–606 CrossRef Medline
- Rohn B, Hänggi D, Etminan N, et al. **Relief of epilepsy and headache and quality of life after microsurgical treatment of unruptured brain AVM-audit of a single-center series and comprehensive review of the literature.** *Neurosurg Rev* 2017;40:59–65 CrossRef Medline