

Are your MRI contrast agents cost-effective?

Learn more about generic Gadolinium-Based Contrast Agents.



FRESENIUS
KABI

caring for life

AJNR

Lymphographic-Like Technique for the Treatment of Microcystic Lymphatic Malformation Components of <3 mm

V. Da Ros, M. Iacobucci, F. Puccinelli, L. Spelle and G. Saliou

This information is current as of April 19, 2024.

AJNR Am J Neuroradiol 2018, 39 (2) 350-354

doi: <https://doi.org/10.3174/ajnr.A5449>

<http://www.ajnr.org/content/39/2/350>

Lymphographic-Like Technique for the Treatment of Microcystic Lymphatic Malformation Components of <3 mm

V. Da Ros, M. Iacobucci, F. Puccinelli, L. Spelle, and G. Saliou



ABSTRACT

BACKGROUND AND PURPOSE: The treatment of microcystic lymphatic malformations remains challenging. Our aim was to describe the lymphographic-like technique, a new technique of slow bleomycin infusion for the treatment of microcyst components of <3 mm, performed at our institution.

MATERIALS AND METHODS: A retrospective analysis of a prospectively collected lymphatic malformation data base was performed. Patients with at least 1 microcystic lymphatic malformation component demonstrated on MR imaging treated by lymphographic-like technique bleomycin infusion were included in the study. Patient interviews and MR imaging were performed to assess subjective and objective (microcystic lymphatic malformation size decrease of >30%) clinical improvement, respectively. Patients were reviewed 3 months after each sclerotherapy session. Lymphographic-like technique safety and efficacy were assessed.

RESULTS: Between January 2012 and July 2016, sixteen patients (5 males, 11 females; mean age, 15 years; range, 1–47 years) underwent the bleomycin lymphographic-like technique for microcystic lymphatic malformations. Sixty sclerotherapy sessions were performed, with a mean of 4 sessions per patient (range, 1–8 sessions) and a mean follow-up of 26 months (range, 5–58 months). We observed no major and 3 minor complications: 1 eyelid infection, 1 case of severe postprocedural nausea and vomiting, and 1 case of skin discoloration. One patient was lost to follow-up. Overall MR imaging objective improvement was observed in 5/16 (31%) patients; overall improvement of clinical symptoms was obtained in 93% of treated patients.

CONCLUSIONS: The bleomycin lymphographic-like technique for microcystic lymphatic malformations is safe and feasible with objective improvement in about one-third of patients. MR signal intensity changes after the lymphographic-like technique are associated with subjective improvement of the patient's symptoms.

ABBREVIATIONS: LM = lymphatic malformation; mLM = microcystic lymphatic malformation; LL-T = lymphographic-like technique

Lymphatic malformations (LMs) are congenital slow-flow vascular anomalies resulting from abnormal development of lymphatic vessels.¹ LMs can be solitary or multifocal and can be classified as macrocystic, microcystic (<1 cm), or combined lesions based on the size of the cysts. Some of the microcystic component is often characterized by multiple smaller cysts (<3 mm), in which direct puncture and selective hand injection cannot be attempted due to the size of the lesion. The bleomycin² sclerother-

apy technique is essentially reserved for macrocystic LMs, but in selected cases, successful results have also been observed for the treatment of the microcystic component.^{3,4}

We describe the bleomycin administration procedure used in our institution for the microcystic lymphatic malformation (mLM) component and the bleomycin safety profile. Preprocedural and postprocedural clinical data and MR imaging were used to objectively and subjectively demonstrate the efficacy of this procedure.

MATERIALS AND METHODS

This study was approved the Clinical Investigation Committee of Bicêtre Hospital, and patient informed consent was waived by this committee due to the retrospective observational nature of the study.

Diagnosis

The mLM component of LMs was diagnosed on the basis of clinical and imaging features by an interventional neuroradiologist

Received May 26, 2017; accepted after revision September 12.

From the Department of Neuroradiology (V.D.R., M.I., L.S., G.S.), Bicêtre Hospital, Le Kremlin Bicêtre Cedex, France; Department of Diagnostic Imaging and Interventional Radiology, Molecular Imaging and Radiotherapy (V.D.R.), Policlinico Tor Vergata, Rome, Italy; Department of Bioimaging and Radiological Sciences (M.I.), Policlinico "A. Gemelli," Rome, Italy; and Department of Neuroradiology (F.P., G.S.), Centre Hospitalier Universitaire Vaudois, Lausanne, Switzerland.

Please address correspondence to Guillaume Saliou, MD, Department of Radiology, Centre Hospitalier Universitaire Vaudois, Rue du Bugnon 46, CH-1011 Lausanne, Switzerland; e-mail: guillaume.saliou@chuv.ch

<http://dx.doi.org/10.3174/ajnr.A5449>

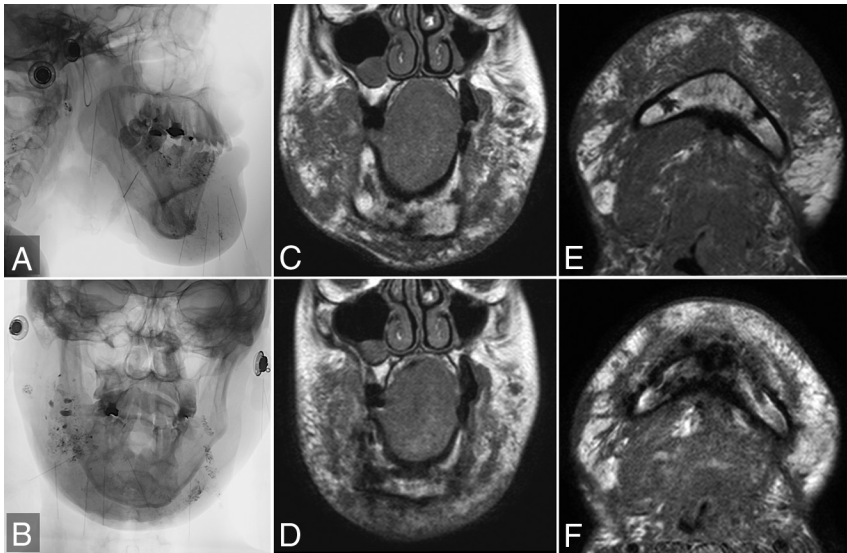


FIG 1. Lateral (A) and anteroposterior (B) plain radiography during a sclerotherapy session in a patient with a diffuse maxillofacial microcystic lymphatic malformation. She had been previously treated by an operation. Before sclerotherapy, on the T1-weighted coronal (C) and axial (E) views, the lymphatic malformation extended into the maxillofacial soft tissues, with multiple small diffuse hypointense microcystic lesions measuring <3 mm. No macrocyst was identified. After 7 sclerotherapy sessions and a cumulative dose of 90 mg of bleomycin, T1-weighted coronal (D) and axial (F) views demonstrate dramatic reduction in the size of the lymphatic malformation. However, soft tissues of the face remain thickened due to fat transformation (hyperintense) of the cysts.

and maxillofacial surgeon, in our weekly multidisciplinary clinic. The diagnostic criteria were clinical (including vesicular maculopapular lesions on the skin surface, a soft-tissue mass with a rubbery hard texture, oozing of lymphatic fluid and/or hemorrhagic fluid, and/or pain and tenderness) and MR imaging was used to assess the extent of the lesions and the dimensions of the cysts. When imaging and clinical features were not conclusive, surgical biopsy was planned to confirm the diagnosis. However, no pretreatment surgical biopsy was required in this patient series.

Lymphographic-Like Technique

All procedures were performed by the same operator (G.S.) under aseptic conditions with the patients under general anesthesia. The position of the 22-ga needles inserted into the lymphatic malformation was checked by fluoroscopic and sonographic guidance, especially in deep or small lesions. When blood reflux was observed in the needle, the position of the needle was modified. Because the microcysts in this series were very small (<3 mm), we did not wait for lymphatic fluid reflux in the needle. Four-to-8 needles inserted into the microcystic component of the lymphatic malformations were used in each session, depending on the volume of mixture available based on the patient's weight. Each needle was connected to a pump with a line comprising a dead space of about 1.8 mL. Bleomycin was diluted as follows: 15 mg of bleomycin in 5 mL of saline and 3 mL of contrast to obtain 8 mL of mixture. This total volume of 8 mL was injected at each session in adults. Because a dose of 0.5 mg/kg per session was injected in children weighing <35 kg, the volume of mixture was determined as follows: 8 mL of mixture every 30 kg of weight. Each line was then filled with 1 mL of mixture, and the remaining line dead space was filled with saline. In low-weight babies, when the total

volume of mixture was <4 mL, contrast medium diluted with saline (50%/50%) was added to obtain a volume of 4 mL to fill 4 syringes. A 10-cm-long gas bubble between the bleomycin mixture and the saline was used to avoid mixing the 2 solutions. Finally, the line was connected to a 10-mL electronic syringe pump filled with 1 mL of saline, and the infusion was administered at a flow rate of 0.7 mL/h. At the end of the injection, a low-dose CT scan was obtained to check diffusion of the mixture in the lymphatic malformation.

Posttreatment Care and Follow-Up

No compressive dressing was applied after completion of the sclerosant infusion. An intravenous infusion of 5 mg of dexamethasone sodium phosphate was routinely performed during the first hour after sclerotherapy to prevent excessive inflammation and its complications. The patient or family was instructed to evaluate sclerotherapy-related complications such as dermal discoloration, bleb formation, lymphedema, or necrosis occurring after discharge. Patients re-

turned to the radiology outpatient clinic 1 month later for assessment of any sclerotherapy-related complications. When no complications were observed, a 1-month interval was observed between the 2 bleomycin injection sessions; at 3 months from the first sclerotherapy, patients were asked to undergo a follow-up MR imaging.

The result of infusion sclerotherapy was initially assessed by 3-month follow-up T2- and T1-weighted sequences in axial and coronal views. On the initial MR images, retrieved from the PACS, anatomic landmarks were used to measure the target microcystic lesion. Soft-tissue thickness was measured from the dermal surface to an interface between the lesion and underlying structures such as the muscular fascia or bony cortex (Fig 1). Posttreatment objective MR imaging evaluations were classified as no change ($<10\%$ decrease in size), minor improvement (10%–30% decrease in size), and objective improvement ($>30\%$ decrease). Clinical results were based on both the physician's physical examination and patient interview. Clinical results were graded as follows: poor subjective response to treatment, good response (reduction of subjective symptoms without decrease in lesion size), and excellent results (reduction of subjective symptoms with a clinically evident decrease in lesion size). Moreover, evaluation of the clinical response was based on the physician's examination at 12 months and was designed to assess cosmetic improvement (decrease in lesion size $<10\%$, 10%–30%, and $>30\%$ on the physician's physical examination). Dysphagia was evaluated by the water test, and relief of pain and skin tension were assessed by the Faces Pain Scale. The decision to continue or discontinue treatment was based on this assessment.

We assessed the final result of infusion sclerotherapy at the

Objective and subjective clinical results

Patient No.	Sex	Age (yr)	Site	No. of Sessions	MRI Findings		Subjective Clinical Symptom Findings ^c
					% Decrease ^a	% Fat Transformations ^b	
1	M	5	Orbital	1	+	+	1
2	F	12	Maxillofacial	4	+	+	1
3	F	22	Tongue	7	+++	+++	2
4	F	8	Maxillofacial	2	+	+	1
5	F	24	Maxillofacial	8	+	+	1
6	F	32	Orbital	6	++	++	1
7	F	6	Orbital	2	++	No	0
8	F	23	Maxillofacial	1	NA	NA	NA
9	F	47	Tongue	7	++	++	1
10	M	5	Orbital	3	+++	+++	2
11	F	23	Orbital	2	+++	+++	2
12	M	1	Maxillofacial	4	+	++	1
13	F	2	Tongue	3	+++	+++	2
14	M	4	Orbital	2	+++	+++	2
15	F	8	Orbital	6	++	++	1
16	M	20	Maxillofacial	2	+	+	1

Note:—NA indicates not available.

^a% Decrease: + = 0–10, ++ = 10–30, +++ = >30.

^b% Fat transformation on T1WI and T2WI MRI: + = 0–10, ++ = 10–30, +++ = >30.

^cClinical evaluation: 0 = no improvement or progression, 1 = clinical improvement, 2 = resolution of symptoms.

vascular anomaly clinic on the basis of a multidisciplinary consensus during the patient's follow-up visits, considering the objective and subjective results at each visit.

No further sclerotherapy was recommended by multidisciplinary consensus in cases with signs of deterioration, indicating ineffective treatment.

The initial and last clinical and MR imaging findings were compared to validate the infusion sclerotherapy.

RESULTS

Between January 2012 and July 2016, sixteen consecutive patients (male/female ratio: 5:11; mean age, 15 years; range, 1–47 years) presented with at least 1 microcystic component of an LM and were treated by the lymphographic-like technique (LL-T). The anatomic sites of mLM were maxillofacial ($n = 6$), orbital ($n = 7$), and tongue ($n = 3$). The patients' symptoms comprised dermal lesions such as vesicular maculopapular lesions ($n = 7$), swelling ($n = 12$), pain ($n = 8$), and swallowing disorders ($n = 3$). Demographic and clinical data of all subjects are summarized in the Table.

Six of the 16 patients (38%) included in this study presented with multiple LMs with both macrocystic and microcystic components. Twelve microcystic components were classified as small/focal, and 4, as large/diffuse. The sites of these lesions were as follows: 6 lesions on the face, 3 intraoral lesions, and 7 orbital lesions.

Three lesions (19%) were treated to obtain cosmetic improvement, 6 (38%) were treated for swelling leading to oral obstruction and dysphagia, 9 (56%) were treated for swelling causing a mass effect, and 4 (25%) were treated because of pain and skin tension. Three (50%) of the lesions causing oral obstruction were also responsible for orthodontic problems secondary to LM enlargement. Five of the 16 patients (31%) had been treated for an LM before the review period: Two patients had undergone a previous operation, 2 patients had undergone previous alcohol sclerotherapy, and 1 patient had been previously treated by both an oper-

ation and alcohol sclerotherapy. These previous treatments had been performed a minimum of 2 years earlier.

Treatment Details and Complications

Sixty bleomycin LL-T sessions were performed in 16 patients. Each patient received a mean of 4 sclerotherapy sessions (range, 1–8). The microcystic component was accessible in every case, and a small "pop" experienced when crossing the microcyst was a marker of penetration of the target lesion.

The dose of bleomycin administered per session ranged from 2 to 15 U, with a mean dose of 10.5 U. The mean injection time was 90 minutes (range, 80–120 minutes). The mean follow-up was 26 months (range, 5–58 months). One patient was lost to follow-up after the first LL-T session.

Three of the 16 patients (19%) developed transient complications secondary to LL-T: One patient developed an orbital infection during hospitalization that resolved in response to oral antibiotics, 1 patient experienced severe nausea and vomiting that resolved with intravenous fluid administration, and 1 patient developed temporary skin discoloration over the injection site that lasted for 1 month and resolved without treatment.

Subjective End Points

At last follow-up, an excellent subjective clinical result was obtained in 5 (31%) of the 16 patients, a good clinical response was obtained in 9 (56%) of the 16 patients, and no response was obtained in 1 patient, though the lesions were improved.

Objective End Points

Objective improvement was observed on MR imaging for 5 (33%) of the 15 lesions (Fig 1), a minor decrease in size was observed for 4/15 lesions (27%), and no change in size was observed for 6/15 lesions (40%). No cases of deterioration were observed, but none of the mLMs were completely cured.

Although 14/15 patients (93%) reported subjective improvement at last follow-up, this improvement was associated with a significant reduction in the size of the mLM on MR imaging in only 5/15 cases (33%). An MR signal intensity change corresponding to fat transformation (T1- and T2-weighted hyperintensity) of the mLM treated by LL-T was observed in all 14 patients (100%) who reported a subjective clinical improvement at last follow-up (Table).

DISCUSSION

mLMs are less responsive to conventional percutaneous sclerotherapy techniques,⁵ mostly because the contractile lymphatic cisterns are situated more deeply in the subcutaneous tissue⁶ and due to the small dimensions of the cysts or channels (<2 cm).⁷ We describe a new bleomycin administration tech-

nique that provided encouraging results in safety and efficacy for the difficult treatment of the smaller (<3 mm) cystic components of mLMs.

The lymphographic-like technique, based on very slow bleomycin infusion, is designed to ensure uniform drug delivery to the lesion, to avoid early rupture or occlusion of small lymphatic channels. The slower infusion rate is achieved with an electronic syringe pump. The constant and slower infusion rate compared with manual injection allows deeper progression of the sclerosant through microchannels with a decreased risk of extravasation into the surrounding soft tissues. Compared with conventional manual injections, the lymphographic-like technique achieves higher concentrations and increased residence time of the sclerosant in the microcystic component, ensuring more efficient tissue inflammation.

A similar technique was recently described by Lee et al,⁸ with good results in safety and efficacy for the treatment of mLMs. However, picibanil (OK-432) was used in this study, and this agent is not currently available on the European market. Several other drugs or chemicals have been proposed for the treatment of mLMs.^{9–11} Doxycycline is the sclerosant most commonly used for the treatment of both macrocystic and microcystic LMs.¹² Doxycycline has demonstrated excellent results in macrocystic LMs but with significantly higher overall complication rates in the case of mLM lesions due to the higher doses of doxycycline required to achieve good results.¹ Very early trials of bleomycin sclerotherapy for LMs have been reported.¹³ Fatal complications such as pulmonary interstitial fibrosis or hypersensitivity^{14,15} have been described. However, no complications were observed when no more than 15 U in adults or 0.5 U/kg per session in children and a cumulative dose <90 U in adults or 6 sessions of 0.5 U/Kg in children were administered,^{4,16} confirming that bleomycin is a safe sclerosant agent.¹⁶ Because a considerable proportion (>60%) of the lesions treated in this series were localized in sensitive regions (ie, orbit and tongue), where even minimal lymphedema can cause a functional deficit, bleomycin was the best sclerosant for the lymphographic-like technique in view of its safety profile.

A few published studies have evaluated the objective response in the treatment of mLMs.¹⁷ Our results show that with an objective moderate decrease in lesion size, a subjective patient symptom improvement, described as a loss of skin tension sensation, was observed when mML fat transformation (T1- and T2- weighted hyperintensity) after LL-T was observed on MR imaging.

Our study has several limitations. First, it was a retrospective study based on a small cohort of patients and was not adequately powered because only patients with microcystic disease were included. Second, because clinical outcomes are commonly classified into relatively arbitrary categories, it is difficult to compare our results with this new bleomycin infusion technique with those of previously published studies. We did not use a specific imaging protocol; however, T1- and T2-weighted imaging was sufficient to demonstrate mLM fat transformation. The infusion technique and the sclerosant agent were adapted to the characteristics and sites of the lesions. This decision was primarily based on the operator's clinical experience. However, our findings confirm the

value of percutaneous bleomycin sclerotherapy for alleviation of the symptoms of craniofacial mLMs, with complication rates similar to those reported in previous studies.⁸ Nonetheless, a prospective study comparing bleomycin infusion with the lymphographic-like technique with other treatment modalities should be considered to provide more reliable data.

CONCLUSIONS

mLMs remain the most challenging form of lymphatic malformation, and new approaches to the management of these lesions must be developed. A new sclerotherapy technique for mLMs is proposed. The lymphographic-like technique was feasible and safe and effective for the treatment of small (<3 mm) microcystic components of LMs, with a favorable subjective outcome. More detailed guidelines must be established to ensure more extensive and safe application of this sclerosant administration technique. In addition, a prospective randomized trial should compare conventional treatment with this new sclerotherapy technique.

Disclosures: Laurent Spelle—UNRELATED: Consultancy: Stryker, Medtronic, MicroVention, Balt.

REFERENCES

1. Burrows PE, Mitri RK, Alomari A, et al. **Percutaneous sclerotherapy of lymphatic malformations with doxycycline.** *Lymphat Res Biol* 2008;6:209–16 Medline
2. Chaudry G, Burrows PE, Padua HM, et al. **Sclerotherapy of abdominal lymphatic malformations with doxycycline.** *J Vasc Interv Radiol* 2011;22:1431–35 CrossRef Medline
3. Bai Y, Jia J, Huang XX, et al. **Sclerotherapy of microcystic lymphatic malformations in oral and facial regions.** *J Oral Maxillofac Surg* 2009;67:251–56 CrossRef Medline
4. Chaudry G, Guevara CJ, Rialon KL, et al. **Safety and efficacy of bleomycin sclerotherapy for microcystic lymphatic malformation.** *Cardiovasc Intervent Radiol* 2014;37:1476–81 CrossRef Medline
5. Hogeling M, Adams S, Law J, et al. **Lymphatic malformations: clinical course and management in 64 cases.** *Australas J Dermatol* 2011; 52:186–90 CrossRef Medline
6. Whimster I. **The pathology of lymphangioma circumscriptum.** *Br J Dermatol* 1976;94:473–86 CrossRef Medline
7. Giguère CM, Bauman NM, Sato Y, et al. **Treatment of lymphangiomas with OK-432 (Picibanil) sclerotherapy: a prospective multi-institutional trial.** *Arch Otolaryngol Head Neck Surg* 2002;128: 1137–44 CrossRef Medline
8. Lee J, Lee SJ, Chung HY, et al. **Infusion sclerotherapy of microcystic lymphatic malformation: clinico-radiological mid-term results.** *J Korean Soc Radiol* 2016;74:26–36 CrossRef
9. Mathur NN, Rana I, Bothra R, et al. **Bleomycin sclerotherapy in congenital lymphatic and vascular malformations of head and neck.** *Int J Pediatr Otorhinolaryngol* 2005;69:75–80 CrossRef Medline
10. Nehra D, Jacobson L, Barnes P, et al. **Doxycycline sclerotherapy as primary treatment of head and neck lymphatic malformations in children.** *J Pediatr Surg* 2008;43:451–60 CrossRef Medline
11. Herbreteau D, Riche MC, Enjolras O, et al. **Percutaneous embolization with Ethibloc of lymphatic cystic malformations with a review of the experience in 70 patients.** *Int Angiol* 1993;12:34–39 Medline
12. Shergill A, John P, Amaral JG. **Doxycycline sclerotherapy in children with lymphatic malformations: outcomes, complications and clinical efficacy.** *Pediatr Radiol* 2012;42:1080–88 CrossRef Medline

13. Yura J, Hashimoto T, Tsuruga N, et al. **Bleomycin treatment for cystic hygroma in children.** *Nihon Geka Hokan* 1977;46:607–14 Medline
14. Levy RL, Chiarillo S. **Hyperpyrexia, allergic-type response and death occurring with low-dose bleomycin administration.** *Oncology* 1980;37:316–17 Medline
15. Sung MW, Chang SO, Choi JH, et al. **Bleomycin sclerotherapy in patients with congenital lymphatic malformation in the head and neck.** *Am J Otolaryngol* 1995;16:236–41 CrossRef Medline
16. Sainsbury DC, Kessell G, Fall AJ, et al. **Intralesional bleomycin injection treatment for vascular birthmarks: a 5-year experience at a single United Kingdom unit.** *Plast Reconstr Surg* 2011;127:2031–44 CrossRef Medline
17. Spence J, Krings T, terBrugge KG, et al. **Percutaneous sclerotherapy for facial venous malformations: subjective clinical and objective MR imaging follow-up results.** *AJNR Am J Neuroradiol* 2010;31:955–60 CrossRef Medline