

Are your **MRI contrast agents** cost-effective?

Learn more about generic **Gadolinium-Based Contrast Agents**.



FRESENIUS
KABI

caring for life

AJNR

Digital subtraction angiography of glomus tympanicum and jugulare tumors.

R F Carmody, J F Seeger, W W Horsley, J R Smith and R W Miller

AJNR Am J Neuroradiol 1983, 4 (3) 263-265

<http://www.ajnr.org/content/4/3/263>

This information is current as of April 20, 2024.

Digital Subtraction Angiography of Glomus Tympanicum and Jugulare Tumors

Raymond F. Carmody,¹ Joachim F. Seeger,¹ William W. Horsley,¹ Janice R. L. Smith,¹ and Roger W. Miller²

Radiologic procedures used to evaluate patients with suspected glomus tumor have included plain skull radiography, temporal bone tomography, computed tomography, and cerebral angiography. Of these, only angiography has proven reliable as a screening procedure for small glomus tympanicum and jugulare tumors. Digital subtraction angiography was used as the initial examination for suspected paraganglioma in 14 patients. Intravenous digital subtraction angiography proved to be an acceptable screening tool for these highly vascular tumors. Also, intraarterial digital subtraction angiography proved very satisfactory for mapping of tumor blood supply, which greatly simplified preoperative embolization. Effectiveness of therapy was readily ascertained by serial follow-up intravenous digital subtraction angiography.

Glomus tympanicum or jugulare tumors usually present clinically with pulsatile tinnitus, hearing loss, or lower cranial nerve deficit [1]. These lesions can often be detected by otoscopic examination, but the extent of the tumor usually cannot be predicted. Skull radiography and tomography are not effective for diagnosing small glomus tumors. Similarly, computed tomography (CT) is insensitive for small paragangliomas in the temporal region. Conventional selective cerebral angiography is a sensitive means of diagnosing glomus tumors, but is not a suitable screening procedure because of its risks and cost. For 2 years, we have screened possible glomus tumor suspects with digital subtraction angiography (DSA). This procedure can be performed safely on an outpatient basis, usually in less than 30 min.

Materials and Methods

Fourteen patients with suspected glomus tumor or with pulsatile tinnitus of unknown etiology were referred by the otolaryngology service for DSA examination. The technique of examination is as follows: A 5–6 French pigtail catheter is introduced into the superior vena cava. Forty ml of a 76% iodinated contrast medium is injected at a rate of 20–30 ml/sec. One or two images are obtained per second. The imaging sequence must be long enough to evaluate the venous sinuses.

Two projections are usually sufficient for screening purposes—a half-axial view (fig. 1) and an Arcelin (or Stenver) view (fig. 2). The Arcelin projection is especially helpful because it opens up the

genu of the petrous carotid artery and the distal sigmoid sinus. A slightly rotated lateral view to separate the petrous bones is an alternative projection. The common carotid bifurcation is included in the image to rule out an associated carotid or vagus body tumor.

Results

Thirteen patients who presented clinically with pulsatile tinnitus all had technically good or excellent intravenous DSA examinations. Five of these had negative physical examinations, no hearing loss, and normal DSA studies. Three patients with a red mass in the middle ear cavity and a fourth with severe external otitis had DSA findings typical of paraganglioma; namely, a hypervascular, intensely staining lesion in the temporal bone with early venous shunting. One of these was felt to be a glomus tympanicum lesion, and three had features of glomus jugulare tumors (fig. 3). One other patient who had a red mass in the middle ear cavity was thought to have a large glomus tympanicum tumor on the basis of the intravenous DSA study, the conventional angiogram, and the CT scan, but surgical exploration disclosed metastatic thyroid carcinoma to the petrous bone.

In a 30-year-old woman with a pulsating noise in her right ear, DSA showed a large right frontal lobe arteriovenous malformation. In a 71-year-old woman with pulsatile tinnitus that abated with mastoid compression, DSA showed an occluded distal jugular vein reconstituted by multiple collateral venous channels. This was believed to be the result of the use of a previous internal jugular vein central venous pressure catheter.

In a 31-year-old woman with pulsatile tinnitus but no abnormal physical findings, DSA showed a large jugular bulb on the afflicted side. This finding was of doubtful significance.

An 8-year-old boy had an otoscopic examination suggestive of a very small glomus tympanicum tumor. In order to maximize the likelihood of detecting a small vascular lesion, we elected to perform intraarterial rather than intravenous DSA (fig. 4). No angiographic abnormalities were seen. Surgical exploration disclosed a cholesterol granuloma on the tympanic membrane.

Discussion

Intravenous DSA has been shown to be an effective screening tool for certain intracranial vascular lesions [2, 3], and it is also

¹ Department of Radiology, Section of Neuroradiology, University of Arizona Health Sciences Center, Tucson, AZ 85724. Address reprint requests to R. F. Carmody.

² Department of Surgery, Section of Otolaryngology, University of Arizona Health Sciences Center, Tucson, AZ 85724.

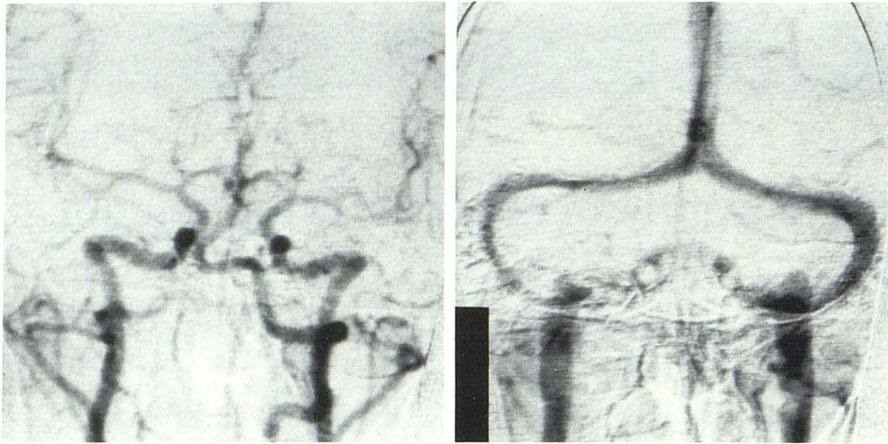


Fig. 1.—Normal intracranial intravenous DSA, anteroposterior Towne projection. Arterial (A) and venous (B) phases.

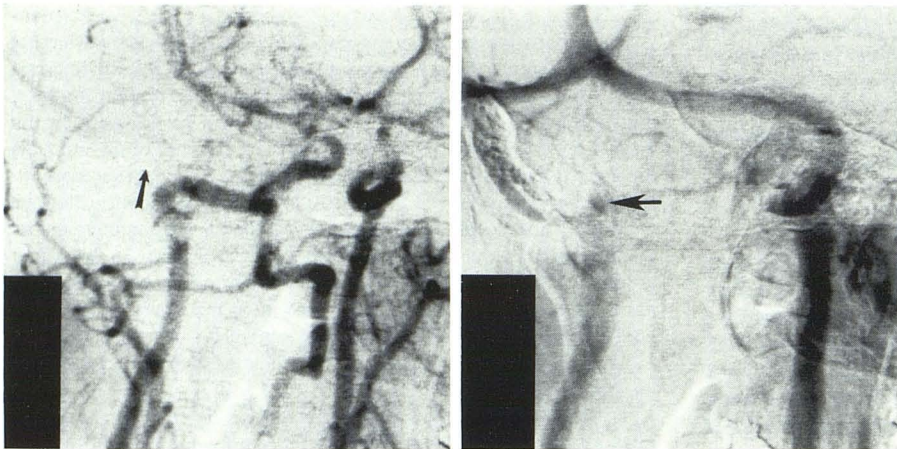


Fig. 2.—Normal intracranial intravenous DSA, Arcelin projection. A, Arterial phase. Region of middle ear cavity (arrow). B, Venous phase. Small right jugular bulb (arrow).

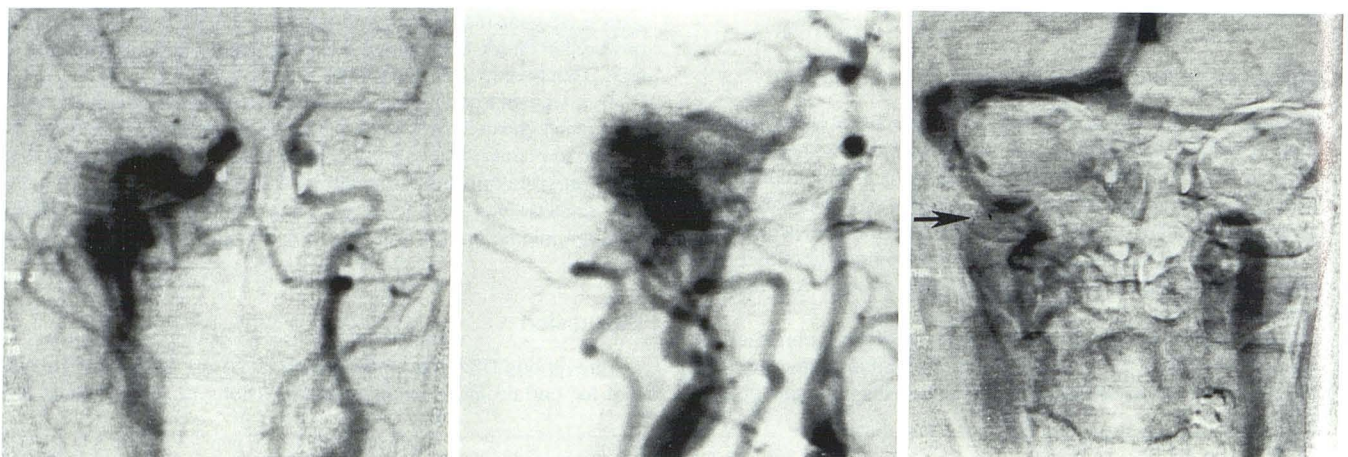


Fig. 3.—42-year-old woman with pulsatile tinnitus and hearing loss, right ear. Anteroposterior (A) and Arcelin (B) projections, arterial phase. Large hypervascular mass in right temporal bone. C, Anteroposterior projection, venous phase. Patency but compression of right internal jugular vein (arrow) due to large glomus jugulare tumor.

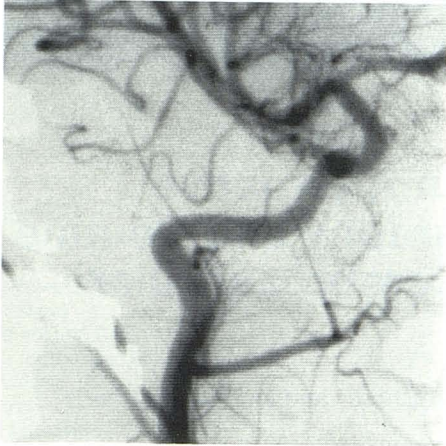

Fig. 4.—Normal intraarterial DSA, Arcelin projection. Vascular resolution approaches conventional angiography.

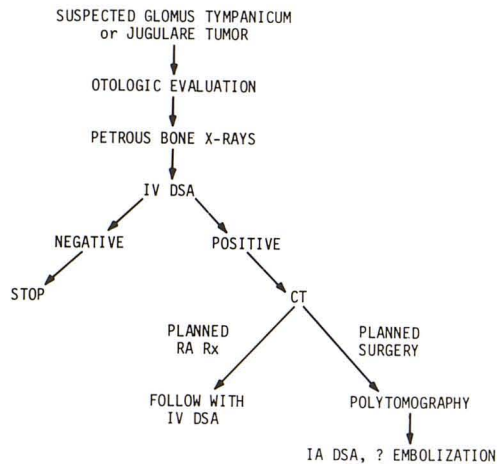


Fig. 5.—Protocol for evaluating patients with suspected glomus tumor. IV DSA = intravenous DSA; IA DSA = intraarterial DSA; RA Rx = radiation therapy.

proving to be useful in otolaryngologic radiology [4, 5]. With spatial resolution of 1–2 line pairs/mm, as well as excellent contrast resolution, DSA is an efficient means of screening patients with suspected paragangliomas of the head and neck.

Our protocol for the evaluation of the patient with a suspected glomus tumor is illustrated in figure 5. After the individual is seen

by an otologist and appropriate plain radiographs are obtained, we generally proceed directly with DSA. If the study is negative, the radiologic workup is terminated. If positive, high-resolution enhanced CT can be performed immediately after the DSA. CT can demonstrate both bone destruction and intracranial extension. Pluridirectional tomography, while currently still helpful in selected cases, may eventually be totally replaced by high-resolution CT scanning with multiplanar reformatting capability.

Following surgical and/or radiation therapy, the size and vascularity of the paraganglioma can be conveniently reevaluated by DSA. Two of our patients have had serial follow-up studies.

The use of digital fluoroscopy for intraarterial studies appears to provide consistently excellent images, even with half the usual doses of contrast material, with little loss of spatial resolution. Once a glomus tumor has been discovered or confirmed by intravenous DSA, intraarterial DSA can be done to define better the feeding vessels and angioarchitecture of the lesion. Intraarterial DSA also proved to be a very helpful adjunct to therapeutic embolization of these lesions in three of our cases. The availability of instantaneous subtraction images considerably shortens the catheter time for this procedure.

It is possible that some glomus tumors may have been missed by DSA in our series, but the quality of the images makes this seem unlikely. All patients with glomus tumors diagnosed by DSA subsequently had conventional angiography to "map out" tumor blood supply. Although conventional angiography defined the feeding vessels much more clearly, the appearance of the tumor stain was virtually identical in these two studies. We could not justify subjecting our patients to the risks of a conventional arteriogram merely to confirm negative DSA examinations.

To summarize, DSA is an efficient, safe, and cost-effective screening test for glomus tympanicum and jugulare tumors. Other vascular lesions that may present with pulsatile tinnitus, such as arteriovenous malformations, dural arteriovenous fistulae, ectatic carotid arteries, or aneurysms presenting in the middle ear cavity, should be detectable by this technique.

REFERENCES

1. Britton BH. Glomus tympanicum and glomus jugulare tumors. *Radiol Clin North Am* 1974;12:543–551
2. Modic MT, Weinstein MA, Chilcote WA, et al. Digital subtraction angiography of the intracranial vascular system: comparative study in 55 patients. *AJR* 1982;138:229–306
3. Carmody RF, Smith JRL, Seeger JF, Ovitt TW, Capp MP. Intracranial applications of digital intravenous subtraction angiography. *Radiology* 1982;144:529–534
4. Kinney SE, Modic MT, Weinstein MA, Starnes D, Duchesneau PM. Digital subtraction angiography of lesions of the head and neck. *Laryngoscope* 1982;92:557–561
5. Miller RW, Carmody RF, Seeger JF, Coulthard SW, Smith JRL, Koopman CF Jr. Digital subtraction angiography: applications in otolaryngology—head and neck surgery. *Head Neck Surg* 1983 (in press)