

Are your **MRI contrast agents** cost-effective?

Learn more about generic **Gadolinium-Based Contrast Agents**.



FRESENIUS  
KABI

caring for life

# AJNR

## **Elimination of metrizamide from the spinal subarachnoid space: a study of patients with abolished intracranial circulation.**

O P Eldevik

*AJNR Am J Neuroradiol* 1983, 4 (3) 585-587

<http://www.ajnr.org/content/4/3/585>

This information is current as of April 19, 2024.

# Elimination of Metrizamide from the Spinal Subarachnoid Space: A Study of Patients with Abolished Intracranial Circulation.

O. Petter Eldevik<sup>1</sup>

Two absorptive pathways for contrast media injected into the lumbar subarachnoid space have been postulated: (1) through the intracranial parasagittal arachnoid granulations and (2) direct absorption through the spinal arachnoid villi into the blood. To study the capacity of the spinal absorptive pathway, serial measurements of metrizamide concentrations in blood serum and urine were obtained before and after lumbar intrathecal injection of contrast medium in four patients with arrested intracranial blood circulation ("brain death") and intracranial pressure exceeding systolic blood pressure who had no circulation of cerebrospinal fluid from the spinal subarachnoid space to the parasagittal arachnoid granulations. These measurements indicated a high capacity of the spinal absorptive pathway for metrizamide elimination.

Scintigraphic imaging of intrathecal radionuclides [1] and cerebral computed tomographic (CT) imaging of myelographic contrast media [2, 3] suggest that transport of the radionuclide or the contrast medium is from the spinal subarachnoid space to the basal cisterns with elimination through the intracranial parasagittal pachionian granulations and arachnoid villi. However, measurements of contrast media transfer from cerebrospinal fluid (CSF) to blood in rabbits [4], monkeys [5], and humans [6, 7] have been interpreted as showing direct elimination of the contrast agent through spinal arachnoid villi and granulations. In order to determine whether a major portion of intrathecal water-soluble myelographic contrast medium is eliminated in patients via the intracranial route, metrizamide concentrations in serum and urine were compared after lumbar intrathecal injection in patients without intracranial blood circulation and in patients with a presumed normal intracranial circulation.

## Subjects and Methods

The elimination of metrizamide from the subarachnoid space was investigated in four patients declared dead after angiographically proven abolished intracranial blood circulation (group 1) and in three patients with sciatica (group 2).

Group 1 subjects had been accepted as kidney donors after three-vessel cerebral angiography had established cessation of intracranial blood circulation. The death certificates had been signed and consent to remove the kidneys had been obtained from the nearest relatives according to the requirements of Norwegian law. While arrangements for organ transplantation were being

made, cardiopulmonary and kidney functions were maintained according to the hospital routine in such cases. Lumbar myelography was performed during the 3–5 hr interval between death and transplantation.

Three patients in group 1 had died after head injuries sustained 1–5 days before the study. The other patient had died after rupture of an intracranial saccular aneurysm 10 days before the study. Diagnostic lumbar puncture had been performed in two patients 5 and 10 days, respectively, before death. Epidural intracranial pressure had been recorded in two patients and exceeded systolic blood pressure for 6 hr before death. Two patients developed diabetes insipidus and had been given intramuscular injections of vasopressin.

Lumbar puncture was performed with a 22 gauge spinal needle, avoiding multiple perforations of the dural sac. Lumbar CSF pressure was measured with a water manometer in reference to the spinal column. In three cases with initial CSF pressures of 20 cm water or more, removal of 1–3 ml of CSF reduced the pressure to 13 cm water. Ten ml of CSF was then withdrawn and 10 ml of metrizamide (170 mg I/ml) was injected intrathecally. The spinal needle was left in place during the study and the body was kept in the lateral decubitus position. Blood samples were drawn before injection of contrast medium, at 0.25, 0.5, 0.75, and 1.0 hr post-injection, and thereafter every 0.5 or 1.0 hr. Urine was collected hourly from an indwelling bladder catheter. Blood samples were centrifuged and serum was removed. Serum and urine samples were frozen for later analysis. Metrizamide concentrations in serum and urine were measured with high-performance liquid chromatography [8].

Group 2 subjects had had no previous myelograms, lumbar punctures, or spinal operations. They had no known neurologic abnormalities or disease except sciatica. Lumbar myelography was performed according to routine procedure [9]. Ten ml of CSF was withdrawn and 10 ml of metrizamide (170 mg I/ml) was injected intrathecally. The spinal needle was removed and films were obtained in prone and lateral positions. The conus medullaris was included in the examination by tilting the table to allow contrast medium to reach the lower thoracic region. After myelography, study subjects were placed in bed with the head elevated 15° from the horizontal. Blood samples were drawn via an antecubital vein catheter at the same intervals as in group 1. The catheter was filled with heparin (100 IU/ml) to prevent blood clotting between samplings. Subjects in group 2 were asked to empty the bladder before and every second hour after contrast medium injection. Blood and urine samples were frozen and analyzed as for group 1.

<sup>1</sup>Department of Neuroradiology, Ullevål Hospital, Oslo 1, Norway. Address reprint requests to O. P. Eldevik.

TABLE 1: Serial Serum Metrizamide Concentrations after Lumbar Intrathecal Injection of 10 ml Metrizamide (170 mg l/ml)

Group No.: Case No.	Metrizamide Concentration (mg/l)											
	Time Elapsed (hr) after Injection											
	0.25	0.50	0.75	1.0	1.5	2.0	2.5	3.0	3.5	4.0	5.0	6.0
1:												
1	4	7	8	10	...	14	...	17	...	13	20	...
2	0	0	0	2	15	24	18	10	11	4	...	...
3	37	65	77	82	92	93	79	92	...	84	...	...
4	2	4	7	11	...	13	...	11	...	...	...	...
2:												
5	0	5	14	16	...	29	...	31	...	38	...	25
6	8	16	19	19	...	13	...	16	21	...	...	31
7	14	25	44	43	...	47	...	35	...	37	...	48

Note.—Group 1 subjects were "brain-dead" cases with abolished intracranial blood circulation; group 2 subjects were sciatica patients with normal intracranial circulation.

## Results

Serial serum concentrations of metrizamide after lumbar intrathecal injection of contrast medium in all subjects in both groups are shown in table 1. Metrizamide was detectable in blood serum 0.25 hr after contrast medium injection in three of four cases in group 1 and in two of three cases in group 2. Peak serum metrizamide concentrations for individual subjects ranged from 13 mg/l to 93 mg/l in group 1 and from 31 mg/l to 48 mg/l in group 2. The time to peak serum metrizamide concentration was 2–5 hr for subjects in group 1 and 4–6 hr in group 2. Serial average serum concentrations for the two groups are shown graphically in figure 1.

The total amount of metrizamide excreted in the urine during the first 4 hr after intrathecal injection was 208 mg, 48 mg, and 857 mg, respectively, for cases 1, 2, and 3 in group 1. Case 4 excreted 152 mg of metrizamide in the urine during the first 3 hr. Group 2 subjects excreted 171 mg, 179 mg, and 191 mg of metrizamide, respectively, during the first 2 hr after myelography. One patient in group 2 excreted 961 mg of metrizamide in the urine during the first 4 hr after myelography, another patient excreted 1,204 mg of metrizamide during the first 8 hr after myelography, and the third patient failed to provide additional urine samples.

## Discussion

Side effects from myelography with water-soluble contrast media are probably proportional to the volume and concentration of contrast medium reaching the intracranial subarachnoid space [10]. Knowledge of the pathways for elimination of aqueous myelographic contrast media might be helpful in reducing the side effects of myelography. If there is a direct pathway of elimination from the lumbar subarachnoid space through the lumbar arachnoid membrane, reduction of side effects might best be achieved by maximal use of this lumbar pathway. Prevention of cephalad movement of the contrast medium by gravity would allow maximal absorption in the lumbar region.

Hindmarsh [11] found a correlation between the proportion of contrast medium circulating with the CSF and the molecular size of the contrast medium. He reported faster absorption of an agent with low molecular weight (MW) (methiodal, MW = 221) than of media with higher molecular weights (metrizamide, MW = 789; meglumine iocarmate, MW = 1646). Spinal arachnoid villi and granulations in embryo pigs and dogs were first described by Elman [12]. Kido et al. [13] studied human spinal arachnoid villi and granulations by dye perfusion in cadavers and demonstrated morphological similarities between spinal and cranial arachnoid villi and granulations. They concluded that spinal villi and granulations are an important pathway for CSF absorption.

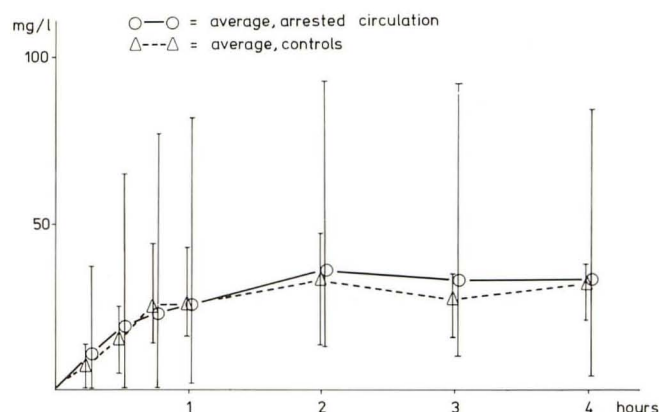


Fig. 1.—Serial average serum metrizamide concentrations after lumbar intrathecal injection of 10 ml metrizamide (170 mg l/ml) in two groups of subjects. Vertical lines indicate range within each group.

The precise manner in which arrested intracranial blood circulation and brain herniation affect spinal CSF physiology is unknown. With abolished intracranial blood circulation, communication between the spinal and cranial subarachnoid spaces is prevented and no CSF production or absorption can occur intracranially. Therefore, studies measuring the elimination of water-soluble contrast media from the spinal subarachnoid space in subjects with arrested intracranial circulation can provide data regarding the potential for direct spinal absorption of such agents. Such data do not show how contrast media are absorbed after ordinary clinical lumbar myelography but can certainly suggest whether contrast medium elimination takes place wholly or only partly by the intracranial route.

Defects in the arachnoid or dura secondary to lumbar puncture or trauma resulting in leakage may alter contrast medium elimination via the epidural veins of the intracranial cisterns [10]. In the present study, contrast medium leakage through a dural tear was unlikely in group 1 because there was no evidence of spinal fracture or dislocation in the four cases studied. Care was taken to avoid multiple perforations of the dura at the site of spinal puncture, and the spinal needle was left in place during the examination. Two of the cases in group 1 had had previous lumbar punctures but not within 5 days before death. The effect on the arachnoid of possible long-term elevated spinal CSF pressure prior to the study is unknown.

Direct absorption of contrast medium in the spinal region is indicated by the detection of metrizamide in blood serum at about the same rate in the two groups (fig. 1). Direct spinal elimination of metrizamide is also indicated by data from experimental myelogra-

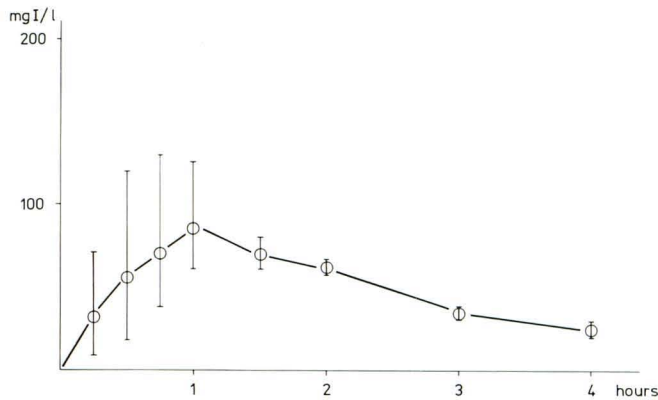


Fig. 2.—Serum metrizamide concentrations after lumbar intrathecal injection of metrizamide in three rabbits with cervical subarachnoid blockage. Vertical lines indicate range.

phy performed in animals (S. Salvesen, unpublished data). In these experiments the cervical subarachnoid space in three rabbits was blocked by injection of oil (Pantopaque) and metrizamide was injected into the lumbar subarachnoid space. Contrast medium appeared in serum at the same rate as in controls, with peak serum metrizamide concentrations occurring 1 hr after metrizamide injection (fig. 2).

The capacity of the spinal absorptive pathway is considerable, although it may vary among individuals, with variations probably depending on pressure gradients and the condition of the arachnoid membrane. Data from this study suggest that side effects of lumbar myelography with water-soluble contrast media may be reduced by techniques that encourage maximal use of the spinal absorptive pathway through reduction of cephalad flow of contrast medium by gravity. If care is employed in the myelographic procedure and the upper part of the body is elevated after myelography, most of the contrast medium can be collected in the caudal dural sac. However, the upright position may increase the likelihood of CSF leakage through the lumbar puncture hole. Nevertheless, Sykes et al. [14] reported a reduced incidence of adverse side effects after metrizamide myelography in ambulatory patients as compared with patients who remained in bed after myelography.

## REFERENCES

1. Di Chiro G. Observations on the circulation of the cerebrospinal fluid. *Acta Radiol [Diagn]* (Stockh) **1966**;5:988-1002
2. Hindmarsh T. Computer cisternography for evaluation of CSF flow dynamics. Further experiences. *Acta Radiol [Suppl]* (Stockh) **1977**;355:269-279
3. Enzmann DR, Norman D, Price DC, Newton TH. Metrizamide and radionuclide cisternography in communicating hydrocephalus. *Radiology* **1979**;130:681-686
4. Golman K, Wiik I, Salvesen S. Absorption of a nonionic contrast agent from cerebrospinal fluid to blood. *Neuroradiology* **1979**;18:227-233
5. Eldevik OP, Haughton VM, Sasse EA. Elimination of aqueous myelographic contrast media from the subarachnoid space. *Invest Radiol* **1980**;15:260-263
6. Golman K. Absorption of metrizamide from cerebrospinal fluid to blood: pharmacokinetics in humans. *J Pharm Sci* **1975**;64:405-407
7. Partain CL, Wu HP, Staab EV, Johnstone RE. A multiregional kinetics model for cerebrospinal fluid. *Radiology* **1978**;127:705-711
8. Jacobsen R, Børresen S. *High performance liquid chromatography (HPLC): a sensitive and selective method for contrast medium measurements*. Oslo, Norway: Nyegaard (in press)
9. Dugstad G, Eldevik OP. Lumbar myelography. *Acta Radiol [Suppl]* (Stockh) **1977**;355:17-29
10. Potts DG, Gomez DG, Abbott GF. Possible causes of complications of myelography with water-soluble contrast medium. *Acta Radiol [Suppl]* (Stockh) **1977**;355:390-401
11. Hindmarsh T. Elimination of water-soluble contrast media from the subarachnoid space. Investigation with computer tomography. *Acta Radiol [Suppl]* (Stockh) **1975**;346:45-50
12. Elman R. Spinal arachnoid granulations with especial reference to the cerebrospinal fluid. *Johns Hopkins Hosp Bull* **1923**;34:99-104
13. Kido DK, Gomez DG, Pavese AM, Potts DG. Human spinal arachnoid villi and granulations. *Neuroradiology* **1976**;11:221-228
14. Sykes RHD, Wasenar W, Clark P. Incidence of adverse effects following metrizamide myelography in nonambulatory and ambulatory patients. *Radiology* **1981**;138:625-627