

Are your **MRI contrast agents** cost-effective?

Learn more about generic **Gadolinium-Based Contrast Agents**.



FRESENIUS
KABI

caring for life

AJNR

Advantages of supplementary CT in myelography of intraspinal masses.

R Tadmor, E D Cacayorin and S A Kieffer

AJNR Am J Neuroradiol 1983, 4 (3) 618-621

<http://www.ajnr.org/content/4/3/618>

This information is current as
of April 17, 2024.

Advantages of Supplementary CT in Myelography of Intraspinal Masses

Rina Tadmor,¹ Edwin D. Cacayorin,² and Stephen A. Kieffer^{1, 2}

Computed tomographic (CT) myelography subsequent to non-ionic water-soluble contrast medium myelography has provided additional diagnostic information for evaluating intraspinal mass lesions. In 20 patients thus studied, there were eight intramedullary tumors, eight intradural extramedullary masses, and four extradural neoplasms. In intramedullary tumors CT enabled more precise delineation of the extent and location of expansion of the spinal cord. In intradural and extradural tumors, rotation and compression of the spinal cord as well as bony and paraspinal soft-tissue changes were more accurately demonstrated in the axial plane. When a complete block was present, the greater contrast sensitivity of CT permitted visualization beyond the level of the block. Histologic prediction is not feasible by CT myelography except for hyperlucent lipoma. CT can provide useful supplemental information to conventional metrizamide myelography.

Computed tomographic (CT) evaluation of the spine in spinal stenosis, herniated lumbar intervertebral disk, trauma to the vertebral column, and other bony pathology has been well established [1-3]. CT also permits accurate cross-sectional assessment of the spinal cord and nerve roots within the opacified thecal sac as well as the extradural soft tissues surrounding the sac [4]. CT myelography for the investigation of syringomyelia and of spinal dysraphism has added a further dimension to our understanding of these anomalies of the spine [5-7]. Application of CT for the detection and localization of intraspinal mass lesions has also been described [8-10]. This report analyzes our accumulated experience in the application of CT myelography to the evaluation of intraspinal mass lesions and emphasizes the supplementary information it may provide after conventional myelography with metrizamide.

Materials and Methods

Twenty patients ranging in age from 5 months to 65 years with clinical suspicion of an intraspinal mass lesion had plain radiographic studies of the spine and subsequently underwent conventional metrizamide myelography of that region. Volumes of metrizamide injected into the spinal subarachnoid space were 8-15 ml at concentrations of 170-200 mg l/ml. Within 1.5-2 hr after the intrathecal injection of contrast medium, CT examination of the area of interest was obtained. Patients with spinal dysraphism, syringomyelia, spinal stenosis, or herniated disk are not included in this

study. All masses were pathologically proven by surgical exploration and histologic verification.

The CT examinations were performed on Elscint Exel-905, Technicare 2020, and General Electric 8800 scanners. In most cases, a scan projection digital radiograph was first obtained which permitted rapid and accurate delineation of the area of interest; subsequent axial CT sections could then be made above, through, and below the lesion. Each study was tailored according to the

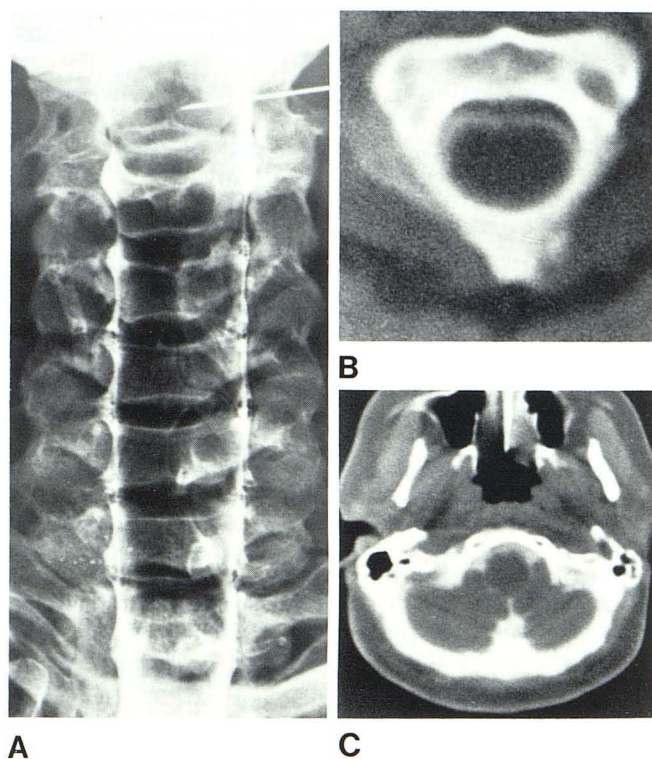


Fig. 1.—Intramedullary glioma with intracranial extension in 42-year-old woman. A, Cervical myelogram, anteroposterior view. Cervical spinal cord is diffusely enlarged from level of T2, but upper limit of cord widening is not delineated. B, CT myelogram at C2 level. Spinal cord is diffusely enlarged. C, At level of inferior medulla. Medulla is concentrically enlarged. Images obtained at higher levels demonstrated pons to be normal in size.

¹ Department of Radiology, Chaim Sheba Medical Center, Tel Hashomer, Israel, and Sackler School of Medicine, Tel Aviv University, Tel Aviv, Israel.

² Department of Radiology, State University of New York, Upstate Medical Center, Syracuse, NY 13210. Address reprint requests to S. A. Kieffer.

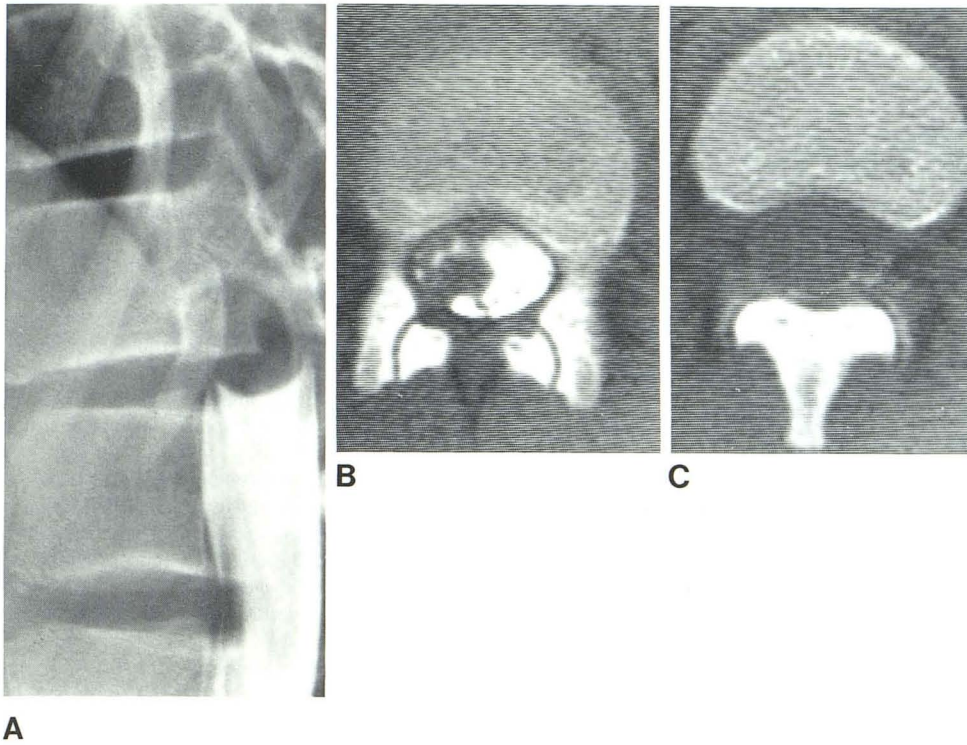


Fig. 2.—Intramedullary astrocytoma of conus medullaris in 13-year-old boy. **A**, Lumbar metrizamide myelogram, lateral view. Complete block with meniscuslike configuration of contrast column suggesting that mass may be intradural extramedullary in location. Note displacement of roots of cauda equina by mass. **B**, CT myelography at level of upper margin of L1. Inferior aspect of mass is eccentric in location and irregular and exophytic in configuration. Nerve roots lie ipsilateral and close to mass, which suggests that mass actually represents enlarged conus medullaris—extramedullary tumor would displace adjacent nerve roots to contralateral side of thecal sac. **C**, CT myelography at level of lower margin of T12. Enlarged conus medullaris virtually fills thecal sac.

extent of the tumor. The scanning techniques employed either a small scan circle (125 or 140 mm) or a large scan circle (420 mm) with image postprocessing confined to a smaller (125 mm diameter) region of the circle. Slice thickness was 5–8 mm. In many cases, overlapping of consecutive axial sections permitted subsequent image reconstructions in sagittal or coronal planes.

Results

In all 20 patients, the diagnosis of intraspinal mass was initially made by myelography, and CT myelography was performed subsequently. There were eight intramedullary tumors, eight intradural extramedullary masses, and four extradural neoplasms.

Four of the eight intramedullary lesions were located in the cervical area; CT myelography demonstrated intracranial extension along the neuraxis into the medulla and pons in all four patients. These included one glioma, one hemangioblastoma with a large cystic component, and two lipomas. Evaluation of intracranial extension by conventional metrizamide myelography was often not possible (fig. 1), either because of our reluctance to carry the contrast medium intracranially or because of apparent block to upward flow of the contrast bolus in the cervical region. In the region of the conus medullaris, axial CT myelography allowed definite diagnosis of spinal cord enlargement when conventional myelographic evaluation was equivocal. Histological prediction was possible only in the two cases of lipoma, which demonstrated negative attenuation coefficients.

The eight intradural extramedullary masses included two thoracic meningiomas, three neurofibromas, two patients with seed metastases, and one case of an intradural disk herniation presenting as a tumor. Differentiation between exophytic extension of intramedullary tumor and intradural extramedullary neoplasm was accomplished with CT myelography in one instance where conventional

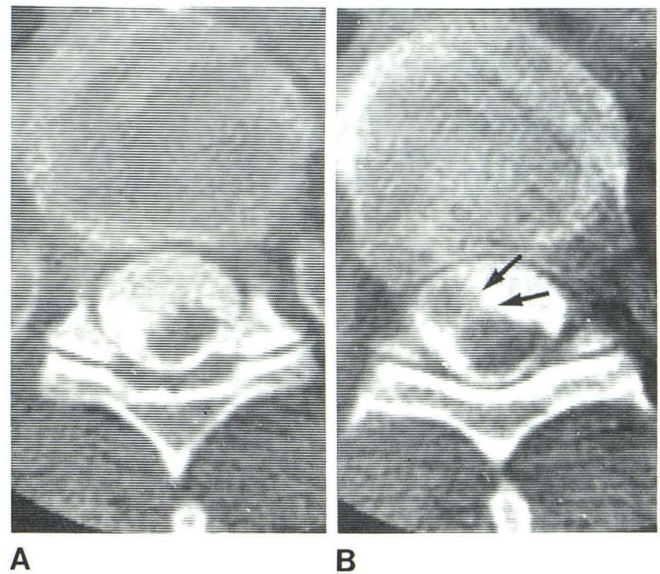


Fig. 3.—Thoracic meningioma in 69-year-old man. CT myelography. **A**, At T10 level. Spinal cord is located eccentrically on posterior aspect of thecal sac to left of midline. **B**, At T9 level. Lobulated intradural extramedullary mass (arrows) on right anteriorly displaces and compresses cord posteriorly and to left.

myelographic evaluation was equivocal (fig. 2). The effects of intradural extramedullary tumors on the adjacent spinal cord (rotation, deformity, displacement) were more clearly delineated on the sequential axial CT myelograms than on the conventional myelograms (fig. 3).

The four extradural lesions included two lymphomas and two

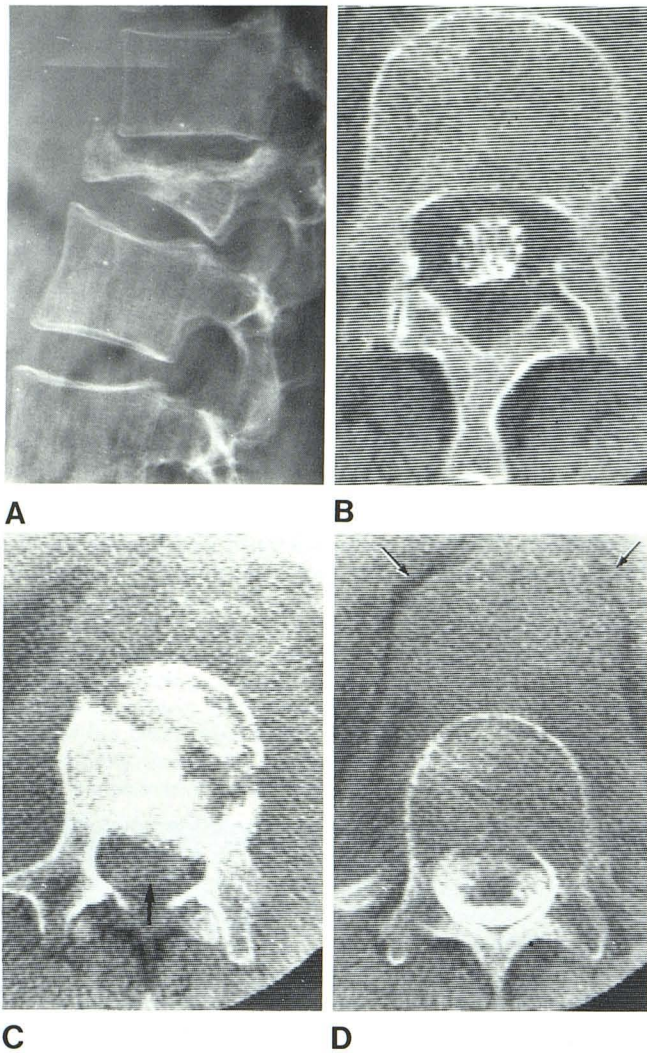


Fig. 4.—Extradural thoracolumbar lymphoma in 60-year-old man. **A**, Lateral radiograph showing severe compression and destruction of body of L1. **B**, CT myelography at L2. Opacified thecal sac is concentrically compressed by thickening of extradural soft tissues. **C**, At L1. Destruction with pathological fracture involving body of L1. Displaced posterior portion of vertebral body encroaches upon spinal canal. Thecal sac is severely compressed and barely recognizable (arrow). Conventional myelographic images demonstrated extradural block at this level. **D**, At T12. Extradural soft-tissue mass impinges upon anterior aspect of thecal sac which is opacified above level of apparent block. Also extensive soft-tissue mass surrounds external margins of vertebral body, bulges diaphragmatic crura (arrows), and obscures margins of aorta.

cases of carcinomatous metastasis. CT myelography delineated the extent and location of the thickened extradural space due to tumor infiltration more precisely than the conventional myelographic images. Extension of extradural neoplasm into adjacent osseous structures and prevertebral and paraspinous soft tissues was also demonstrated (fig. 4).

In instances of apparent complete block on conventional myelography, it was occasionally possible to establish the distal limit of intraspinal tumor extension by visualization of contrast opacification beyond the "block" on CT myelograms (fig. 4D). This was achieved in two patients in this series (one intramedullary metastasis, one extradural lymphoma), thus obviating a second myelogram with puncture above the level of the block.

Discussion

Myelography with nonionic water-soluble contrast medium is currently the accepted initial technique for detection and localization of intraspinal mass lesions. When properly performed, such examinations provide superior radiographic demonstration of the presence, location, and extent of space-occupying masses. However, postmyelography CT can provide additional diagnostic information which may enhance accuracy and obviate the need for further invasive examinations.

The additional information obtained from display in the axial plane regarding presence and degree of deformity, displacement, and rotation of the spinal cord and thecal sac may aid in characterization of the mass as intramedullary, intradural extramedullary, or extradural when conventional myelographic findings are equivocal. Axial CT myelographic images also provide improved appreciation of cord/tumor relations, which may aid in planning the surgical approach, biopsy, or resection.

Demonstration of cord enlargement or displacement by conventional myelography may prove difficult in two regions, the cervicomedullary junction and the conus medullaris, in which overlying bony structures obscure anatomic detail. Information provided by CT myelography in the axial plane is often sufficient to eliminate diagnostic uncertainty regarding presence and/or extent of a mass lesion in these areas.

CT myelography offers two further advantages as a supplemental and complementary examination to myelography. The superior contrast resolution may permit recognition of subarachnoid space opacification too faint to be recognized by conventional film-screen techniques. This has proven valuable in demonstrating that some apparent "complete" blocks to the flow of contrast medium are indeed incomplete, thus allowing delineation of tumor margins beyond the level of obstruction and obviating a second spinal puncture. Also, the demonstration by CT of involvement of adjacent osseous structures and soft tissues not only increases the understanding of degree of tumor extension but also may permit more accurate preoperative characterization of tumor type.

At the present stage of technologic development, state-of-the-art CT units lack sufficient contrast and spatial resolution to provide clear and reliable definition of the contents of most of the spinal canal without intrathecal introduction of contrast material [1, 11]. The spinal cord can be reliably demarcated on plain CT images only in the high cervical region (C1 and C2 levels) where the subarachnoid space is considerably larger than in the remainder of the spine. In the upper thoracic region, identification of the margins of the spinal cord on plain CT images was possible in only one-third of the cases in a consecutive nonselected series [12]. While intravenous injection of iodinated contrast medium results in enhancement of the normal extradural soft tissues and spinal dura as well as some large arteriovenous malformations and tumors [8, 13, 14], this opacification is by no means universal or clearly detectable within the resolution limits of current CT apparatus. Thus, it appears that CT myelography will continue to be the procedure of choice to supplement conventional myelography in providing accurate definition of the contents of the spinal canal in patients with suspected intraspinal mass lesions.

REFERENCES

1. Cacayorin ED, Kieffer SA. Applications and limitations of computed tomography of the spine. *Radiol Clin North Am* 1982;20:185-206
2. Harwood-Nash DC. Computed tomography of the pediatric spine: a protocol for the 1980s. *Radiol Clin North Am* 1981;19:479-494

3. Tadmor R, Davis KR, Roberson GH, New PFJ, Taveras JM. Computed tomographic evaluation of traumatic spinal injuries. *Radiology* **1978**;127:825-827
4. Di Chiro G, Schellinger D. Computed tomography of spinal cord after lumbar intrathecal introduction of metrizamide (computer assisted myelography). *Radiology* **1976**;120:101-104
5. Aubin ML, Vignaud J, Jardin C, Bar D. Computed tomography in 75 clinical cases of syringomyelia. *AJNR* **1981**;2:199-204
6. Resjo IM, Harwood-Nash DC, Fitz CR, Chuang SH. Computed tomographic metrizamide myelography in spinal dysraphism in infants and children. *J Comput Assist Tomogr* **1978**;2:549-558
7. Scotti G, Musgrave MA, Harwood-Nash DC, Fitz CR, Chuang SH. Diastematomyelia in children: metrizamide and CT metrizamide myelography. *AJNR* **1980**;1:403-410, *AJR* **1980**;135:1225-1232
8. Aubin ML, Jardin C, Bar D, Vignaud J. Computerized tomography in 32 cases of intraspinal tumor. *J Neuroradiol* **1979**;6:81-92
9. Resjo IM, Harwood-Nash DC, Fitz CR, Chuang SH. Computed tomographic metrizamide myelography (CTMM) in intraspinal and paraspinal neoplasms in infants and children. *AJR* **1979**;132:367-372
10. LaMasters DL, Watanabe TJ, Chambers EF, Norman D, Newton TH. Multiplanar metrizamide-enhanced CT imaging of the foramen magnum. *AJNR* **1982**;3:485-494
11. Haughton VM, Syvertsen A, Williams AL. Soft-tissue anatomy within the spinal canal as seen on computed tomography. *Radiology* **1980**;134:649-655
12. Taylor AJ, Haughton VM, Doust BD. CT imaging of the thoracic spinal cord without intrathecal contrast medium. *J Comput Assist Tomogr* **1980**;4:223-224
13. Di Chiro G, Doppman JL, Werner L. Computed tomography of spinal cord arteriovenous malformations. *Radiology* **1977**;123:351-354
14. Handel S, Grossman R, Sarwar M. Computed tomography in the diagnosis of spinal cord astrocytoma. *J Comput Assist Tomogr* **1978**;2:226-228