

Are your **MRI contrast agents** cost-effective?

Learn more about generic **Gadolinium-Based Contrast Agents**.



FRESENIUS  
KABI

caring for life

**AJNR**

**Cervical disk syndromes: value of metrizamide myelography and diskography.**

H Hartjes, K Roosen, W Grote, A Buch, A Brenner, K Ruhnau and H Hirche

*AJNR Am J Neuroradiol* 1983, 4 (3) 644-645

<http://www.ajnr.org/content/4/3/644>

This information is current as of April 19, 2024.

# Cervical Disk Syndromes: Value of Metrizamide Myelography and Diskography

Heinrich Hartjes,<sup>1</sup> Klaus Roosen,<sup>2</sup> Wilhelm Grote,<sup>2</sup> Anke Buch,<sup>2</sup> Ailke Brenner,<sup>2</sup> Kurt Ruhnau,<sup>2</sup> and Herbert Hirche<sup>3</sup>

**This paper reports on the respective diagnostic values of myelography with water-soluble contrast media and diskography in a study of 100 patients examined between 1979 and 1981 and operated on because of cervical disk disease. The results of the study led to a change of the diagnostic procedures formerly applied in radicular syndromes (i.e., diskography, and then perhaps myelography) and in cervical myelopathy (myelography, rarely followed by diskography). Now cervical metrizamide myelography is always performed first. Diskography is only indicated in radicular syndromes to determine the segment causing clinical symptoms when there is a polysegmental space-occupying lesion on the myelogram in combination with a mono- or oligoradicular neurologic symptomatology; or in the case of a normal myelogram with complaints resistant to conservative treatment.**

At the annual meeting of a neurosurgical society in 1979, a well known German neuroradiologist reported that since he had begun evaluating cervical myelopathy with metrizamide myelography, diskography had become obsolete. This precipitated a controversy about the values of the two methods in diagnosing cervical disk disease.

## Subjects and Methods

During a 2 year period, both metrizamide myelography and diskography were performed on 100 patients (31 women and 69 men). Diagnoses were later verified by surgery. All examinations were made with the MIMER III. Myelography was done in the prone position, diskography in the supine position, and standard procedures were followed. Myelography was done using metrizamide (300 mg I/ml), injected after a lateral puncture at C1-C2. Depending on the findings and the width of the spinal canal, 4-8 ml of contrast medium was administered [1-6]. The four standard projections could be completed by tomograms of the regions of interest. The contrast medium for diskography was diatrizoate, injected intradiskally under fluoroscopic control [7-12].

The methods were compared statistically using the Wilcoxon, Kruskal-Wallis, and Bonferoni-Holm tests, and the intensity of the cervical segment findings was classified into five levels. Level 1 was definitely positive; level 2, probably positive; level 3, dubious; level

4, probably negative; and level 5, definitely negative. Figure 1 and table 1 illustrate how this grading was applied for myelography and diskography.

## Results

In order to estimate the accuracy of the diagnosis and the significance of the myelographic appearance, anamnestic, radiographic, electromyographic, surgical, and pre- and postoperative neurologic data were assessed for each patient. The neurologic and clinical results up to 23 months after surgery were also considered.

We found that 68 patients suffered from only radicular disorder and 32 from cervical myelopathy. Groups I-VI were established as a result of the combination of normal, mono- or polysegmental findings by myelography and diskography (fig. 2). Except for group I all findings represented levels 1 and 2 of the grading scheme as demonstrated in figure 1 and table 1. As proved by surgery, the primary cause of complaints was a hernia of an intervertebral disk in 75% of the cases and cervical osteochondrosis in the other 25%.

### Groups I-VI: Radiculopathy

Our statistical findings suggest that diskography is not indicated for group III patients. We found no monosegmental myelographically positive findings that were either diskographically normal or showed further diskographically positive findings. In other words, the congruity between clinical and myelographic monosegmental findings makes diskography superfluous.

The myelogram showed normal findings in 10 cases of radicular syndromes. While a diskogram did not allow any statement for three of these patients, in seven it showed findings leading to surgery, which relieved the typical complaints. This information would have been missed if only myelographic diagnosis had been applied. Also, one has to realize that there may have been three false-negative diskograms in the three patients of group I.

Apart from radiculopathy, the myelographically polysegmental findings in group V (levels 1 and 2 of the grading scheme and stretching beyond the clinical signs) represent the second indication for diskography. Here, diskography can clear up the question (not always clinically determined), of which myelographic defect causes

<sup>1</sup>Department of Diagnostic Radiology, University Hospital, Essen, Hufelandstrasse 55, D-4300 Essen, West Germany. Address reprint requests to H. Hartjes.

<sup>2</sup>Department of Neurosurgery, University Hospital Essen, Essen, West Germany.

<sup>3</sup>Department of Biomathematics, University Hospital Essen, Essen, West Germany.



TABLE 1: Grading of Cervical Diskographic Findings

Grades	Criteria
1 and 2	Provocation of different clinical signs
3	Distinct deposition dorsal/lateral
4	Small deposition dorsal/lateral
5	Nucleus pulposus

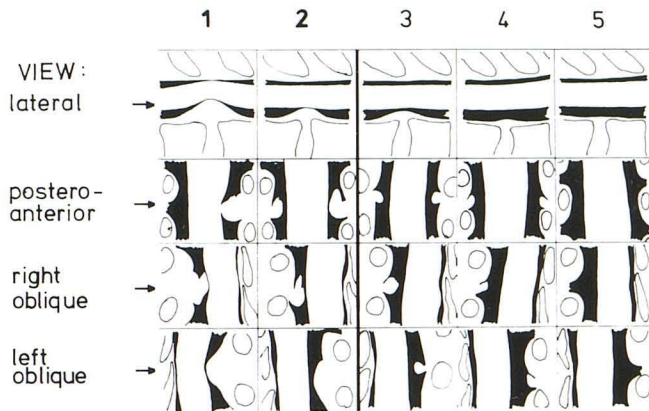


Fig. 1.—Sketch of myelographic cervical segment findings used in assigning patients to intensity levels 1-5.

Radiculopathy	RADIOLOGY		Cervical	M <sub>Myelopathy</sub>
3	I	M: normal D: normal	I	0
7	II	M: normal D: monosegmental	II	0
12	III	M: monosegmental D: monosegmental	III	5
17	IV	M: polysegmental D: normal	IV	10
23	V	M: polysegmental D: monosegmental	V	8
6	VI	M: polysegmental D: polysegmental	VI	9
<b>68</b>		M = Myelography D = Discography	<b>32</b>	

Fig. 2.—Summary of findings in 100 patients evaluated by both myelography and diskography.

the subjective clinical symptoms.

When diskography turns out to be negative in this group, there is an indication for a foraminotomy in the afflicted spaces. When there are positive diskographic findings in only one space (in 33.8% of the cases in this group), ventral fusion is advisable. The therapeutic decision will vary in cases of a polysegmentally positive diskogram.

Groups III-VI: Cervical Myelopathy

Myelography was never normal in the group of patients suffering from cervical myelopathy. Therefore there were no patients in groups I and II.

In the case of monosegmental compression of the cord by disk

herniation or by osteophytes, diskography did not provide additional therapeutically important information in any case. Also, diskography did not provide any new data that influenced surgical approach in cases of myelographically demonstrated multilevel cord compression. Diskography, therefore, usually is superfluous for clarifying cervical myelopathy.

Only one exception from this statement may be justified, and that is in the case of the myelographically complete block. Here, the diskogram shows clearly if there is a diskogenic or other lesion present, which is important preoperative information. If possible, computed tomography (CT) is preferable to diskography in these cases, as an increase of pressure in the disk space caused by diskography bears the risk of causing sudden deterioration in the patient's findings.

In conclusion, because of the optimal technical equipment available and the improved, detailed information metrizamide offers, myelography is the better method [3]. Diskography is used less frequently because of its risks, and should be used only for strict indications [12]. But it should by no means fall into oblivion. Its ability to provoke and mimic clinical complaints justifies the application of this method to locate the lesion responsible for the clinical signs: (1) when the myelogram turns out to be normal and does not reveal disk sequestra lying laterally and (2) when there are polysegmental protrusions that can be illustrated myelographically, and that exceed the clinical complaint.

Metrizamide has markedly improved myelography. It remains to be seen to what extent this will change because of spinal CT. According to our experience with all three methods we do not yet regard surgery for cervical compression syndromes justified solely on the basis of CT diagnosis.

REFERENCES

- Amundsen P. Metrizamide in cervical myelography. Survey and present state. *Acta Radiol [Suppl]* (Stockh) 1977;355:85-97
- Bradac GB, Kaernbach A. *Neue Aspekte in der Myelographie Erfahrungen mit Amipaque Technik-Ergebnisse-Grenzen*. Berlin: Schering, 1981
- Hartjes H, Roosen K. Diagnostische Probleme des engen cervicalen Spinalkanals. unter Berücksichtigung der Myelographie mit Amipaque. *Radiologe* 1982;22:45-50
- Kaplan JO, Quencer RM, Stokes NA, Post MJD. Improved technique for cervical metrizamide myelography. *Radiology* 1980;135:519-520
- Vogelsang H, Schmitt R, Busse O, Dangel U. Myelographie mit Metrizamide (Amipaque). *Acta Neurochir* (Wien) 1978;40:157-173
- Vogelsang H, Busse O, Schmidt R. Die cervikale Myelographie mit wasser-löslichem Kontrastmittel (Metrizamide). Technik und vorläufige Ergebnisse. *ROFO* 1976;125:225-228
- Bettag W, Grote W. Die Bedeutung der Diskographie für die Behandlung des "Zervikalsyndroms." *Hippokrates* 1969;40:138-141
- Cloward RB. Cervical discography. A contribution to the etiology and mechanism of neck, shoulder and arm pain. *Ann Surg* 1959;150:1052-1064
- Cloward RB. Cervical discography. *Acta Radiol [Diagn]* (Stockh) 1963;1:675-688
- Grote W, Wappenschmidt J. Über Technik und Indikationen zur zervikalen Discographie. *ROFO* 1967;106:721-727
- Hatt MU. Höhenlokalisierung der cervicalen Discushernie in Klinik, Elektromyographie und Myelographie. *Dtsch Zeitschr Nervenheilk* 1969;197:56-65
- Roosen K, Bettag W, Fiebach O. Komplikationen der cervicalen Diskographie. *ROFO* 1975;122:520-527