

Are your **MRI contrast agents** cost-effective?

Learn more about generic **Gadolinium-Based Contrast Agents**.



FRESENIUS
KABI

caring for life

AJNR

Serial Sonography of Posthemorrhagic Ventricular Dilatation and Porencephaly after Intracranial Hemorrhage in the Preterm Neonate

Arthur C. Fleischer, Alastair A. Hutchison, Albert L. Bundy, James E. Machin, Gary A. Thieme, Mildred T. Stahlman and A. Everette James, Jr.

This information is current as of April 20, 2024.

AJNR Am J Neuroradiol 1983, 4 (4) 971-975
<http://www.ajnr.org/content/4/4/971>

Serial Sonography of Posthemorrhagic Ventricular Dilatation and Porencephaly after Intracranial Hemorrhage in the Preterm Neonate

Arthur C. Fleischer¹
 Alastair A. Hutchison²
 Albert L. Bundy¹
 James E. Machin¹
 Gary A. Thieme¹
 Mildred T. Stahlman²
 A. Everette James, Jr.¹

Changes in ventricular size and brain parenchyma were documented in 40 preterm neonates with intracranial hemorrhage (ICH), who were serially examined for 3 weeks or more. Sonography disclosed a close relation between the severity of the intracranial hemorrhage and the development of progressive ventricular dilatation. Eighty percent of preterm neonates with minor degrees of intracranial hemorrhage (localized subependymal hemorrhage or subependymal hemorrhage with small intraventricular hemorrhage [subependymal/intraventricular hemorrhage]) did not develop significant ventricular dilatation, whereas all of the neonates with intraventricular and/or intraparenchymal hemorrhage developed moderate or severe ventricular dilatation. Spontaneous resolution of moderate and/or severe ventricular dilatation occurred by the end of the third week in about one-third of neonates with intracranial hemorrhage. Progressive ventricular dilatation was documented in 10 of 15 neonates with major intraventricular and/or intraparenchymal hemorrhage. The therapeutic implications of the findings are discussed.

The diagnostic accuracy of mechanical-sector, real-time sonography for the assessment of intracranial hemorrhage (ICH) in preterm neonates has been established [1-3]. However, the incidence and timing of the development of sequelae of ICH by this method have not been fully evaluated [4]. The purpose of this study was to document the chronologic sequence of changes in the ventricular system and brain parenchyma after ICH in the belief that the observations might be useful in the therapeutic management of affected neonates.

Subjects and Methods

During a 2 year period, 136 preterm neonates were serially examined with portable mechanical-sector real-time sonography. Only those neonates who weighed less than 2,000 g or were judged to be 34 weeks or less by gestational age assessment were included. There were 106 in-born and 30 out-born neonates.

This study had prior approval from the Committee on Protection of Human Subjects of Vanderbilt University Medical Center. If there were no clinical indications for serial cranial sonography, parental permission was obtained before inclusion of the patient in the study.

Sonographic examinations were performed with a mechanical-sector real-time device (Advanced Technology Labs., Bellevue, WA) with a 5.0 MHz transducer that was focused at 3-7 cm. Standard coronal and sagittal views were obtained through the anterior fontanelle; occasionally, the posterior fontanelle and temporal bone were used as imaging ports.

The scanning protocol consisted of three equally spaced sonographic examinations the first week of life, two during the second week, and one during the third and fourth weeks. For example, if a neonate were born on a Monday, sonography was performed on Monday, Wednesday, and Friday of the first week; Monday and Friday of the second; and Wednesdays of the third and fourth weeks. More scans were obtained as clinically indicated. To be included for data analysis, the neonate had to be scanned at least four times over a minimum of 3 weeks.

This article appears in the July/August 1983 issue of *AJNR* and the September 1983 issue of *AJR*.

Presented at the Third World Federation of Ultrasound in Medicine and Biology, Brighton, England, July 1982, and at the annual meeting of the American Roentgen Ray Society, Atlanta, April 1983.

This work was supported in part by Biomedical Support Research grant RR 05424-20.

¹ Department of Radiology and Radiological Sciences, Vanderbilt University Medical Center, Nashville, TN 37232. Address reprint requests to A. C. Fleischer.

² Department of Pediatrics, Vanderbilt University Medical Center, Nashville, TN 37232.

AJNR 4:971-975, July/August 1983
 0195-6108/83/0404-0971 \$00.00
 © American Roentgen Ray Society

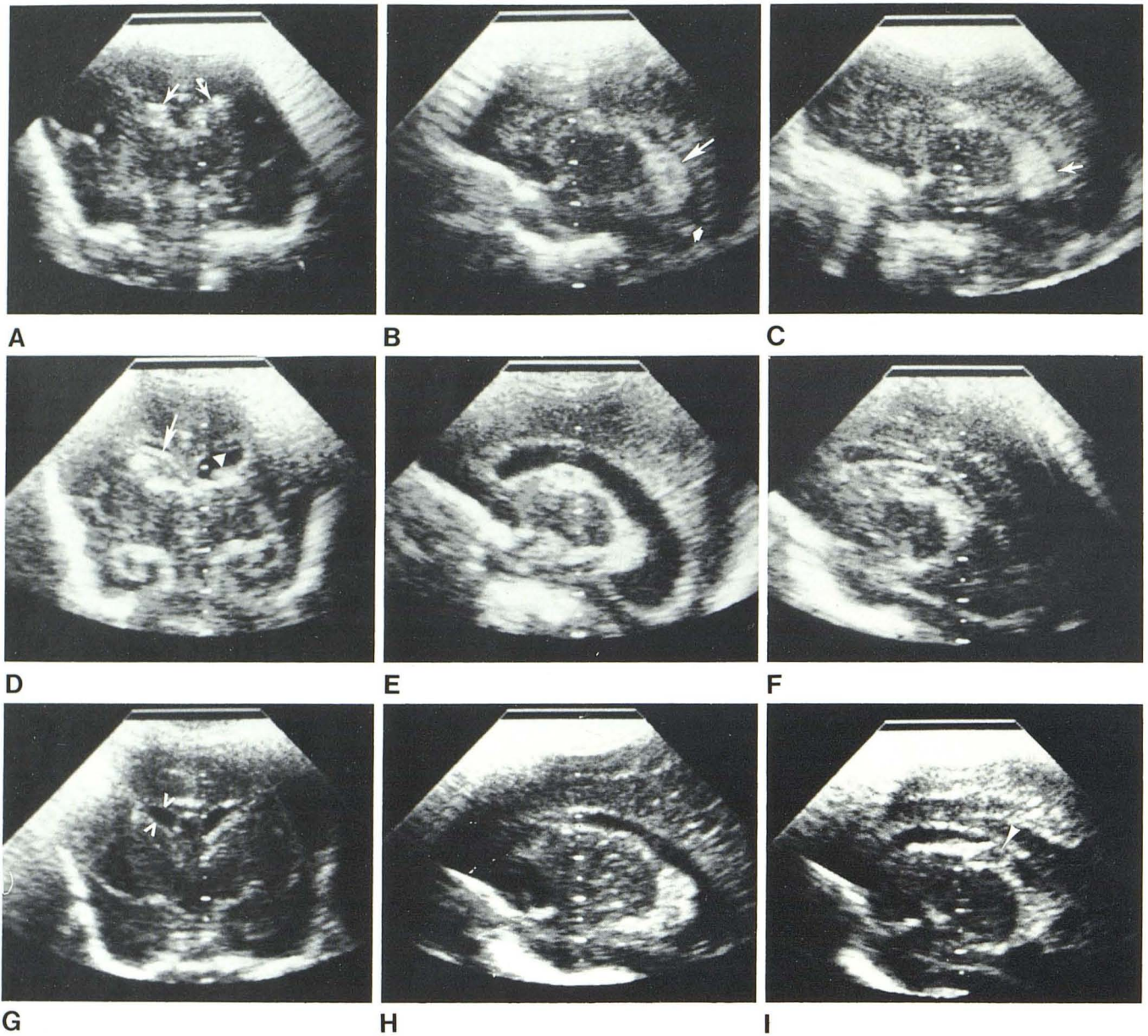


Fig. 1.—SEH/IVH leading to moderate ventricular dilatation with spontaneous resolution. A–C, Day 3. A, Coronal sonogram. Bilateral IVH (arrows) in lateral ventricles. Centimeter gradations are projected in center of image. B, Modified parasagittal sonogram. SEH/IVH (large arrow) with clot in right occipital horn (small arrow). C, Same as B on left showing SEH/IVH (arrow). D–F, Day 13. D, Coronal sonogram. Moderate dilatation, clot in right lateral ventricle (arrow) and left SEH (arrowhead). E, Modified sagittal sonogram.

Moderate dilatation of right lateral ventricle. F, Same as E for left lateral ventricle. G–I, Day 25. G, Coronal sonogram. Normal-sized lateral ventricles. Width of lateral ventricles between arrowheads was 3 mm. H, Modified parasagittal view of right lateral ventricle. I, Same as H of left lateral ventricle. Decreased echogenicity of subependymal hemorrhage (arrowhead) may be due to fibrinolysis of SEH.

Sonographic examinations were performed by two experienced sonologists (A. C. F. and J. E. M.). The sonograms were later collated and interpreted without clinical information by a staff sonologist (G. A. T.) and sonography fellow (A. L. B.). Standards for interpretation were set so as to have consistent data between the interpreters. Specifically, the size of the lateral ventricles was assessed in their greatest transverse width in the coronal plane at the level of the third ventricle [3] (fig. 1G). The details and rationale for using this method of measurement of the lateral ventricle have been reported by Sauerbrei et al. [3]. Among our patients, this method of measurement was found to be of sufficient consistency

since the hemisphere width of the neonates studied showed only minor variations (within 2 mm). The absolute size of the ventricles was determined by comparing the linear distance obtained with hand-held calipers to centimeter gradations projected on the image (fig. 1B). Alternately, the linear distance was compared with centimeter grid on a film of similar magnification (field-of-view). Ventricular dilatation was classified into mild (4–6 mm), moderate (7–10 mm), and severe (over 10 mm wide). Porencephaly was defined as fluid-filled spaces in areas of previous intraparenchymal hemorrhage (IPH).

The type of intracranial hemorrhage was described as follows:

subependymal hemorrhage (SEH)—hemorrhage localized to the subependymal germinal matrix; SEH/intraventricular hemorrhage (IVH)—SEH associated with a small or moderate amount of intraventricular hemorrhage; IVH—hemorrhage occupying over 50% of the ventricular lumen; and IPH—hemorrhage within the parenchyma of the brain. This classification of ICH was used because of its applicability to the sonographic features of the various types of ICH [5]. It does not include the presence, absence, or degree of associated ventricular dilatation included in the CT classification of ICH proposed by Burstein et al. [6].

Final grading was based on the most severe form of intracranial hemorrhage that was documented in a particular neonate. Progressive ventricular dilatation was defined as progressive enlargement of the ventricles beyond what is considered mild ventricular dilatation. Conversely, regression of ventricular dilatation was considered to be present when the ventricles decreased from severe to moderate, moderate to mild, or mild to normal. Stable ventricular dilatation was defined when the ventricles remained dilated over a minimum of 2 weeks once mild dilatation was present.

One hundred and thirty-six neonates were serially examined with each neonate having an average of seven studies (range, four to 18) over an average of 36.5 days (range, 20–97 days). Of the 136 neonates serially examined, 40 (29.4%) had evidence of ICH. We retrospectively analyzed 256 cranial sonograms from these 40 patients. Of these 40 neonates, eight underwent serial ventricular aspirations.

The gestational age of the affected neonates averaged 29.8 weeks (range, 26–34 weeks). Birthweights of the neonates with ICH averaged 1,210 (range, 600–1,660).

Results

Although there was no statistically significant correlation between the presence of ICH and the gestational age and birth weight of the neonate, there was a general tendency for the more severe forms of ICH to occur in neonates of lowest birth weight and gestational age. The types and course of intracranial hemorrhage are summarized in table 1. Eighteen of 19 neonates with SEH (18 of 19) did not develop significant ventricular dilatation, whereas 11 of 12 with SEH/IVH or IVH had moderate ventricular dilatation. Severe dilatation developed in six of nine patients with IPH. Of the neonates who developed moderate ventricular dilatation, four of 14 demonstrated spontaneous diminution in ventricular size (figs. 1A–1I); two after serial ventricular aspirations. Progressive dilatation occurred in four of six with IVH and in six of nine with IPH (figs. 2A–2C). Thus, progressive dilatation developed in 10 (66%) of 15 neonates with the more severe form of ICH. Ten neonates demonstrated progressive dilatation despite serial ventricular aspirations in five (table 1).

Table 2 summarizes data concerning the approximate time of each sequela after an ICH has occurred. Since the examinations were not performed daily, these numbers are only approximate. SEH tended to occur in the latter half of the first week of life, and mild dilatation typically occurred within the following week. Moderate ventricular dilatation was documented in patients with IVH during the second week, whereas severe dilatation occurred in the third week of life. Diminution in ventricular size after IVH typically occurred near the end of the second week after ICH. The

TABLE 1: Ventricular Dilatation Correlated with Type of Intracranial Hemorrhage

Type of ICH: Degree of Ventricular Dilatation	No. Patients
Subependymal:	
None → stable	8
Mild → stable	4
Mild → ↓	6
Moderate → stable	1
Subtotal	19
Subependymal/intraventricular:	
Mild → stable	2
Moderate → stable	2
Moderate → ↓	2
Subtotal	6
Intraventricular:	
Moderate → stable	2 (1)
Moderate → severe → ↓	2
Moderate → severe → stable	2 (1)
Subtotal	6
Intraparenchymal:	
Moderate + porencephaly → ↓	2 (2)
Moderate + porencephaly → stable	1
Severe + porencephaly → stable	6 (4)
Subtotal	9
Total	40

Note.—ICH = intracranial hemorrhage. Arrows reflect progression of dilatation. Numbers in parentheses represent patients who had serial ventricular aspirations.

development of IPH typically occurred during the first week of life, with porencephaly developing at the end of the first month.

Discussion

The development of progressive ventricular dilatation and porencephaly depends on the extent and type of ICH. Specifically, most neonates with localized SEH did not develop significant ventricular dilatation on serial examination. On the other hand, neonates who had IPH and IVH typically progressed to severe ventricular dilatation and porencephaly. Between these two extremes, the development of moderate or severe ventricular dilatation most often occurred when extensive IVH was present.

The major emphasis of current therapy for ventricular dilatation and porencephaly after ICH is aimed at minimizing the deleterious effect of compression and ischemia of brain parenchyma. Our study indicates that the chance of developing progressive ventricular dilatation after ICH is clearly related to the extent of ICH. Localized SEH/IVH tends to resolve, whereas extensive IVH and IPH are frequently associated with progressive ventricular dilatation. Once moderate or severe ventricular dilatation has developed, it may spontaneously resolve over a period of 2½–3 weeks in one-third of affected neonates. Of the other two-thirds with IVH and moderate or severe ventricular dilatation, half will remain unchanged, whereas half will develop progressive ventricular dilatation. The probability that ventricular dilata-

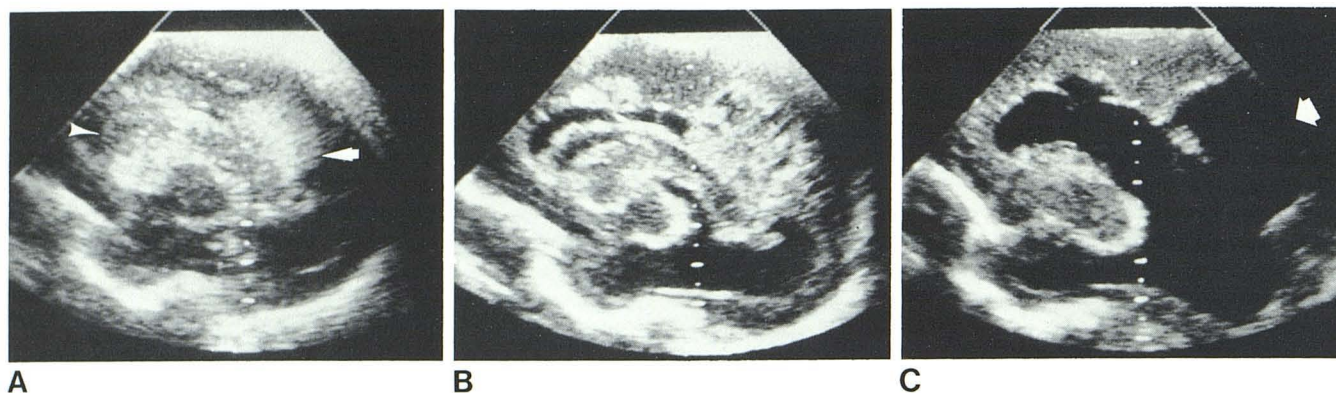

Fig. 2.—Development of porencephaly after IPH. **A**, Day 6. Sagittal sonogram. Left IVH (arrowhead) and IPH (arrow). **B**, Day 14. Severe dilatation with clot retraction and initial changes of IPH to porencephaly. **C**, Day 28. Porencephaly (arrow) in parietooccipital area with persistent severe dilatation.

TABLE 2: Approximate Time of Occurrence of Posthemorrhagic Sequelae

	No. Patients (n = 40)	No. Days after Initial ICH	
		Average	(Range)
Ventricular dilatation:			
Mild	12	6	(2–10)
Moderate	10	12	(8–39)
Severe	7	17	(13–19)
Diminished ventricles	12	19	(8–35)
Porencephaly	9	28	(19–47)

Note.—ICH = intracranial hemorrhage.

tion will resolve spontaneously seems to be related to the extent of ICH, occurring more frequently in neonates with SEH/IVH and less so in those with IVH or IPH. It is suggested that the documentation of progressive ventricular dilatation after 3 weeks is an indication for active medical and/or surgical therapy.

Our observations on the progression of ventricular dilatation agree with other series that evaluated the course of ICH and its sequelae [6–8]. The Emory study evaluated the natural history of ventricular dilatation by serial CT in 49 patients with ICH [7]. They found that 22% of the survivors of ICH developed progressive ventricular dilatation. Ventricular dilatation resolved spontaneously in four of 12, and the likelihood of developing progressive ventricular dilatation was greater in those with extensive IVH. The Johns Hopkins series reported that 11 of 12 neonates with grades III or IV ICH (CT classification) [6] demonstrated a progressive increase in ventricular size [8]. Their follow-up period was 12–22 months. Ventricular dilatation resolved or remained stable in 11 of 15 affected neonates in the Hammersmith series, with four (26%) of 15 spontaneously resolving [9]. These figures correlate well with the five (33%) of 15 neonates with major IVH and/or IPH that resolved spontaneously over our study period.

The timing of the development of porencephaly after an IPH found in our study (19–47 days) correlates well with the 10–56 days reported by Grant et al. [10]. Although the experience with the effect of ventriculoperitoneal shunting

on areas of porencephaly is limited, both the study of Grant et al. and our study indicate a variable response of porencephalic areas to shunting procedures.

The exact mechanism of production of brain damage in posthemorrhagic hydrocephalus is unclear, but it has been suggested that there is a crucial period of white-matter edema during which slow but irreversible brain damage occurs [11]. Even though the results of this study and others like it suggest that the extent of ICH may be helpful in the prediction of the development of posthemorrhagic hydrocephalus, serial sonographic examinations are necessary to determine when to commence therapy.

This study covered the first weeks of life, but it is hoped that data from studies such as this will be helpful in establishing the efficacy of certain treatment regimens such as serial lumbar punctures or external ventricular drainage in reducing the ill effects of progressive ventricular dilatation [12, 13]. Only long-term studies will determine the influence of such therapy on the neurodevelopmental outcome of affected neonates.

ACKNOWLEDGMENTS

We thank Robert Cotton, Hakan Sundell, Jay Shenai, and George Rojas for allowing us to examine neonates under their care in the neonatal intensive care unit; and William Meacham and the neurosurgery house staff for clinical follow-ups on some of the treated neonates.

REFERENCES

1. Babcock D, Han B. The accuracy of high resolution real-time ultrasonography of the head in infancy. *Radiology* 1981;139:665–667
2. Grant E, Bortz F, Schellinger D, et al. Real-time ultrasonography of neonatal intraventricular hemorrhage in comparison with computed tomography. *Radiology* 1981;139:685–689
3. Sauerbrei E, Digney M, Harrison P, et al. Ultrasonic evaluation of neonatal intracranial hemorrhage and its complications. *Radiology* 1981;139:677–684
4. Volpe J. Neonatal intraventricular hemorrhage. *N Engl J Med* 1981;304:886–891

5. Fleischer A, Hutchison A, Kirchner S, James AE. Cranial sonography of the preterm neonate. *Diagn Imaging* **1981**;3:20-28
6. Burstein J, Papile LA, Burstein R. Intraventricular hemorrhage and hydrocephalus in premature newborns: a prospective study with CT. *AJR* **1979**;132:631-635
7. Ahmann P, Lazzara A, Dykes F, Brann AW, Schwartz J. Intraventricular hemorrhage in the high risk preterm infant: incidence and outcome. *Ann Neurol* **1980**;7:118-124
8. Shinnar S, Molteni R, Gammon K, D'Souza B, Altman J, Freeman J. Intraventricular hemorrhage in the premature infant: a changing outlook. *N Engl J Med* **1982**;306:1464-1468
9. Levene M, Starte D. A longitudinal study of posthemorrhagic ventricular dilatation in the newborn. *Arch Dis Child* **1981**;56:905-910
10. Grant E, Kerner M, Schellinger D, et al. Evolution of porencephalic cysts from intraparenchymal hemorrhage in neonates: sonographic evidence. *AJR* **1982**;138:467-470
11. Weller R, Shulman K. Infantile hydrocephalus: clinical, histological, and ultrastructural study of brain damage. *J Neurosurg* **1972**;36:255-265
12. Papile L, Burstein J, Burstein R, Koffler H, Koops B, Johnson J. Posthemorrhagic hydrocephalus in low birth weight infants: treatment by serial lumbar puncture. *J Pediatr* **1980**;97:273-277
13. Hurbaugh R, Saunders R, Edwards W. External ventricular drainage for control of posthemorrhagic hydrocephalus in premature infants. *J Neurosurg* **1981**;55:766-770