

Are your **MRI contrast agents** cost-effective?

Learn more about generic **Gadolinium-Based Contrast Agents**.



FRESENIUS  
KABI

caring for life

# AJNR

## **Intraoperative sonography of intraspinal tumors: initial experience.**

J E Knake, W F Chandler, J E McGillicuddy, T O Gabrielsen, J T Latack, S S Gebarski and P J Yang

*AJNR Am J Neuroradiol* 1983, 4 (6) 1199-1201

<http://www.ajnr.org/content/4/6/1199>

This information is current as  
of April 17, 2024.

# Intraoperative Sonography of Intraspinial Tumors: Initial Experience

James E. Knake<sup>1</sup>  
 William F. Chandler<sup>2</sup>  
 John E. McGillicuddy<sup>2</sup>  
 Trygve O. Gabrielsen<sup>1</sup>  
 Joseph T. Latack<sup>1</sup>  
 Stephen S. Gebarski<sup>1</sup>  
 Peter J. Yang<sup>1</sup>

Real-time sonography during surgery for intraspinal tumors is capable of demonstrating the extent of the tumor, its relation to the spinal cord, and the internal morphology of both the tumor and the cord. Such information is not obtainable intraoperatively by any other imaging method. It is especially valuable when all or a part of the tumor is anterior to the cord and therefore not visible to the surgeon without exploration and the attendant risk of spinal cord injury. Direct contact with the spinal cord is not necessary for sonographic imaging.

Considerable experience has now been gained with intraoperative brain sonography for tumor localization, needle biopsy, cyst aspiration, and shunt placement [1–5]. Sonography has been shown to be both accurate and valuable in such procedures. Surgical treatment of spinal cord lesions presents many of the same challenges; namely, a need to identify and biopsy, drain, or excise a lesion without the luxury of wide surgical exposure or extensive exploration. We recently used intraoperative sonography to examine three intradural, extramedullary spinal tumors and describe that experience.

## Materials and Methods

Mobile real-time sector scanning equipment (Advanced Technology Labs., Bellevue, WA) with either a 5 MHz or 7.5 MHz transducer crystal frequency was used. The scan head and cable were covered with sterile glove or sheath and stockinette, in the same fashion as previously described for intraoperative cranial sonography [2–4]. The laminectomy site was selected on the basis of conventional neuroradiologic examinations, usually myelography and/or computed tomography (CT). With the patient prone and the surgical wound filled to a depth of several centimeters with saline, the transducer face was introduced to the saline pool. Without need for direct dural contact, real-time imaging was done in transaxial and longitudinal planes. The sonographic images were recorded on videotape for subsequent photography. Two thoracic meningiomas and one proximal cauda equina lipoma were examined.

## Results

Each of the lesions was moderately to markedly hyperechoic in comparison with the spinal cord, and their margins were readily identifiable. The two thoracic meningiomas are illustrated in figures 1 and 2. The 5-MHz-frequency transducer was capable of defining the tumor margins, dorsal dural surface, and dorsal surface of the vertebrae anterior to the spinal cord (fig. 2). The 7.5-MHz-frequency transducer was also able to reveal in detail the configuration of the subarachnoid space and the internal morphology of both the tumor and the spinal cord, including its central canal (fig. 1). Both of the meningiomas were situated almost entirely anterior to the spinal cord.

Received February 25, 1983; accepted after revision May 27, 1983.

Presented in part at the annual meeting of the American Society of Neuroradiology, San Francisco, June 1983.

<sup>1</sup> Department of Diagnostic Radiology, Division of Neuroradiology, Box 13, University of Michigan Hospitals, Ann Arbor, MI 48109. Address reprint requests to J. E. Knake.

<sup>2</sup> Department of Surgery, Section of Neurological Surgery, University of Michigan Hospitals, Ann Arbor, MI 48109.

**AJNR 4:1199–1201, Nov/Dec 1983**  
 0195–6108/83/0406–1199 \$00.00  
 © American Roentgen Ray Society

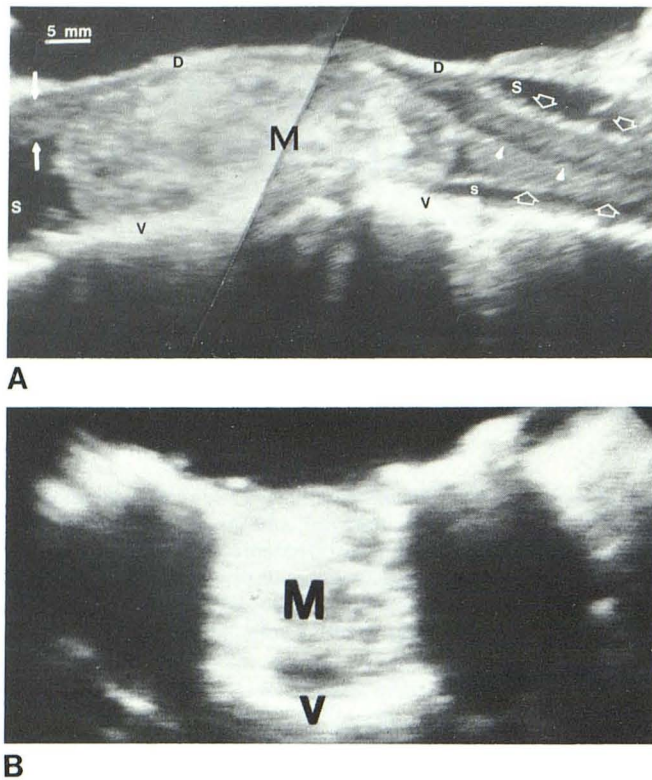


Fig. 1.—Thoracolumbar meningioma anterior to cord. Metrizamide myelogram (not illustrated) showed complete obstruction at upper T12 level from above and at lower L1 level from below. **A**, Intraoperative sonogram, sagittal plane, 7.5 MHz crystal frequency, patient's head to right. A 4.5 × 1.7 cm meningioma (M) is easily identified although not uniformly echogenic; denser internal echoes reflect calcification. Craniad segment of spinal cord (*open arrows*) lies ventrally within subarachnoid space (S) but is displaced dorsally over tumor. Central canal (*arrowheads*) is visible within cord. Compressed proximal cauda equina bundle (*closed arrows*) emerges dorsally at caudal aspect of tumor. Intact dorsal dura (D) well demonstrated. Anechoic space above dura is saline pool used for imaging (see text). V = ventral surface of spinal canal (dura, posterior longitudinal ligaments, and dorsal vertebral body surface). Oblique line through center of tumor results from photographically combining craniad sweep and caudad sweep of transducer into single image and is not visible during sonography. **B**, Axial sonogram, 7.5 MHz crystal frequency. The 2 cm wide meningioma (M) so fully occupies spinal canal that no subarachnoid space is visible. The only sonographic feature other than tumor is ventral spinal canal surface (V).

## Discussion

Preoperative neuroradiologic examinations, particularly myelography but also CT, depend heavily on an intrathecal contrast agent to define the margins of intraspinal masses. When complete obstruction to the passage of contrast agent is present, the region between the cranial and caudal limits of obstruction cannot be evaluated myelographically. By CT, the contents of the spinal canal in this segment may appear only as a uniform tissue density unless fat, cyst, or calcification distinguishes the lesion from the spinal cord itself. Furthermore, even when an intraspinal lesion is well defined by these examinations, parts of the lesion that may be within or anterior to the spinal cord remain invisible to the surgeon observing the dorsal dural surface. In such instances, the cord must be manipulated to inspect the anterior extradural and intradural spaces, or, in the case of

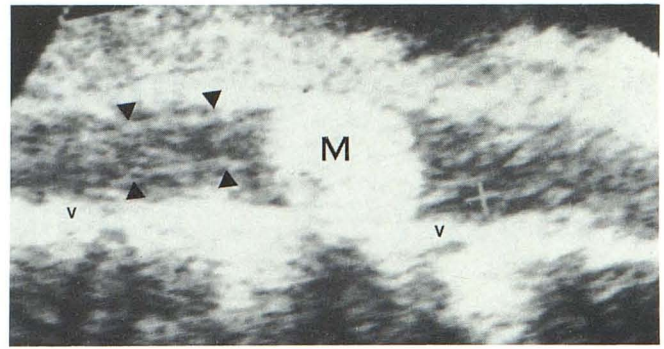


Fig. 2.—Thoracic meningioma anterior to spinal cord. Metrizamide myelogram (not illustrated) revealed complete obstruction at upper margin of T8 from above and at midlevel of T9 from below. Intraoperative sonogram, sagittal plane, 5 MHz crystal frequency, patient's head to left. With this commonly available crystal frequency, meningioma (M) can be localized accurately and dorsally displaced spinal cord (*arrowheads*) identified craniad to tumor. Internal morphology of tumor and cord not imaged (cf. fig. 1). V = ventral surface of spinal canal (dura, posterior longitudinal ligaments, and dorsal vertebral body surface).

intramedullary lesions, the cord must be aspirated or incised. Precise localization of the position and boundaries of intraspinal lesions is necessary during surgery and appears to be provided by real-time sonography.

In our experience, the ease with which the margins of extramedullary tumors anterior to the spinal cord could be defined parallels the findings of Dohrmann and Rubin [6]. The ability to confidently select needle position for the aspiration or biopsy of intramedullary tumors should also be greatly enhanced by sonography and has been described in one instance [6]. Although sonography of a noncystic intramedullary tumor has not yet been reported, we are confident, on the basis of experience with intraoperative sonographic identification of even relatively subtle, noncystic brain neoplasms, that such tumors will be identifiable [4]. Certainly any intramedullary lesion that expands the spinal cord will be localizable by virtue of the cord configuration alone, even if the echo pattern of the lesion is not greatly different from that of the cord.

Although 5 MHz transducers are probably more widely available at present, and although this crystal frequency was capable of defining the margins of the highly echogenic extramedullary tumor shown in figure 2, the 7.5 MHz crystal frequency provided so much greater resolution that exclusive use of the higher frequency must be recommended, especially when an intramedullary lesion is suspected.

Even in the limited case material of our initial experience and that of others [6], the information provided by spinal sonography is shown to be distinct from that of other imaging methods and cannot be obtained intraoperatively by any other means. One can expect that needle biopsy of intramedullary tumors, drainage of cysts, and shunting of syrinx cavities will be assisted routinely by sonography. The visibility of the strongly echogenic posterior vertebral surface indicates that sites of degenerative spurring will be readily detectable, and that anteriorly situated bone fragments in cases of trauma will be easily recognized. Such potentials are under current investigation. Having observed the growth

of intraoperative cranial sonography from its infancy, we foresee a similarly rapid spread of enthusiasm for the use of intraoperative spinal sonography.

#### ACKNOWLEDGMENT

We thank Sandra Ressler for manuscript preparation.

#### REFERENCES

1. Gooding GAW, Edwards MSB, Rabkin AE, Powers SK. Intraoperative real-time ultrasound in the localization of intracranial neoplasms. *Radiology* **1983**;146:459-462
2. Knake JE, Chandler WF, McGillicuddy JE, Silver TM, Gabrielsen TO. Intraoperative sonography for brain tumor localization and ventricular shunt placement. *AJNR* **1982**;3:425-430, *AJR* **1982**;139:733-738
3. Knake JE, Chandler WF, Gabrielsen TO, Latack JT, Gebarski SS. Intraoperative sonography in the nonstereotaxic biopsy and aspiration of subcortical brain lesions. *AJNR* **1983**;4:672-674
4. Knake JE, Silver TM, Chandler WF. Intraoperative cranial sonography for neurosurgical procedures. *Semin Ultrasound* **1982**;2:200-208
5. Rubin JM, Dohrmann GJ. Use of ultrasonically guided probes and catheters in neurosurgery. *Surg Neurol* **1982**;18:143-148
6. Dohrmann GJ, Rubin JM. Intraoperative ultrasound imaging of the spinal cord: syringomyelia, cysts, and tumors—a preliminary report. *Surg Neurol* **1982**;18:395-399