

The **next generation** GBCA
from Guerbet is here

Explore new possibilities >

Guerbet | 

© Guerbet 2024 GUOB220151-A

AJNR

Erratum

AJNR Am J Neuroradiol 2019, 40 (10) E63
doi: <https://doi.org/10.3174/ajnr.A6206>
<http://www.ajnr.org/content/40/10/E63>

This information is current as
of March 20, 2024.

The authors regret that in the article “Surveillance of Unruptured Intracranial Saccular Aneurysms Using Noncontrast 3D-Black-Blood MRI: Comparison of 3D-TOF and Contrast-Enhanced MRA with 3D-DSA” (*AJNR Am J Neuroradiol* 2019;40:960–66), the legend for Fig 4 did not match the figure. A corrected legend with the original figure is reproduced below.

<http://dx.doi.org/10.3174/ajnr.A6206>

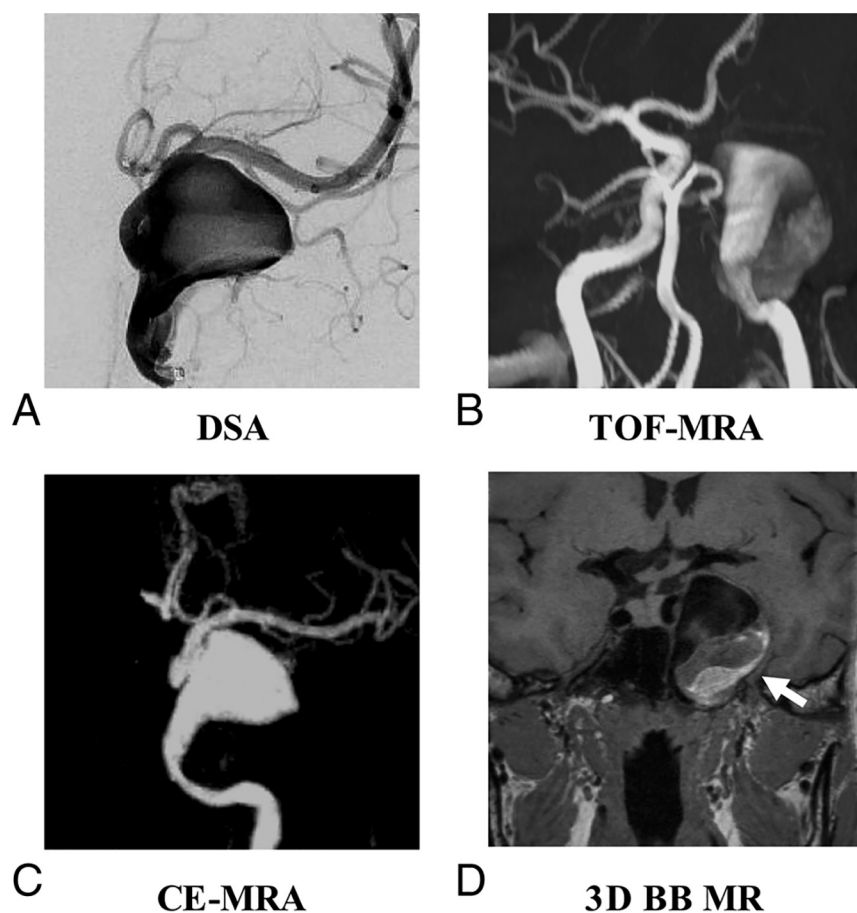


FIG 4. A, A 63-year-old woman with a right internal carotid artery aneurysm on DSA. 3D black-blood (BB) SPACE (D) can clearly visualize the sac and intraluminal thrombus of the aneurysm, which is superior to DSA (A), TOF-MRA (B), and contrast-enhanced (CE)-MRA (C).