

Are your **MRI contrast agents** cost-effective?

Learn more about generic **Gadolinium-Based Contrast Agents**.



**FRESENIUS
KABI**

caring for life

AJNR

**Treatment of Ruptured Blister-Like
Aneurysms with the FRED Flow Diverter: A
Multicenter Experience**

M.A. Möhlenbruch, F. Seker, E. Özlük, O. Kizilkilic, E. Broussalis, M. Killer-Oberpfalzer, C.J. Griessenauer, M. Bendszus and N. Kocer


This information is current as
of April 17, 2024.

AJNR Am J Neuroradiol 2020, 41 (12) 2280-2284

doi: <https://doi.org/10.3174/ajnr.A6849>

<http://www.ajnr.org/content/41/12/2280>

Treatment of Ruptured Blister-Like Aneurysms with the FRED Flow Diverter: A Multicenter Experience

 M.A. Möhlenbruch,  F. Seker,  E. Özlük,  O. Kizilkilic,  E. Broussalis,  M. Killer-Oberpfalzer,  C.J. Griessenauer,  M. Bendszus, and  N. Kocer



ABSTRACT

BACKGROUND AND PURPOSE: Treatment of ruptured blister-like aneurysms is technically challenging. This study aimed at analyzing the safety and efficacy of the Flow-Redirection Endoluminal Device (FRED) in the treatment of ruptured blister-like aneurysms.

MATERIALS AND METHODS: In a retrospective multicenter study, all patients treated with the FRED due to a ruptured intracranial blister-like aneurysm between January 2013 and May 2019 were analyzed. The primary end points for clinical safety were mRS 0–2 at 6 months after treatment and the absence of major ipsilateral stroke or death. The primary end points for efficacy were the absence of rebleeding after treatment and complete angiographic occlusion according to the O’Kelly-Marotta classification at 6 months after treatment.

RESULTS: In total, 30 patients with 30 ruptured blister-like aneurysms were treated. Immediate complete aneurysm obliteration (O’Kelly-Marotta classification D) with the FRED was achieved in 10 patients (33%). Of the 26 patients with follow-up, complete obliteration was achieved in 21 patients (80%) after 6 months and in 24 patients (92%) in the final follow-up (median, 22 months). Twenty-three patients (77%) achieved mRS 0–2 at 6 months. Major stroke or death occurred in 17%. Two patients died due to pneumonia, and 2 patients died due to infarction following cerebral vasospasm. There was no case of rebleeding after FRED implantation. There was 1 case of delayed asymptomatic stent occlusion.

CONCLUSIONS: Treatment of ruptured blister-like aneurysms with the FRED is safe and effective.

ABBREVIATIONS: OKM = O’Kelly-Marotta; FRED = Flow-Redirection Endoluminal Device; PED = Pipeline Embolization Device

Blister-like aneurysms are a subtype of intracranial aneurysm. It is assumed that blister-like aneurysms are a laceration of the arterial wall based on degeneration of the internal elastic lamina. This focal wall defect seems to be covered with normal adventitia and fibrinous tissue.¹ Blister-like aneurysms are characterized by a thin vessel wall and the absence of an aneurysm neck. There is no pseudolumen or organized thrombus. Blister-

like aneurysms typically arise at nonbranching segments of the supraclinoid internal carotid artery, but they can also arise at other locations such as the basilar artery.^{2–6}

Surgical treatment and endovascular coiling of blister-like aneurysms are technically challenging.⁷ The introduction of flow diverters, however, has allowed a safe and effective treatment option for blister-like aneurysms.^{8,9} Several studies on the treatment of blister-like aneurysms with the Pipeline Embolization Device (PED; Medtronic) have shown good clinical and angiographic results.^{4,10–15}

The aim of this retrospective multicenter study was to analyze the safety and efficacy of the Flow-Redirection Endoluminal Device (FRED; MicroVention) in the treatment of ruptured blister-like aneurysms.

MATERIALS AND METHODS

Patient Population

This retrospective multicenter study at 3 centers was approved by the local institutional review board at each participating center (Heidelberg/Germany, Istanbul/Turkey, Salzburg/Austria). Between January 2013 and September 2019, all patients with ruptured blister-


Received June 16, 2020; accepted after revision August 5.

From the Department of Neuroradiology (M.A.M., F.S., M.B.), Heidelberg University Hospital, Heidelberg, Germany; Department of Radiology (E.Ö.), Acibadem University Atakent International Hospital, Istanbul, Turkey; Division of Neuroradiology (O.K., N.K.), Department of Radiology, Cerrahpasa Medical Faculty, Istanbul University-Cerrahpasa, Istanbul, Turkey; Research Institute of Neurointervention (E.B., M.K.-O., C.J.G.), Paracelsus Medical University, Salzburg, Austria; and Department of Neurosurgery (C.J.G.), Geisinger, Danville, Pennsylvania.

M.A. Möhlenbruch and F. Seker contributed equally to this work.

Paper previously presented at: World Federation of Interventional and Therapeutic Neuroradiology Congress, October 21–24, 2019; Naples, Italy.

Please address correspondence to Naci Kocer, MD, Department of Radiology, Cerrahpasa School of Medicine, 34300 Cerrahpasa, Istanbul, Turkey; e-mail: nkocer@istanbul.edu.tr

 Indicates article with supplemental on-line table.

<http://dx.doi.org/10.3174/ajnr.A6849>

like aneurysms treated with the FRED as an off-label therapy were included. Blister-like aneurysms were defined according to Peschillo et al⁶ as small, conical, wide-neck aneurysms located at a non-branching site of the circle of Willis. Data collection included demographics, clinical data, imaging data, aneurysm features, details of the aneurysm treatment, and clinical outcome.

FRED

A detailed description of the FRED has been published previously. Briefly, the FRED is a braided self-expandable closed-cell flow diverter. The midsection, which encompasses 80% of its total length, has a dual-layer-design low-porosity inner mesh of higher pore attenuation (48 wires) and an outer stent with high porosity (16 wires). The inner mesh and the outer stent are attached by an interwoven double helix of tantalum strands. The FRED is currently available in 5 different diameters (3.5, 4.0, 4.5, 5.0, and 5.5 mm), recommended for vessel diameters from 3.0 to 5.5 mm, at working lengths from 7 to 56 mm.¹⁶⁻¹⁸

Aneurysm Treatment

Endovascular treatment was performed with the patient under general anesthesia. All patients were treated with the FRED. FRED size was chosen according to the maximal diameter of the parent artery. FRED length covered the parent artery at least 3 mm proximal and distal to the blister-like aneurysm. Decisions for additional coiling (eg, due to aneurysm size) were at the discretion of the treating physician. Antiplatelet medication was given according to in-house protocols at each site.

Imaging Data

Imaging was performed according to in-house protocols of each participating site. In general, patients were followed up at least once by DSA. Thereafter, aneurysms were followed up by DSA, flat panel CT angiography with intravenous contrast agent injection, or contrast-enhanced TOF-MRI. Local experienced neuro-interventionalists not involved in the aneurysm treatment reviewed the imaging data.

Outcome Measures

End points for clinical safety were mRS 0–2 at 6 months after treatment and absence of major ipsilateral stroke or death. End points for efficacy were absence of rebleeding after treatment and complete angiographic occlusion according to the O’Kelly-Marotta classification (OKM) at 6 months after treatment.¹⁹

RESULTS

Study Subjects

In total, 30 patients with 30 ruptured blister-like aneurysms were included in this study. The mean age was 55.6 years, and 63.3% of the patients were female. Hunt and Hess grades and Fisher grades are shown in Table 1.

Procedure

The median duration from onset to aneurysm treatment was 2 days. Treatment was delayed due to either delayed detection of the blister-like aneurysm and/or delayed referral of patients from other hospitals.

Table 1: Baseline characteristics

Characteristic	Value
Age (mean) (SD) (yr)	55.6 (12.9)
Female (No.) (%)	19 (63.3)
Hunt and Hess grade (No.) (%)	
1	13 (43.3)
2	4 (13.3)
3	5 (16.7)
4	6 (20.0)
5	2 (6.7)
Fisher grade (No.) (%)	
1	3 (10.0)
2	14 (46.7)
3	7 (23.3)
4	6 (20.0)
Extraventricular drain (No.) (%)	
Before aneurysm treatment	14 (46.7)
After aneurysm treatment	0 (0)
None	16 (53.3)

Table 2: Aneurysm characteristics

Characteristics	Value
Aneurysm rupture to treatment (No.) (%)	
0–1 day	13 (43.3)
2–7 days	8 (26.7)
>7 days	9 (30.0)
Aneurysm location (No.) (%)	
Internal carotid artery	19 (63.3)
Basilar artery	7 (23.3)
Vertebral artery	2 (6.7)
Anterior communicating artery	1 (3.3)
Posterior cerebral artery	1 (3.3)
Median aneurysm height (No.) (mm)	1.7
Median aneurysm diameter (No.) (mm)	2
Median diameter of parent vessel proximally (No.) (mm)	3.5
Median diameter parent vessel distally (No.) (mm)	3
Median diameter of FRED (No.) (mm)	4
Median length of FRED (No.) (mm)	13
Median No. of FREDs used	1
Aneurysms that were additionally coiled (No.) (%)	2 (6.7)

A ventricular drainage was placed in 14 patients (46.7%) before aneurysm treatment. No ventricular drainage was placed after flow diversion.

Aneurysm location was mostly the supraclinoid ICA (63.3%) and basilar artery (23.3%), with a median aneurysm size of 2 mm (Table 2). All aneurysms were initially treated with a single FRED flow diverter each. In 29 of 30 cases, the FRED was completely adherent to the wall of the parent artery immediately after deployment. In 1 case, the FRED opened; however, additional angioplasty was necessary to adhere the FRED completely to the vessel wall.

In 2 cases, the treating physician decided to place coils inside the blister-like aneurysm in addition to flow-diverter implantation because of the aneurysm size. The maximum aneurysm diameters in these 2 cases were 4 and 2 mm, respectively.

Medication

Antiplatelet medication was given according to in-house protocols at each site. Preoperatively, dual-antiplatelet therapy with aspirin and clopidogrel was given in 8 patients (26.7%), and prasugrel was given in 4 patients (13.3%). Intraoperatively, 20

Table 3: Aneurysm occlusion

Occlusion Grading	End of the Procedure (n = 30)	At 6 Months (n = 26)	At 12 Months (n = 26)	Last Follow-Up ^a (n = 26)
OKM (No.) (%)				
D	10 (33.3)	21 (80.8)	22 (84.6)	24 (92.3)
C	4 (13.3)	3 (11.5)	3 (11.5)	2 (7.7)
B	16 (53.3)	2 (7.7)	1 (3.8)	0 (0)
A	0 (0)	0 (0)	0 (0)	0 (0)

^a Median last follow-up was approximately 22 months (interquartile range, 12–37 months).

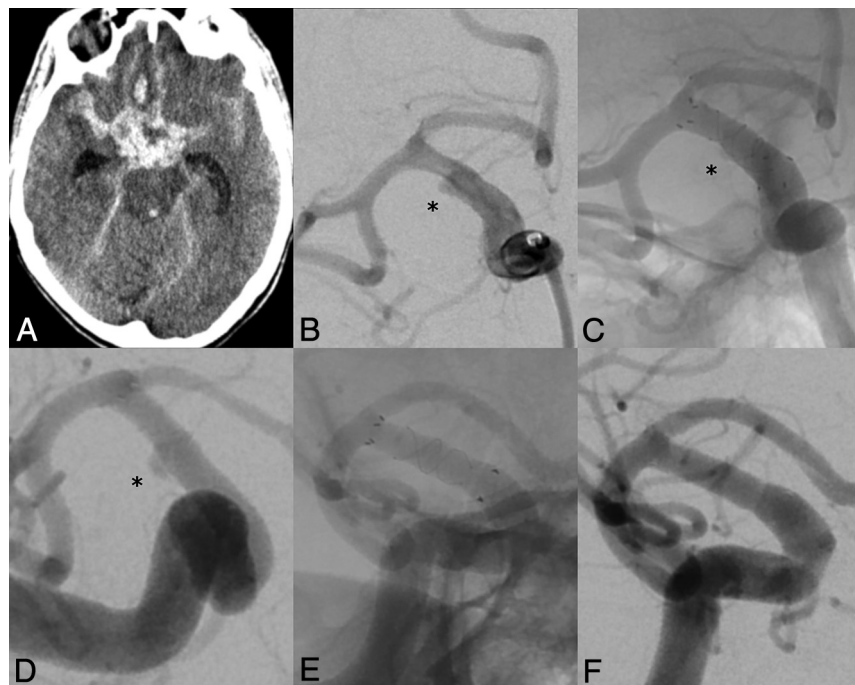


FIGURE. A, Nonenhanced head CT of a female patient in her 50s showing subarachnoid hemorrhage, Hunt and Hess grade 4, and Fisher grade 4. B, Angiography reveals a blister-like aneurysm of the right supraclinoid ICA with a maximum neck diameter of 3.3 mm. C, Angiographic result immediately after deployment of FRED 4.0 × 13 mm. D, Follow-up angiography at day 17 shows a residual aneurysm filling. E and F, Follow-up angiography at 3 months demonstrates complete aneurysm obliteration. mRS score at 3 months was 1.

patients (66.7%) received glycoprotein IIb/IIIa inhibitors, and 7 patients (23.3%) received heparin. Postoperatively, dual-antiplatelet therapy with aspirin and clopidogrel was given in 21 patients (70.0%); ticagrelor, in 5 patients (16.7%); and prasugrel, in 4 patients (13.3%). Patients continued antiplatelet therapy according to the standard of care in the respective hospital for at least 6 months.

Safety

Twenty-three patients (76.7%) achieved mRS 0–2 after 6 months (Online Table). Two patients died due to pneumonia, and 2 patients died due to SAH-related delayed cerebral ischemia.

Procedure-related complications occurred in 4 cases: One patient with a basilar blister-like aneurysm had a major stroke after flow diversion. MR imaging revealed a left paramedian pontine infarction indicating a perforator stroke despite premedication of the patient with tirofiban and heparin before deployment of the FRED.

Another patient with a blister-like aneurysm of the ICA had a minor stroke due to distal cerebral emboli. Both patients received tirofiban during the procedure and were on dual-antiplatelet therapy after treatment. They were discharged with mRS 4, and both recovered to mRS 2 one year after treatment. In 1 case, there was partial thrombus formation within the FRED. However, this was not hemodynamically relevant, and the FRED was patent on follow-up images. The patient received tirofiban during the procedure and ticagrelor thereafter. There was 1 case of retroperitoneal hematoma requiring medical management.

In 1 patient, asymptomatic FRED occlusion occurred, which was diagnosed during a routine follow-up 19 months after aneurysm treatment. In this case, aspirin had been discontinued 12 months before.

There was no case of recurrent hemorrhage before or after flow diversion.

Efficacy

Complete aneurysm obliteration (OKM D) at the end of the procedure was achieved in 10 patients (33.3%).

Follow-up imaging was not possible in 4 patients due to death as described above. Except for 1 patient who was followed up only once by flat panel CT with intravenous contrast agent injection, all patients underwent DSA at least once.

Follow-up imaging was available in 26 patients. Six months after aneurysm treatment, 21 patients (80.8%)

achieved complete obliteration (OKM D). A residual neck (OKM C) was visible in 3 patients (11.5%), and a residual aneurysm (OKM B) was visible in 2 patients (7.7%). In the final follow-up (median, 22 months), complete obliteration was observed in 24 patients (92.3%) (Table 3).

One patient required additional implantation of another FRED 10 days after the initial treatment due to aneurysm growth. Another patient required implantation of a second FRED 2 years after initial treatment because the blister-like aneurysm was not sufficiently obliterated. No complications occurred in either case, and the aneurysms were completely obliterated at follow-up imaging.

DISCUSSION

The present retrospective study adds evidence that treatment of ruptured blister-like aneurysms with the FRED is safe and effective. Complete aneurysm obliteration with the FRED was achieved in 80% at 6 months and in 92% in the final follow-up.

Most important, there was no case of rebleeding after FRED implantation. About 77% achieved mRS 0–2 at 6 months. Major stroke or death occurred in 17%.

The results of the present study with the FRED are similar to those of Mokin et al,¹⁵ who analyzed treatment of ruptured blister-like aneurysms with the PED. Mokin et al reported complete aneurysm obliteration in 87.5% on follow-up angiograms in patients treated with the PED. Furthermore, they reported that 68% of their patients achieved good clinical outcome at 3 months. The results of the present study suggest that the FRED and PED show similar safety and efficacy in the treatment of blister-like aneurysms. While the PED is a 48-strand braided mesh, the FRED is a dual-layer stent with an inner stent consisting of 48 wires and an additional outer stent with 16 wires serving as a scaffold for the inner stent. This design might potentially increase aneurysm obliteration after flow diversion with the FRED.^{18,20} However, there are currently no data supporting this hypothesis.

For many years, treatment of blister-like aneurysms has been technically challenging for both clipping and coiling. Today, flow-diverter implantation allows the endovascular treatment of blister-like aneurysms just as in wide-neck and fusiform aneurysms.^{7,21} The mesh design of flow diverters alters blood flow into the aneurysm and induces a thrombosis within the aneurysm (Figure).⁴

There are often concerns regarding stent or flow-diverter deployment in patients with aneurysmal SAH because it requires antiplatelet and/or anticoagulation treatment to avoid thrombosis.⁷ Antiplatelet therapy, however, increases the risk of intracranial rebleeding. There was no rebleeding in any cases in this study, though. Mokin et al¹⁵ reported that 1 of 49 patients had delayed aneurysmal rerupture. Mazur et²² and Nerva et al²³ each reported 1 case of delayed rebleeding after PED deployment in a patient with a ruptured blister-like aneurysm. There are, however, case studies by Ryan et al¹⁴ ($n=13$), Linfante et al¹² ($n=10$), Capocci et al²⁴ ($n=8$), Chalouhi et al,¹⁰ ($n=8$), Cerejo et al ($n=8$),²⁵ Çinar et al ($n=7$),²⁶ and Hu et al¹¹ ($n=3$) reporting no rebleeding after flow-diverter implantation in patients with ruptured blister-like aneurysms. Ryan et al¹⁴ ($n=13$) reported 1 case of rebleeding, however, due to an unrecognized additional aneurysm. The data of the present study and previous studies show that the risk of rebleeding after flow-diverter implantation in blister-like aneurysms is low.

There was 1 case (3.3%) of delayed asymptomatic in-stent thrombosis in the present study. Thrombosis was diagnosed 19 months after aneurysm treatment during a routine follow-up. In this case, aspirin had been discontinued 12 months before. Thrombosis might have been prevented by a longer period of antiplatelet medication. Mokin et al¹⁵ reported 2 cases of intraprocedural in-stent thrombosis, 2 cases of intraprocedural thrombosis in an M3 segment, 1 case of delayed asymptomatic in-stent stenosis, and 1 case of delayed asymptomatic in-stent thrombosis. These data suggest that the risk of thrombosis might be higher than that of rebleeding. Sufficient antiplatelet therapy is therefore mandatory.

This study has several limitations mostly due to its retrospective multicenter design with a potential selection and reporting bias. Aneurysm treatment and medication differed at each

participating site. Also imaging data and clinical outcome were not reviewed by a central core laboratory.

CONCLUSIONS

This study adds evidence that treatment of blister-like aneurysms with the FRED is safe and effective. Outcome results are similar to those of the PED.

Disclosures: Markus A. Möhlenbruch—UNRELATED: Consultancy: Medtronic, MicroVention, Stryker*; Grants/Grants Pending: Balt, Medtronic, MicroVention, Stryker*; Payment for Lectures Including Service on Speakers Bureaus: Medtronic, MicroVention, Stryker.* Christoph J. Griessenauer—UNRELATED: Consultancy: Stryker; Employment: Geisinger. Martin Bendszus—UNRELATED: Board Membership: Data and Safety Monitoring Board for Vascular Dynamics, Boehringer; Consultancy: Codman, Braun; Grants/Grants Pending: DFG, EU, Hopp Foundation, Novartis, Siemens, Stryker, Guerbet*; Payment for Lectures Including Service on Speakers Bureaus: Novartis, Teva Pharmaceutical Industries, Codman, Guerbet, Merck, Grifols, Bayer. Naci Kocer—UNRELATED: Other: proctoring and consultant agreement with MicroVention. Monika Killer-Oberpfalzer—RELATED: Grant: research grant from MicroVention/Terumo*; *Money paid to the institution.

REFERENCES

1. Ishikawa T, Nakamura N, Houkin K, et al. **Pathological consideration of a “blister-like” aneurysm at the superior wall of the internal carotid artery: case report.** *Neurosurgery* 1997;40:403–06 [CrossRef Medline](#)
2. Abe M, Tabuchi K, Yokoyama H, et al. **Blood blister-like aneurysms of the internal carotid artery.** *J Neurosurg* 1998;89:419–24 [CrossRef Medline](#)
3. Mizutani T, Miki Y, Kojima H, et al. **Proposed classification of non-atherosclerotic cerebral fusiform and dissecting aneurysms.** *Neurosurgery* 1999;45:253–59 [CrossRef Medline](#)
4. Szmuda T, Sloniewski P, Waszak PM, et al. **Towards a new treatment paradigm for ruptured blood blister-like aneurysms of the internal carotid artery? A rapid systematic review.** *J Neurointerv Surg* 2016;8:488–94 [CrossRef Medline](#)
5. Peschillo S, Miscusi M, Caporlingua A, et al. **Blister-like aneurysms in atypical locations: a single-center experience and comprehensive literature review.** *World Neurosurg* 2015;84:1070–79 [CrossRef Medline](#)
6. Peschillo S, Cannizzaro D, Caporlingua A, et al. **A systematic review and meta-analysis of treatment and outcome of blister-like aneurysms.** *AJNR Am J Neuroradiol* 2016;37:856–61 [CrossRef Medline](#)
7. Peitz GW, Sy CA, Grandhi R. **Endovascular treatment of blister aneurysms.** *Neurosurg Focus* 2017;42:E12 [CrossRef Medline](#)
8. Rouchaud A, Brinjikji W, Cloft HJ, et al. **Endovascular treatment of ruptured blister-like aneurysms: a systematic review and meta-analysis with focus on deconstructive versus reconstructive and flow-diverter treatments.** *AJNR Am J Neuroradiol* 2015;36:2331–39 [CrossRef Medline](#)
9. Zhu D, Yan Y, Zhao P, et al. **Safety and efficacy of flow diverter treatment for blood blister-like aneurysm: a systematic review and meta-analysis.** *World Neurosurg* 2018;118:e79–86 [CrossRef Medline](#)
10. Chalouhi N, Zanaty M, Tjoumakaris S, et al. **Treatment of blister-like aneurysms with the Pipeline Embolization Device.** *Neurosurgery* 2014;74:527–32 [CrossRef Medline](#)
11. Hu YC, Chugh C, Mehta H, et al. **Early angiographic occlusion of ruptured blister aneurysms of the internal carotid artery using the Pipeline Embolization Device as a primary treatment option.** *J Neurointerv Surg* 2014;6:740–43 [CrossRef Medline](#)
12. Linfante I, Mayich M, Sonig A, et al. **Flow diversion with Pipeline Embolic Device as treatment of subarachnoid hemorrhage secondary to blister aneurysms: dual-center experience and review of the literature.** *J Neurointerv Surg* 2017;9:29–33 [CrossRef Medline](#)
13. Yoon JW, Siddiqui AH, Dumont TM, et al. Endovascular Neurosurgery Research Group. **Feasibility and safety of Pipeline Embolization Device in patients with ruptured carotid blister aneurysms.** *Neurosurgery* 2014;75:419–29 [CrossRef Medline](#)

14. Ryan RW, Khan AS, Barco R, et al. **Pipeline Flow Diversion of ruptured blister aneurysms of the supraclinoid carotid artery using a single-device strategy.** *Neurosurg Focus* 2017;42:E11 [CrossRef Medline](#)
15. Mokin M, China A, Primiani CT, et al. **Treatment of blood blister aneurysms of the internal carotid artery with flow diversion.** *J Neurointerv Surg* 2018;10:1074–78 [CrossRef Medline](#)
16. Killer-Oberpfalzer M, Kocer N, Griessenauer CJ, et al. **European multicenter study for the evaluation of a dual-layer flow-diverting stent for treatment of wide-neck intracranial aneurysms: the European Flow-Redirection Intraluminal Device Study.** *AJNR Am J Neuroradiol* 2018;39:841–47 [CrossRef Medline](#)
17. Kocer N, Islak C, Kizilkilic O, et al. **Flow Redirection Endoluminal Device in treatment of cerebral aneurysms: initial experience with short-term follow-up results: clinical article.** *J Neurosurg* 2014;120:1158–71 [CrossRef Medline](#)
18. Möhlenbruch MA, Herweh C, Jestaedt L, et al. **The FRED Flow-Diverter Stent for intracranial aneurysms: clinical study to assess safety and efficacy.** *AJNR Am J Neuroradiol* 2015;36:1155–61 [CrossRef Medline](#)
19. O'Kelly CJ, Krings T, Fiorella D, et al. **A novel grading scale for the angiographic assessment of intracranial aneurysms treated using flow diverting stents.** *Interv Neuroradiol* 2010;16:133–37 [CrossRef Medline](#)
20. Griessenauer CJ, Thomas AJ, Enriquez-Marulanda A, et al. **Comparison of Pipeline Embolization Device and Flow Re-Direction Endoluminal Device flow diverters for internal carotid artery aneurysms: a propensity score-matched cohort study.** *Neurosurgery* 2019;85:E249–55 [CrossRef Medline](#)
21. Meling TR. **What are the treatment options for blister-like aneurysms?** *Neurosurg Rev* 2017;40:587–93 [CrossRef Medline](#)
22. Mazur MD, Taussky P, MacDonald JD, et al. **Rerupture of a blister aneurysm after treatment with a single flow-diverting stent.** *Neurosurgery* 2016;79:E634–38 [CrossRef Medline](#)
23. Nerva JD, Morton RP, Levitt MR, et al. **Pipeline Embolization Device as primary treatment for blister aneurysms and iatrogenic pseudoaneurysms of the internal carotid artery.** *J Neurointerv Surg* 2015;7:210–16 [CrossRef Medline](#)
24. Capocci R, Shotar E, Di Maria F, et al. **Delayed treatment (≥5 days) by flow diversion of ruptured blister-like cerebral aneurysms.** *Clin Neuroradiol* 2020;30:287–96 [CrossRef Medline](#)
25. Cerejo R, Bain M, John S, et al. **Flow diverter treatment of cerebral blister aneurysms.** *Neuroradiology* 2017;59:1285–90 [CrossRef Medline](#)
26. Çinar C, Oran İ, Bozkaya H, et al. **Endovascular treatment of ruptured blister-like aneurysms with special reference to the flow-diverting strategy.** *Neuroradiology* 2013;55:441–47 [CrossRef Medline](#)