Are your MRI contrast agents cost-effective?
Learn more about generic Gadolinium-Based Contrast Agents.
FRESENIUS KABI
caring for life

AJNR

Flow Diversion of Posterior Circulation Aneurysms: Systematic Review of Disaggregated Individual Patient Data

A. Alwakeal, N.A. Shlobin, P. Golnari, W. Metcalf-Doetsch, P. Nazari, S.A. Ansari, M.C. Hurley, D.R. Cantrell, A. Shaibani, B.S. Jahromi and M.B. Potts

This information is current as of April 19, 2024.

AJNR Am J Neuroradiol 2021, 42 (10) 1827-1833
doi: https://doi.org/10.3174/ajnr.A7220
http://www.ajnr.org/content/42/10/1827

Flow Diversion of Posterior Circulation Aneurysms: Systematic Review of Disaggregated Individual Patient Data

A. Alwakeal, N.A. Shlobin, P. Golnari, W. Metcalf-Doetsch, P. Nazari, S.A. Ansari, M.C. Hurley, D.R. Cantrell, A. Shaibani, B.S. Jahromi, and M.B. Potts

ABSTRACT

BACKGROUND: Experience with endoluminal flow diversion for the treatment of posterior circulation aneurysms is limited.

PURPOSE: We sought to investigate factors associated with the safety and efficacy of this treatment by collecting disaggregated patient-level data from the literature.

DATA SOURCES: PubMed, EMBASE, and Ovid were searched up through 2019 for articles reporting flow diversion of posterior circulation aneurysms.

STUDY SELECTION: Eighty-four studies reported disaggregated data for 301 separate posterior circulation aneurysms.

DATA ANALYSIS: Patient, aneurysm, and treatment factors were collected for each patient. Outcomes included the occurrence of major complications, angiographic occlusion, and functional outcomes based on the mRS.

DATA SYNTHESIS: Significant differences in aneurysm and treatment characteristics were seen among different locations. Major complications occurred in 22%, angiographic occlusion was reported in 65% (11.3 months of mean follow-up), and good functional outcomes (mRS 0–2) were achieved in 67% (13.3 months of mean follow-up). Multivariate analysis identified age, number of flow diverters used, size, and prior treatment to be associated with outcome measures. Meta-analysis combining the current study with prior large nondisaggregated series of posterior circulation aneurysms treated with flow diversion found a pooled incidence of 20% ($n = 712$ patients) major complications and 75% ($n = 581$ patients) angiographic occlusions.

LIMITATIONS: This study design is susceptible to publication bias. Use of antiplatelet therapy was not uniformly reported.

CONCLUSIONS: Endoluminal flow diversion is an important tool in the treatment of posterior circulation aneurysms. Patient age, aneurysm size, prior treatment, and the number of flow diverters used are important factors associated with complications and outcomes.

ABBREVIATIONS: aOR = adjusted OR; FD = flow diverter; PCA = posterior cerebral artery; VBJ = vertebrobasilar junction

Endoluminal flow diversion is a well-established treatment for cerebral aneurysms, but most flow diverters (FDs) have been approved for the treatment of anterior circulation aneurysms.[1] Posterior circulation aneurysms comprise ~10%–15% of all cerebral aneurysms,[2] and some of the first cases of flow diversion in the cerebral circulation involved posterior circulation aneurysms.[3,4] However, the early flow-diversion experience was notable for several reports of complications associated with the treatment of posterior circulation aneurysms,[5,6] resulting in severe morbidity or death.[7] Although less common than anterior circulation aneurysms, aneurysms of the posterior circulation have an increased risk of rupture with respect to size,[8] and the treatment risks are typically higher than in anterior circulation aneurysms regardless of treatment technique.[8,9] Although there have been several single- and multicenter series, reviews, and meta-analyses[10] of flow diversion for posterior circulation aneurysms, such aneurysms comprise a diverse set of morphologies and anatomic configurations that would presumably affect the technical outcomes and safety of flow diversion. Given the relative rarity of posterior circulation aneurysms, we sought to perform a systematic review of disaggregated

Received March 12, 2021; accepted after revision April 29.

From the Department of Neurological Surgery (A.A., N.A.S., P.G., W.M.-D., P.N., S.A.A., M.C.H., A.S., B.S.J., M.B.P.) and Radiology (A.A., S.A.A., M.C.H., D.R.C., A.S., B.S.J., M.B.P.), Northwestern Memorial Hospital, Feinberg School of Medicine, Northwestern University, Chicago, Illinois.

Please address correspondence to Matthew B. Potts, MD, 676 N St. Clair St, Suite 2210, Chicago, IL 60611; e-mail: matthew.potts@northwestern.edu; @MatthewPottsMD

Indicates open access to non-subscribers at www.ajnr.org

Indicates article with online supplemental data.

http://dx.doi.org/10.3174/ajnr.A7220

individual case data of flow diversion for posterior circulation aneurysms to obtain a large series to investigate specific factors associated with outcome.

MATERIALS AND METHODS

Literature Search

We performed a systematic review in accordance with the Preferred Reporting Items for Systematic Review and Meta-Analyses (PRISMA) statement.[11] We searched PubMed MEDLINE (National Library of Science), EMBASE (Elsevier), and Ovid (Wolters Kluwer) databases in December 2019 using Boolean combinations of search terms associated with the use of flow diverters for cerebral aneurysms and the names of specific endoluminal flow-diverter devices, including the Pipeline Embolization Device (PED; Medtronic), Silk (Balt Extrusion), Flow-Redirection Endoluminal Device (FRED; MicroVention), Surpass Streamline Flow Diverter (Stryker Neurovascular), the p64 Flow-Modulation Device (phenox), Derivo embolization device (Acandis), and Tubridge flow diverter (MicroPort NeuroTech). Full search terms are listed in the Online Supplemental Data. All data bases were searched back to 2008, and the search was limited to articles published in or translated into English. The protocol for this systematic review was not registered.

Full text articles were included in this study if they reported the use of endoluminal flow diversion for the treatment of cerebral aneurysms of the posterior circulation and included disaggregated individual patient-level data for all patients in the series. Posterior circulation aneurysms were defined as involving the vertebral arteries, PICA, basilar artery, and major branches of the basilar artery, including the AICA, superior cerebellar artery (SCA), and posterior cerebral artery (PCA). A distinction was made between extradural and intradural vertebral artery aneurysms. Similarly, distal PICA aneurysms in which the FD was placed within the PICA were distinguished from PICA-origin aneurysms in which the FD was placed in the parent vertebral artery. Basilar perforator artery aneurysms arising distal to the perforator origin were specifically excluded from this analysis because such aneurysms are not amenable to direct flow diversion (ie, placement of an FD within a basilar perforator artery). Additional articles were identified through review of citations in included articles.

Data Collection and Analysis

Data were collected for each individual patient in each included article and included patient demographics (sex, age), presentation (ruptured versus unruptured), aneurysm characteristics (location, size, type), treatment details (prior treatment, type of flow diverter, number of FDs, adjuvant use of coils), occurrence of major complications, and radiographic and functional outcomes. Functional outcomes were recorded using the mRS. When mRS outcomes were not reported but a description of the patient's neurologic function was provided, this was translated into an mRS score. If no functional outcome was provided but the patient underwent imaging follow-up, the patient was noted to be "alive." Major complications were defined as any hemorrhage, infarct, or other complication that resulted in a functionally significant neurologic deficit or death. Unexplained neurologic worsening of ≥2 points on the mRS was also considered a major complication. Individual cases were excluded if they lacked both angiographic and functional outcome data. Specific aneurysm locations were excluded if we found <5 cases in the literature. In addition, we differentiated proximal-versus-distal PICA aneurysm locations but excluded cases if it was not clear where the flow diverter was placed (ie, within the PICA itself or within the vertebral artery across the origin of the PICA). After full data collection, individual cases were again reviewed to remove any potential duplicates.

Descriptive statistics were performed using R statistical and computing software (http://CRAN.R-project.org). Major complication, angiographic occlusion, and poor neurologic outcome (mRS >2) were each considered as a separate outcome. Comparisons of baseline variables among aneurysm locations were performed in R using analysis of variance for continuous variables and the Fisher exact test for categoric variables. To determine factors associated with these outcomes, we performed uni- and multivariate binary logistic regression analyses with SPSS (IBM) for each outcome using patient (sex, age), aneurysm (presentation, location, type, size), and treatment characteristics (prior treatment, adjunct coiling, number of FDs) to obtain unadjusted ORs and adjusted ORs (aORs), respectively. Meta-analyses of pooled proportions from trials reporting aggregated data of ≥10 patients with posterior circulation aneurysms treated with flow diversion were performed with the metaphor package in R (http://CRAN.R-project.org/package=metafor) using a DerSimonian and Laird random-effects model. Statistical significance was set at $P < .05$.

RESULTS

A systematic review (Online Supplemental Data) of PubMed, EMBASE, and Ovid returned 84 articles reporting disaggregated patient-level data for the use of endoluminal FDs for the treatment of posterior circulation aneurysms meeting the inclusion and exclusion criteria in 301 separate aneurysms (Online Supplemental Data). Fewer than 5 cases of superior cerebellar artery and AICA aneurysms were identified, so the final locations used in this analysis included the extradural vertebral artery ($n = 8$, 2.7%), intradural vertebral artery ($n = 116$, 38.5%), proximal PICA ($n = 20$, 6.6%), distal PICA ($n = 9$, 3.0%), vertebrobasilar junction (VBJ, $n = 53$, 17.6%), basilar trunk ($n = 51$, 16.9%), basilar apex ($n = 17$, 5.6%), and PCA ($n = 27$, 5.6%; Fig 1). Baseline demographic data for the final population and by aneurysm location are presented in the Online Supplemental Data. Significant differences were seen among the various aneurysm locations in nearly every baseline variable measured (Online Supplemental Data). Similarly, rates of major complications and angiographic occlusion as well as functional outcomes differed among aneurysm locations, with the VBJ and basilar trunk aneurysms associated with the highest rates of complications and poor outcomes, while the VBJ, basilar trunk, and proximal PICA aneurysms showed the lowest occlusion rates (Fig 1). Outcomes by demographic, aneurysm, and treatment factors are shown in the Online Supplemental Data.

Major complications were reported in 66 cases (21.9%) and included hemorrhagic (12 cases) and ischemic events (33 cases), symptomatic mass effect (5 cases), unspecified neurologic worsening (5 cases), and mortalities attributed to subarachnoid hemorrhage (7 cases), premorbid status (2 cases), and other medical comorbidities (2 cases, Online Supplemental Data). Of the 12

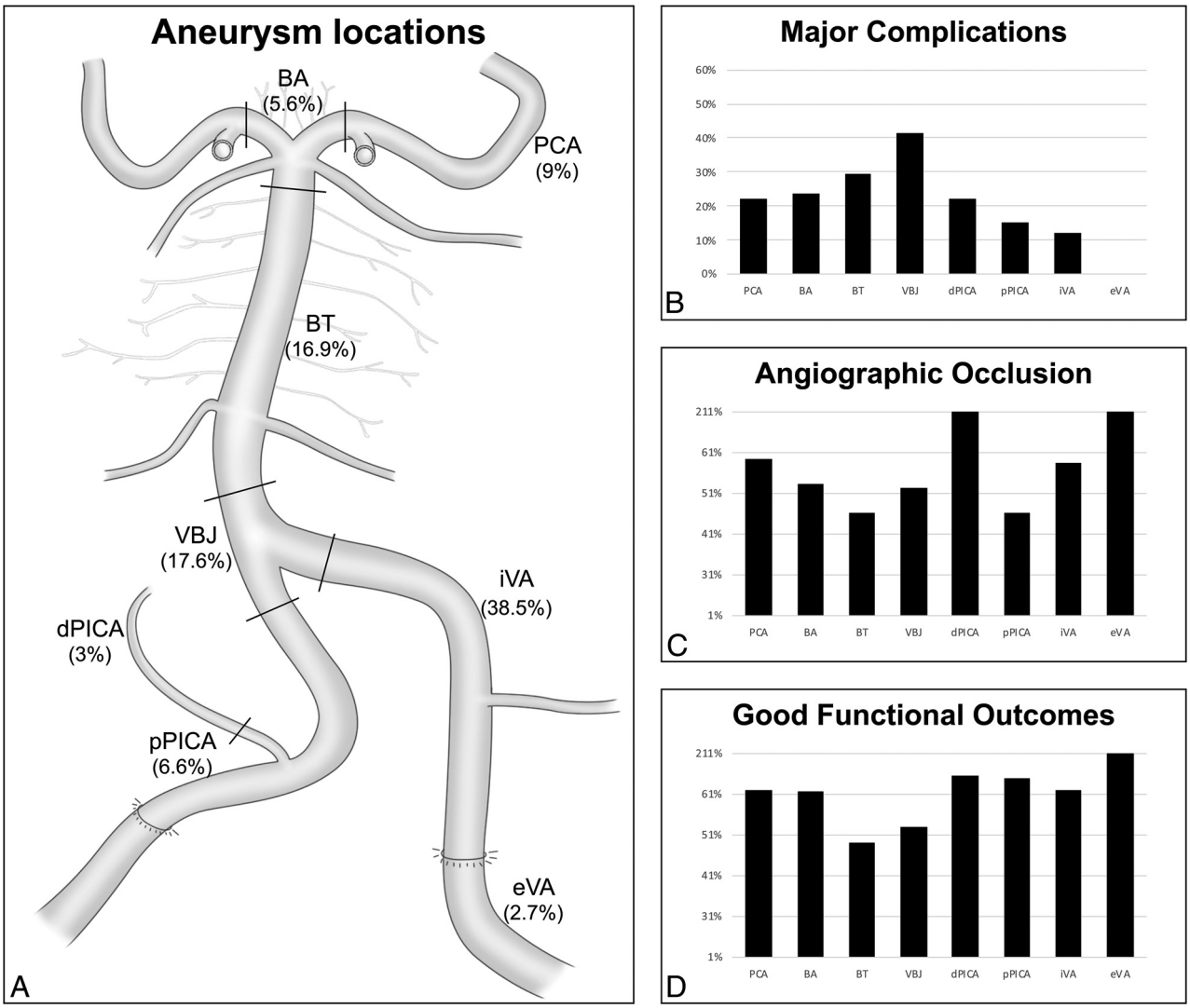

FIG 1. *A*, Final posterior circulation aneurysm locations included the extradural vertebral artery (eVA), intradural vertebral artery (iVA), proximal PICA (pPICA), distal PICA (dPICA), VBJ, basilar trunk (BT), basilar apex (BA), and the PCA. *B*, Proportion of major complications by aneurysm location. *C*, Proportion of angiographic occlusions by aneurysm location. *D*, Proportion of good functional outcomes (defined as mRS 0–2) by aneurysm location.

hemorrhagic complications, 2 were specifically attributed to aneurysm rerupture, one of which occurred after treatment of a giant fusiform basilar trunk aneurysm and the other after treatment of a large proximal PICA aneurysm. One hemorrhage occurred in a delayed fashion after treatment of a distal PICA aneurysm, while another reported hemorrhage was related to external ventricular drain placement in the setting of a ruptured aneurysm (Online Supplemental Data). Of the 33 ischemic complications, 12 were specifically related to in-stent thrombosis. Seven of these occurred intra- or periprocedurally, while the remainder occurred in a delayed fashion, ranging from 4.5 months to 4 years after flow-diversion treatment (Online Supplemental Data). In univariate analysis (Online Supplemental Data), age ($P = .01$), aneurysm location ($P = .009$), type ($P = .008$), size ($P = .006$), and the number of FDs 9 ($P < .001$) were all associated with the occurrence of major complications. Multivariate logistic regression (Online Supplemental Data) found only increasing age ($P = .006$) and the number of FDs ($P = .003$) to be significantly associated with a major complication, with increasing age and increasing number of FDs associated with higher aORs (1.04 and 1.54, respectively). Of note, rupture status was not associated with the occurrence of major complications.

Angiographic follow-up was reported in 288 cases (95.7%), with a mean angiographic follow-up time of 11.3 months (range, 1 day to 65 months; length of angiographic follow-up was not reported in 16%). Overall, complete aneurysm occlusion was reported in 196 cases (65.1%). Univariate analysis (Online Supplemental Data) identified age ($P = .004$), location ($P = .08$), size ($P < .001$), the use of adjunct coils ($P = .02$), and the number of FDs ($P = .03$) to be associated with angiographic outcomes. Although the omnibus test results for aneurysm types were nonsignificant, dissecting aneurysms were also found to have a significantly increased likelihood of occlusion compared with saccular aneurysms (OR = 2.23, $P = .02$). Multivariate logistic regression (Online Supplemental Data) found that only age ($P = .001$) and size ($P = .02$) remained significant predictors of angiographic

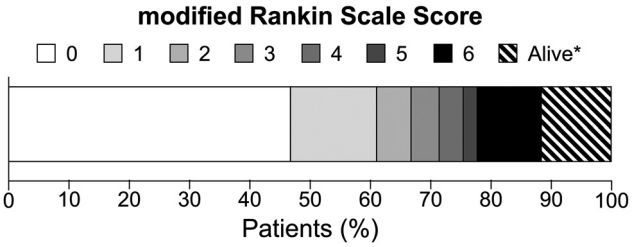

FIG 2. Overall long-term neurologic outcomes based on the mRS score. The *asterisk* indicates patients who did not have a reported neurologic outcome but had angiographic follow-up and were designated as alive.

occlusion in this cohort, with older age and giant aneurysms associated with decreased aneurysm occlusion (aOR = 0.96 and 0.19, respectively).

The mean time to clinical follow-up was 13.3 months (range, 1 day to 65 months; the length of the clinical follow-up time was not reported in 23.9%). Good functional outcomes (mRS 0–2) were reported in 201 cases (66.8%), and the overall mortality in this series was 10.6% (Fig 2). Thirty-five cases (11.6%) did not report on neurologic status but patients did have angiographic follow-up and were, therefore, designated as alive at the time of clinical follow-up and were not included in the outcome analysis. Univariate analysis (Online Supplemental Data) identified rupture status ($P = .03$); aneurysm location ($P = .02$); type ($P = .02$); size ($P = .001$); prior treatment ($P = .01$); and the number of FDs ($P < .001$) as factors associated with a dichotomized functional outcome (mRS 0–2 versus >2). Multivariate logistic regression (Online Supplemental Data) found that younger age ($P = .004$) and fewer FDs ($P < .001$) remained significantly associated with good functional outcome (aOR = 0.96 and 0.53, respectively). In addition, prior treatment significantly increased the likelihood of a good functional outcome (aOR = 3.7, $P = .04$). Rupture status was not significant in this analysis (aOR = 0.38, $P = .07$).

Meta-analyses were performed combining data from this study with other nonoverlapping studies reporting aggregated data of ≥10 cases of posterior circulation aneurysms treated with flow diversion.[12–18] Among 712 patients, the pooled incidence of major complications after treatment of posterior circulation aneurysms with flow diversion was 19.6% (95% CI, 15.3%–23.9%) with heterogeneity $I^2 = 42.9\%$ (Fig 3). A similar meta-analysis of angiographic outcomes in 581 patients found that complete aneurysm occlusion was achieved in 75.2% of cases (95% CI, 66.8%–83.6%) with heterogeneity $I^2 = 77.9\%$ (Fig 3).

DISCUSSION

The experience of flow diversion for the treatment of posterior circulation aneurysms is relatively limited compared with the anterior circulation. For example, the most recent published meta-analysis by Liang et al[10] combined 12 studies comprising 358 posterior circulation aneurysms treated with the PED to yield an 82% obliteration rate with an 18% complication rate. Posterior circulation aneurysms, however, represent an anatomically diverse group of aneurysms, with differing morphologic subtypes and technical challenges. To further investigate factors associated with the safety and efficacy of this treatment in posterior circulation aneurysms, we performed a systematic review of the literature to collect disaggregated, patient-level data and identified 301 individual cases of posterior circulation aneurysms treated with endoluminal flow diversion. This is the largest series of case-reported data to date, permitting more granular analysis of variables associated with complications, occlusion rates, and outcomes. Our findings reveal complications in 22%, angiographic occlusion in 65%, and good outcomes in 67%. Age, aneurysm size, prior treatment, and the number of flow diverters were significantly and independently associated with clinical and radiographic outcomes. We then performed a meta-analysis of prior large (≥10 patients) series,[12-18] demonstrating that our results are in line with prior aggregated studies and revealing an overall complication rate of 19.6% and a 75.2% occlusion rate (Fig 2).

Prior studies have shown that flow diversion in the posterior circulation can be performed successfully, albeit with higher inherent risks than in the anterior circulation. Several factors associated with complications and outcomes have been identified, including size, morphology, and the involvement of critical perforators.[19] As part of their meta-analysis, Liang et al[10] performed a meta-regression analysis and found that age was the only identifiable factor associated with angiographic outcomes. They found no factors associated with complications. The largest study in that meta-analysis was by Griessenauer et al,[14] who reported a retrospective multicenter series of 129 patients with posterior circulation aneurysms treated with the PED. They analyzed aneurysms separately by morphology (saccular, fusiform, and dissecting) and found very few factors associated with angiographic outcomes or complications. In fact, the only significant variable found on multivariate analysis was clopidogrel responsiveness, which was associated with complications in saccular aneurysms.

More recently, Lopes et al[16] reported a subgroup analysis of posterior circulation aneurysms from the International Retrospective Study of Pipeline Embolization Device (IntrePED) trial, a multicenter retrospective PED registry. They identified 91 patients with a mean follow-up of 21 months. Multivariate analysis identified fusiform morphology and the use of ≥3 PEDs as factors associated with combined neurologic morbidity and mortality. Aneurysm size was separately associated with morbidity, while the use of ≥3 PEDs, rupture status, and age were associated with mortality. Our data are consistent with these prior studies in that multivariate analysis identified only a few factors associated with outcomes. Increasing age was uniformly associated with higher procedural complications and poorer angiographic and functional outcomes, and advanced age has been associated with increased complications with interventional procedures in general.[20] Similar to findings in the IntrePED subgroup analysis,[16] multiple FDs were associated with increased complications and poor functional outcomes in our systematic review. Deployment of multiple FDs increases the technical complexity of an intervention and has been associated with a higher risk of complications in prior studies,[21] though a more recent analysis of this topic found no difference in complications with increasing PEDs.[22] The important association of multiple flow diverters with both complication rates and outcomes on multivariable analysis may indicate that this factor is a more relevant marker of aneurysm complexity than size, location, or morphology alone. However, these

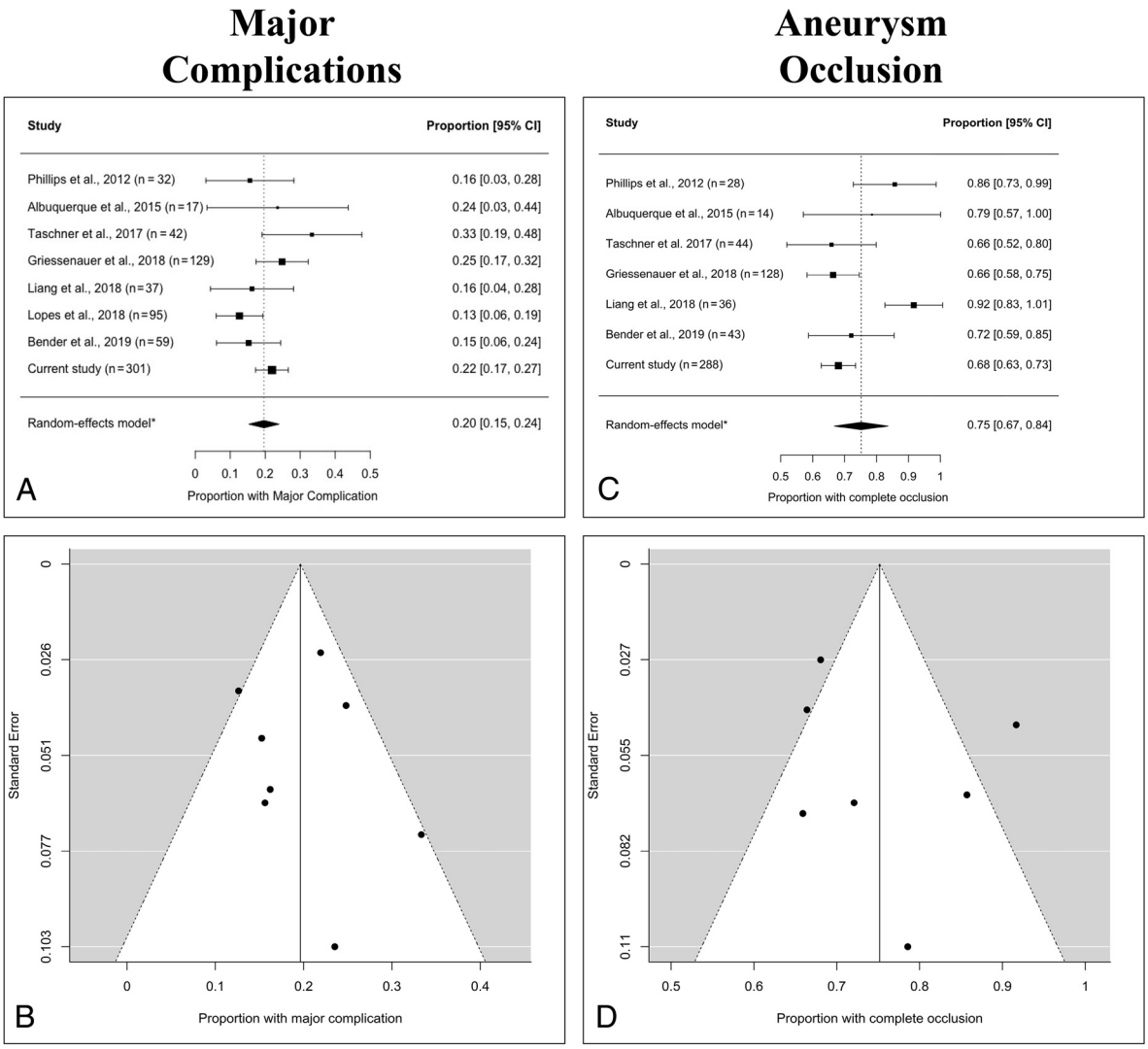

FIG 3. Meta-analysis of studies reporting flow diversion for posterior circulation aneurysms with ≥10 patients. *A*, Forest plot comparing the proportion of patients in each study with a reported major complication. The pooled incidence of major complications among 712 patients was 19.6%, with a heterogeneity $I^2 = 42.9\%$. *B*, Funnel plot of the included studies reporting major complications. *C*, Forest plot comparing angiographic aneurysm occlusion for the included studies. The pooled incidence of complete angiographic occlusion among 594 patients was 75.2%, with a heterogeneity $I^2 = 77.9\%$. *D*, Funnel plot of the included studies reporting angiographic outcomes.

findings should not discount the importance of size, location, and morphology, and additional studies will be required to further investigate these factors.

Most important, while we found no significant differences in outcomes among aneurysms of different locations on multivariable analysis, significant differences in complication rates and outcomes across aneurysm locations were found on univariate analysis (Online Supplemental Data and Fig 1). These univariate differences highlight the different pathologies, anatomy, and technical challenges of treatment with flow diversion predicted by each posterior circulation aneurysm subtype. For example, VBJ and basilar trunk aneurysms have poor natural histories[23,24] but also pose significant treatment challenges regardless of treatment technique.[24-26] In our series, these aneurysms had the highest proportions of giant and fusiform morphologies and were treated with the greatest number of FDs. They, similarly, had the poorest outcomes (Fig 1). Conversely, vertebral artery aneurysms have a relatively benign natural history,[27] and endovascular treatment is known to be safe and effective.[28] Other unique challenges encountered in the posterior circulation include the bifurcation configuration of basilar apex aneurysms, which were the most likely to require adjunct coiling in our series, and distal locations of PICA and PCA aneurysms.

In the United States, the use of the PED for posterior circulation aneurysms remains off-label, though this device was used in most cases (85% in our series). Similarly, the FRED is approved in the United States for use with wide-neck and fusiform internal carotid artery aneurysms from the petrous segment to the terminus. The Surpass Streamline Flow Diverter has approval for the treatment of unruptured large and giant wide-neck intracranial aneurysms, including those in the posterior circulation. Other flow-diverting devices, including the p64, Derivo, and Tubridge are not yet approved for use in the United States. The decision to

use flow diversion to treat posterior circulation aneurysms must be made in the context of other possible treatments. Before the widespread use of flow diversion, several studies evaluated the safety of surgical management,[26,29,30] which includes direct clipping or reconstruction, as well as proximal occlusion, bypass occlusion, and wrapping. Reported favorable neurologic outcomes range from 55% to 90%, depending on location and series.[26] Before flow diversion, endovascular options included primary coil embolization, stent- or balloon-assisted coil embolization, and vessel sacrifice. Favorable outcomes for endovascular treatment similarly range from 67% to 100%, again depending on location.[26] The ultimate choice of treatment technique must be based on individual anatomic, patient, and treating physician factors. Off-label use of flow diversion should be discussed with patients, even if it is considered the optimal treatment method.

We acknowledge several limitations to this study design. First and foremost, this systematic review identified data from case reports or small series and is, therefore, susceptible to publication bias. Case reports are often published to describe a novel approach, an unusual disease presentation, a notable complication, or an exceptional treatment outcome. Given the relative rarity of flow diversion for posterior circulation aneurysms and the novelty and controversy of this treatment in this population, it is reasonable to think that a substantial proportion of such cases have led to publication. A compilation of published case reports and series of flow diversion for posterior circulation aneurysms may, therefore, be a reasonable reflection of the overall population. This is supported by our meta-analysis (Fig 3), which shows similar findings in our series compared with prior large series of a similar patient population. Second, FD use has evolved across time with different generations of devices and increasing experience and skill— factors that could not be analyzed with our study design. Finally, antiplatelet therapy is a critical component of flow diversion. Antiplatelet responsiveness has been associated with complications in flow diversion of cerebral aneurysms— nonresponsiveness is associated with thrombotic complications, while hyper-responsiveness is associated with hemorrhagic complications.[31] This association has also been specifically demonstrated with flow diversion of posterior circulation aneurysms.[14] Unfortunately, our study design did not allow uniform assessment of antiplatelet management. This critical factor, however, warrants further study.

CONCLUSIONS

Endoluminal flow diversion is an important tool in the treatment of posterior circulation aneurysms. Although such aneurysms comprise a diverse set of anatomic configurations, these data suggest that increasing age and the use of multiple FDs are critical factors associated with procedural complications and neurologic outcomes, outweighing aneurysm location on multivariate analysis. Continued evaluation of endoluminal flow diversion in the treatment of posterior circulation aneurysms is warranted.

REFERENCES

1. Chancellor B, Raz E, Shapiro M, et al. **Flow diversion for intracranial aneurysm treatment: trials involving flow diverters and long-term outcomes.** *Neurosurgery* 2020;86:S36–45 CrossRef Medline
2. International Study of Unruptured Intracranial Aneurysms Investigators. **Unruptured intracranial aneurysms: risk of rupture and risks of surgical intervention.** *N Engl J Med* 1998;339:1725–33 CrossRef Medline
3. Pumar JM, Garcia-Dorrego R, Nieto A, et al. **Vascular reconstruction of a fusiform basilar aneurysm with the Silk embolization system.** *J Neurointerv Surg* 2010;2:242–44 CrossRef Medline
4. Fiorella D, Kelly ME, Albuquerque FC, et al. **Curative reconstruction of a giant midbasilar trunk aneurysm with the Pipeline Embolization Device.** *Neurosurgery* 2009;64:212–17; discussion 217 CrossRef Medline
5. Klisch J, Turk A, Turner R, et al. **Very late thrombosis of flow-diverting constructs after the treatment of large fusiform posterior circulation aneurysms.** *AJNR Am J Neuroradiol* 2011;32:627–32 CrossRef Medline
6. Fiorella D, Hsu D, Woo HH, et al. **Very late thrombosis of a Pipeline Embolization Device construct: case report.** *Neurosurgery* 2010;67:onsE313–14; discussion onsE314 CrossRef Medline
7. Siddiqui AH, Abla AA, Kan P, et al. **Panacea or problem: flow diverters in the treatment of symptomatic large or giant fusiform vertebrobasilar aneurysms.** *J Neurosurg* 2012;116:1258–66 CrossRef Medline
8. Wiebers DO, Whisnant JP, Huston J 3rd et al. **Unruptured intracranial aneurysms: natural history, clinical outcome, and risks of surgical and endovascular treatment.** *Lancet* 2003;362:103–10 CrossRef Medline
9. Raaymakers TW, Rinkel GJ, Limburg M, et al. **Mortality and morbidity of surgery for unruptured intracranial aneurysms: a meta-analysis.** *Stroke* 1998;29:1531–38 CrossRef Medline
10. Liang F, Zhang Y, Yan P, et al. **Outcomes and complications after the use of the Pipeline Embolization Device in the treatment of intracranial aneurysms of the posterior circulation: a systematic review and meta-analysis.** *World Neurosurg* 2019;127:e888–95 CrossRef Medline
11. Moher D, Liberati A, Tetzlaff J, et al. The PRISMA Group. **Preferred reporting items for systematic reviews and meta-analyses: the PRISMA statement.** *PLoS Med* 2009;6:e1000097 CrossRef Medline
12. Albuquerque FC, Park MS, Abla AA, et al. **A reappraisal of the Pipeline Embolization Device for the treatment of posterior circulation aneurysms.** *J Neurointerv Surg* 2015;7:641–45 CrossRef Medline
13. Bender MT, Colby GP, Jiang B, et al. **Flow diversion of posterior circulation cerebral aneurysms: a single-institution series of 59 cases.** *Neurosurgery* 2019;84:206–16 CrossRef Medline
14. Griessenauer CJ, Ogilvy CS, Adeeb N, et al. **Pipeline embolization of posterior circulation aneurysms: a multicenter study of 131 aneurysms.** *J Neurosurg* 2018;130:923–35 CrossRef Medline
15. Liang F, Zhang Y, Guo F, et al. **Use of Pipeline Embolization Device for posterior circulation aneurysms: single-center experiences with comparison with anterior circulation aneurysms.** *World Neurosurg* 2018;112:e683–90 CrossRef Medline
16. Lopes DK, Jang DK, Cekirge S, et al. **Morbidity and mortality in patients with posterior circulation aneurysms treated with the Pipeline embolization device: a subgroup analysis of the international retrospective study of the Pipeline Embolization Device.** *Neurosurgery* 2018;83:488–500 CrossRef Medline
17. Phillips TJ, Wenderoth JD, Phatouros CC, et al. **Safety of the Pipeline Embolization Device in treatment of posterior circulation aneurysms.** *AJNR Am J Neuroradiol* 2012;33:1225–31 CrossRef Medline
18. Taschner CA, Vedantham S, de Vries J, et al. **Surpass flow diverter for treatment of posterior circulation aneurysms.** *AJNR Am J Neuroradiol* 2017;38:582–89 CrossRef Medline
19. Adeeb N, Ogilvy CS, Griessenauer CJ, et al. **Expanding the indications for flow diversion: treatment of posterior circulation aneurysms.** *Neurosurgery* 2020;86:S76–84 CrossRef Medline

20. Khosla A, Brinjikji W, Cloft H, et al. **Age-related complications following endovascular treatment of unruptured intracranial aneurysms.** *AJNR Am J Neuroradiol* 2012;33:953–57 CrossRef Medline
21. Chalouhi N, Tjoumakaris S, Phillips JL, et al. **A single Pipeline Embolization Device is sufficient for treatment of intracranial aneurysms.** *AJNR Am J Neuroradiol* 2014;35:1562–66 CrossRef Medline
22. Waqas M, Vakharia K, Gong AD, et al. **One and done? The effect of number of Pipeline embolization devices on aneurysm treatment outcomes.** *Interv Neuroradiol* 2020;26:147–55 CrossRef Medline
23. Kobayashi N, Murayama Y, Yuki I, et al. **Natural course of dissecting vertebrobasilar artery aneurysms without stroke.** *AJNR Am J Neuroradiol* 2014;35:1371–75 CrossRef Medline
24. Saliou G, Sacho RH, Power S, et al. **Natural history and management of basilar trunk artery aneurysms.** *Stroke* 2015;46:948–53 CrossRef Medline
25. Sonmez O, Brinjikji W, Murad MH, et al. **Deconstructive and reconstructive techniques in treatment of vertebrobasilar dissecting aneurysms: a systematic review and meta-analysis.** *AJNR Am J Neuroradiol* 2015;36:1293–98 CrossRef Medline
26. Sanai N, Tarapore P, Lee AC, et al. **The current role of microsurgery for posterior circulation aneurysms: a selective approach in the endovascular era.** *Neurosurgery* 2008;62:1236–49; discussion 1249–53 CrossRef Medline
27. Kim BM, Kim SH, Kim DI, et al. **Outcomes and prognostic factors of intracranial unruptured vertebrobasilar artery dissection.** *Neurology* 2011;76:1735–41 CrossRef Medline
28. Guan J, Li G, Kong X, et al. **Endovascular treatment for ruptured and unruptured vertebral artery dissecting aneurysms: a meta-analysis.** *J Neurointerv Surg* 2017;9:558–63 CrossRef Medline
29. Drake CG, Peerless SJ. **Giant fusiform intracranial aneurysms: review of 120 patients treated surgically from 1965 to 1992.** *J Neurosurg* 1997;87:141–62 CrossRef Medline
30. Coert BA, Chang SD, Do HM, et al. **Surgical and endovascular management of symptomatic posterior circulation fusiform aneurysms.** *J Neurosurg* 2007;106:855–65 CrossRef Medline
31. Tonetti DA, Jankowitz BT, Gross BA. **Antiplatelet therapy in flow diversion.** *Neurosurgery* 2020;86:S47–52 CrossRef Medline