

Are your **MRI contrast agents** cost-effective?

Learn more about generic **Gadolinium-Based Contrast Agents**.



**FRESENIUS
KABI**

caring for life

AJNR

Retrospective Analysis of the Association of a Small Vestibular Aqueduct with Cochleovestibular Symptoms in a Large, Single-Center Cohort Undergoing CT

K. Bouhadjer, L.V. Romo, M.J. Brennan, B.M. Kozak, E. Hattingen, A.F. Juliano, H.D. Curtin and K.L. Reinshagen

This information is current as of April 19, 2024.

AJNR Am J Neuroradiol 2023, 44 (1) 70-73

doi: <https://doi.org/10.3174/ajnr.A7734>

<http://www.ajnr.org/content/44/1/70>

Retrospective Analysis of the Association of a Small Vestibular Aqueduct with Cochleovestibular Symptoms in a Large, Single-Center Cohort Undergoing CT

 K. Bouhadjer,  L.V. Romo,  M.J. Brennan,  B.M. Kozak,  E. Hattingen,  A.F. Juliano,  H.D. Curtin, and  K.L. Reinshagen

ABSTRACT

BACKGROUND AND PURPOSE: Temporal bones in some patients with Ménière disease have demonstrated small vestibular aqueducts; however, the prevalence and clinical importance of small vestibular aqueducts remain unclear in patients without Ménière disease. This study correlates the presence of a small vestibular aqueduct with cochleovestibular symptoms.

MATERIALS AND METHODS: Consecutive temporal bone CTs in adults from January to December 2020 were reviewed. The midpoint vestibular aqueduct size in the 45°-oblique Pöschl view was measured by 2 reviewers independently in 684 patients (1346 ears). Retrospective chart review for the clinical diagnosis of Ménière disease, the presence of cochleovestibular symptoms, and indications for CT was performed.

RESULTS: Fifty-two of 684 patients (7.6% of patients, 62/1346 ears) had small vestibular aqueducts. Twelve patients (15/1346 ears) had Ménière disease. Five of 12 patients with Ménière disease (5 ears) had a small vestibular aqueduct. There was a significant correlation between a small vestibular aqueduct and Ménière disease ($P < .001$). There was no statistical difference between the small vestibular aqueduct cohort and the cohort with normal vestibular aqueducts (0.3–0.7 mm) regarding tinnitus ($P = .06$), hearing loss ($P = .88$), vertigo ($P = .26$), dizziness ($P = .83$), and aural fullness ($P = .61$).

CONCLUSIONS: While patients with Ménière disease were proportionately more likely to have a small vestibular aqueduct than patients without Ménière disease, the small vestibular aqueduct was more frequently seen in patients without Ménière disease and had no correlation with hearing loss, vertigo, dizziness, or aural fullness. We suggest that the finding of a small vestibular aqueduct on CT could be reported by radiologists as a possible finding in Ménière disease, but it remains of uncertain, and potentially unlikely, clinical importance in the absence of symptoms of Ménière disease.

ABBREVIATIONS: VA = vestibular aqueduct; MD = Ménière disease

The vestibular aqueduct (VA) is a small, bony channel in the posterior petrous temporal bone, which encloses the endolymphatic duct and a portion of the endolymphatic sac. Dysfunctions of the endolymphatic sac and duct are intimately related to the surrounding VA.¹ Based on normative data, the midpoint VA size in the 45° oblique Pöschl plane ranges from 0.3 to 0.7 mm.² Enlarged vestibular aqueducts may be seen in the setting of underlying cochlear malformations, and subtle changes in size can be associated with impairment of hearing and balance.³⁻⁵ An enlarged

VA has been associated with sensorineural hearing loss, though the exact pathogenesis is thought to be multifactorial and is not fully understood.^{3,6-10} The clinical importance of a small VA, however, remains unclear. Temporal bones in some patients with Ménière disease (MD), a disorder of the inner ear, characterized by episodes of vertigo, fluctuating hearing loss, tinnitus, and aural fullness, have demonstrated thin or narrow VAs.¹¹⁻¹⁹ The clinical diagnosis of MD is dichotomized into definite or probable MD. Definite MD requires the following: 1) ≥ 2 episodes of vertigo lasting 20 minutes to 12 hours; 2) low- to medium-frequency sensorineural hearing loss in the affected ear on at least 1 occasion before, during, or after one of the episodes of vertigo; 3) fluctuating aural symptoms (hearing, tinnitus, or fullness) in the affected ear; and 4) exclusion of other known causes. The clinical diagnosis of probable MD requires the following: 1) ≥ 2 episodes of vertigo or dizziness lasting 20 minutes to 24 hours; 2) fluctuating aural symptoms in the affected ear; and 3) exclusion of other known causes.²⁰ The

Received July 19, 2022; accepted after revision November 4.

From the Department of Radiology (K.B., L.V.R., M.J.B., A.F.J., H.D.C., K.L.R.), Massachusetts Eye and Ear, Boston, Massachusetts; Neuroradiology Division (B.M.K.), Massachusetts General Hospital, Boston, Massachusetts; and Institut für Neuroradiologie (E.H.), Universitätsmedizin der Goethe Universität Frankfurt, Frankfurt am Main, Germany.

Please address correspondence to Katherine L. Reinshagen, MD, Department of Radiology, 243 Charles St, Massachusetts Eye and Ear, Boston, MA 02114; e-mail: katherine_reinshagen@meei.harvard.edu; @klreinshagen

<http://dx.doi.org/10.3174/ajnr.A7734>

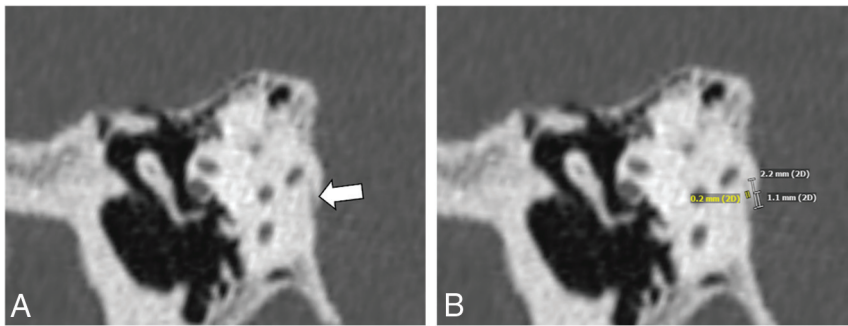


FIGURE Representative Pöschl reformatted multidetector CT image of a 59-year-old patient shows a small VA (A, white arrow) with measurement (0.2 mm) at the midpoint (B).

Table 1: Indications for CT in the 52 patients with small VAs

Indication	No. of Patients
Cochlear implant follow-up or preop planning	10
Cholesteatoma	8
Hearing loss	6
Superior semicircular canal dehiscence	5
Tinnitus	3
Dizziness	3
Infection	3
Patulous eustachian tube	2
Otosclerosis	2
Aural fullness	2
Otorrhea	2
Ossicular anomaly	1
Osteoradionecrosis	1
Tympanic membrane perforation	1
Disequilibrium	1
Vestibular schwannoma	1
Ménière disease	1

Note:—Preop indicates preoperative.

pathogenesis of MD is still unclear but elevated endolymphatic pressure and endolymphatic hydrops are commonly accepted as important associations.

The purpose of this study was to explore the prevalence of small VAs found on temporal bone CTs and the correlation of small VAs with cochleovestibular symptoms and the presence of MD.

MATERIALS AND METHODS

Subjects

This retrospective study received approval (institutional review board No. 2020P003465) from the Massachusetts General Brigham Institutional Review Board. Inclusion criteria were patients 18–95 years of age who underwent dedicated multidetector CT or cone-beam CT of the temporal bone from January 2020 to December 2020 at Massachusetts Eye and Ear. Seven hundred seventy-three CT scans were reviewed. Forty CTs were excluded because these patients underwent >1 CT in the 1-year period of study and only 1 study was included for each patient. Forty-nine CTs were excluded due to motion artifacts preventing accurate measurement of the VA. Six hundred eighty-four patients (1346 ears) were included in the study. Twenty-two patients underwent single-sided conebeam CT of the temporal bones accounting for the discrepancy between

ears and patients. We reviewed the patients' medical records for a clinical diagnosis of definite or probable MD, the presence of dizziness or vertigo, aural fullness, tinnitus, hearing loss, and the indication for the performed CT scan.

Imaging Acquisition

Multidetector CT (Discovery CT750 HD; GE Healthcare) of the temporal bone was performed with 120 kV (peak), 240 mA, FOV = 100 × 100 mm, matrix = 512 × 512, 0.6-mm section thickness with 0.3-mm overlap.

Conebeam CT (3D Accuitomo; J Morita) of the temporal bone was performed with a 90-kV(peak), 8-mA, high-resolution mode with an exposure time of 30.8 seconds, FOV = 64 × 64 mm, matrix = 512 × 512, 0.5-mm section thickness.

Reader Assessment

Two observers retrospectively assessed the midpoint VA size in the 45° oblique Pöschl plane view (Figure). On the basis of Juliano et al,² VA sizes <0.3 mm were reviewed by consensus and considered borderline small-to-small VAs.

Statistical Analysis

Statistical analysis was performed using the R statistical and computing software, Version 4.0.4 (<https://www.r-project.org>). The Fisher exact test was used to assess the association between the presence of a small VA and clinical symptomatology. *P* values < .05 were considered statistically significant.

RESULTS

In this study, 684 patients (mean age, 53 years; range, 18–95 years; 315 men [46%], 369 women [54%]) were included. Fifty-two patients (7.6% of patients; 62 ears, 4.6% of ears) had VAs ranging from nonvisible to borderline small (10 bilateral, 42 unilateral). Twelve ears had nonvisible VAs, whereas 50 ears had visible VAs of <0.3 mm. Enlarged VAs were observed in 39 patients (range, 0.8–3.2 mm; 14 bilateral, 25 unilateral). A VA within the expected normal range of 0.3–0.7 mm was observed in 593 patients (1168 ears).

Of these 52 patients with nonvisible-to-borderline small VAs, 33 patients (63.5%) had hearing loss: sensorineural (13 patients), conductive (7 patients), or mixed hearing loss (6 patients). Seven patients had hearing loss that was unspecified by type in the medical record. Five patients had a history of cholesteatoma. Vestibular symptoms in the 52 patients with nonvisible-to-borderline small VAs were reported as follows: dizziness (6 patients, 11.5%) and vertigo (6 patients, 11.5%). Both dizziness and vertigo were reported in 3 patients. Nine patients reported tinnitus (17%). The indication for CT of the 52 patients with nonvisible-to-borderline small VAs is listed in Table 1.

The distribution of cochleovestibular symptoms by VA size is listed in Table 2. The distribution of the type of hearing loss by VA size is listed in Table 3. Twelve patients (15 of 1346 ears)

Table 2: Distribution of patients with cochleovestibular symptoms by VA size

VA Size	Total (No.)	MD (No.)	Tinnitus (No.)	Dizziness (No.)	Vertigo (No.)	Aural Fullness (No.)
<0.3 mm	52	5	9	6	6	0
0.3 mm ≤ x ≤ 0.7 mm	593	7	182	79	41	13
>0.7 mm	39	0	14	2	2	1

Table 3: Distribution of patients by hearing loss type and VA size

VA Size	Total Patients (No.)	HL (No.)	SNHL (No.)	CHL (No.)	MHL (No.)	UHL (No.)
<0.3 mm	52	33	13	7	6	7
0.3 mm ≤ x ≤ 0.7 mm	593	364	132	100	54	78
>0.7 mm	39	27	12	6	1	8

Note:—HL indicates hearing loss; SNHL, sensorineural hearing loss; CHL, conductive hearing loss; MHL, mixed hearing loss; UHL, unspecified hearing loss.

Table 4: Comparison of VA size and presence of MD by number of ears

VA Size	Total No. Ears	MD
<0.3 mm	62	5
0.3 mm ≤ x ≤ 0.7 mm	1231	10
>0.7 mm	53	0

were affected by MD with 5 ears having a small VA (Table 4). Although small VAs can be seen in ears without MD, there was a statistically significant correlation between small or nonvisible VAs and MD (5 of 62 ears with a small VA had MD compared with 10 of 1231 ears with a normal-sized VA having MD; Fisher exact test, $P < .001$). No patients with MD had an enlarged VA. There was no statistical difference between patients with small VAs and patients with normal-sized VAs with regard to a reported history of tinnitus ($P = .06$), vertigo ($P = .26$), dizziness ($P = .83$), aural fullness ($P = .61$), the presence of hearing loss ($P = .88$), or a specific type of hearing loss (conductive hearing loss, $P = .69$; sensorineural hearing loss, $P = .61$; mixed hearing loss, $P = .62$; and unspecified hearing loss, $P > .99$).

DISCUSSION

An enlarged VA is well-described in the literature and is seen in genetic syndromes like Pendred syndrome and in cochlear anomalies such as incomplete partition type II. Enlarged VAs have been correlated with adverse hearing outcomes, and recent studies have shown that VA size correlates negatively with hearing outcomes (pure tone average, speech reception threshold, and word-recognition score).^{6,21} Because of its clinical implications, the finding of an enlarged VA is typically reported by radiologists. In contrast, a small or nonvisible VA has not been reported regularly in our practice because the clinical importance of small VAs in patients without MD remains unclear.

The etiology of the small or hypoplastic VA is incompletely understood. It has been hypothesized that a small VA may be due to congenital hypoplasia of the VA and endolymphatic sac.^{22,23} While the correlation of a small VA and MD has been the focus of many studies, our study attempted to understand the finding of a small VA in a broader clinical context and ultimately understand whether this finding is important to the encountering radiologist. As expected, our data confirm the significant correlation between small VAs and MD in a large cohort of 684 patients as seen in smaller prior studies.^{16,18,19,24,25} A small VA can lead to endolymphatic hydrops, which is strongly associated with MD.

However, in our cohort, 10 of 15 ears (67%) affected by MD had normal-sized VAs, suggesting that the development of MD is likely multifactorial. Most ears (57 of 62, 92%) in our cohort with small VAs did not have MD at the time of imaging. In addition, no significant difference was found regarding the presence of cochleovestibular symptoms such as vertigo ($P = .26$), dizziness ($P = .83$), aural fullness ($P = .61$), and tinnitus (0.06) between patients with normal-sized VAs and those with small VAs. Therefore, although the finding of a small or nonvisible VA should prompt consideration of MD when encountered by the radiologist, in the absence of symptoms of MD, a small VA is more commonly seen in patients without MD and has no correlation with other cochleovestibular symptoms in our cohort.

Limitations

Our results have some limitations. Due to the retrospective cross-sectional study design, the major limitation of this study is that CT scans were acquired at a single time point in the patient's clinical course; therefore, our data can only provide the prevalence of MD or other cochleovestibular symptoms in our patients at the time of CT. This limitation is particularly noteworthy because a hallmark of MD is its fluctuating and progressive nature and MD attacks possibly being spread out by periods of remission lasting months to years. Thus, the diagnosis of MD may require longer-term follow-up.^{26,27} Future studies assessing longitudinal data in the medical record during a lengthy period would be imperative to understand whether the presence of a small VA places a person at risk of developing MD or other cochleovestibular symptoms.

In addition, the measurements of VAs made in this study reflect the size of the midpoint and do not analyze the morphology or other VA-related information such as angular trajectory as introduced by Bächinger et al.²⁸ Most interesting, angular trajectory measurements of the VA have recently been shown to be predictive of progression of unilateral MD to bilateral MD, though their prediction of disease from asymptomatic patients to MD has not yet been established.²⁹ Measurement of the angular trajectory of the VA is more labor-intensive and is challenging in the setting of nonvisible VAs. We chose to use measurements in the Pöschl plane view because they can be made easily with high interrater reliability.² Future studies using the angular trajectory in patients without MD and assessing their progression to MD could be a valuable addition to the literature.

Finally, although this study has a large sample size, all patients had conditions that required care at a tertiary care center and

temporal bone CTs. Thus, the data are subject to selection bias, which may affect our conclusions and limit our ability to extract the true prevalence of a small VA in the general population. In our cohort, the overall prevalence of small VAs was higher than expected in the general population, possibly due to selection bias. On the basis of normative data from Juliano et al,² we should have expected 3% of the study population to have small VAs; however, in our cohort, 7.6% of patients (4.6% of ears) had small VAs. Future studies could consider assessing the prevalence of a small VA in nontemporal bone CTs, though precise measurements of the VA are often challenging in nondedicated temporal bone studies due to its inherent shape and small size.

CONCLUSIONS

In our large cohort of consecutive patients undergoing temporal bone imaging, small or nonvisible VAs were seen in up to 7.6% of our patients (52 of 684 patients) or 4.6% of ears (62 of 1346 ears). While patients with MD were proportionately more likely to have a small VA than patients without MD, the small VA was more frequently seen in patients without MD and had no correlation with hearing loss, vertigo, dizziness, or aural fullness. We suggest that small or nonvisible VAs on CT scans should be considered by radiologists as a possible finding in MD, though this finding at a single time point remains of uncertain, and potentially unlikely, clinical importance in the absence of MD or MD symptoms.

Disclosure forms provided by the authors are available with the full text and PDF of this article at www.ajnr.org.

REFERENCES

- Kodama A, Sando I. Postnatal development of the vestibular aqueduct and endolymphatic sac. *Ann Otol Rhinol Laryngol Suppl* 1982;96:3–12 [Medline](#)
- Juliano AF, Ting EY, Mingkwansook V, et al. Vestibular aqueduct measurements in the 45° oblique (Pöschl) plane. *AJNR Am J Neuroradiol* 2016;37:1331–37 [CrossRef Medline](#)
- Irving RM, Jackler RK. Large vestibular aqueduct syndrome. *Current Opinion in Otolaryngology & Head and Neck Surgery* 1997;5:267–71
- Reinshagen KL, Curtin HD, Quesnel AM, et al. Measurement for detection of incomplete partition type II anomalies on MR imaging. *AJNR Am J Neuroradiol* 2017;38:2003–07 [CrossRef Medline](#)
- Bouhadjer K, Tissera K, Farris CW, et al. Retrospective review of mid-point vestibular aqueduct size in the 45° oblique (Pöschl) plane and correlation with hearing loss in patients with enlarged vestibular aqueduct. *AJNR Am J Neuroradiol* 2021;42:2215–21 [CrossRef Medline](#)
- Pryor SP, Madeo AC, Reynolds JC, et al. SLC26A4/PDS genotype-phenotype correlation in hearing loss with enlargement of the vestibular aqueduct (EVA): evidence that Pendred syndrome and non-syndromic EVA are distinct clinical and genetic entities. *J Med Genet* 2005;42:159–65 [CrossRef Medline](#)
- Madden C, Halsted M, Meinzen-Derr J, et al. The influence of mutations in the SLC26A4 gene on the temporal bone in a population with enlarged vestibular aqueduct. *Arch Otolaryngol Head Neck Surg* 2007;133:162–68 [CrossRef Medline](#)
- Birkenhäger R, Zimmer AJ, Maier W, et al. Evidence of a novel gene for the LAV-syndrome [in German]. *Laryngorhinootologie* 2007;86:102–06 [CrossRef Medline](#)
- Zhao FF, Lan L, Wang DY, et al. Correlation analysis of genotypes, auditory function, and vestibular size in Chinese children with enlarged vestibular aqueduct syndrome. *Acta Otolaryngol* 2013;133:1242–49 [CrossRef Medline](#)
- Merchant SN, Rosowski JJ. Conductive hearing loss caused by third-window lesions of the inner ear. *Otol Neurotol* 2008;29:282–89 [CrossRef Medline](#)
- Rizvi SS, Smith LE. Idiopathic endolymphatic hydrops and the vestibular aqueduct. *Ann Otol Rhinol Laryngol* 1981;90:77–79 [CrossRef Medline](#)
- Sando I, Ikeda M. The vestibular aqueduct in patients with Meniere's disease: a temporal bone histopathological investigation. *Acta Otolaryngol* 1984;97:558–70 [CrossRef Medline](#)
- Stahle J, Wilbrand HF, Rask-Andersen H. Temporal bone characteristics in Meniere's disease. *Ann N Y Acad Sci* 1981;374:794–807 [CrossRef Medline](#)
- Stahle J, Wilbrand H. The vestibular aqueduct in patients with Meniere's disease: a tomographic and clinical investigation. *Acta Otolaryngol* 1974;78:36–48 [CrossRef Medline](#)
- Masutani H, Takahashi H, Sando I, et al. Vestibular aqueduct in Meniere's disease and non-Menièr's disease with endolymphatic hydrops: a computer aided volumetric study. *Auris Nasus Larynx* 1991;18:351–57 [CrossRef Medline](#)
- Kodama A, Sando I. Dimensional anatomy of the vestibular aqueduct and the endolymphatic sac (rugose portion) in human temporal bones: statistical analysis of 79 bones. *Ann Otol Rhinol Laryngol Suppl* 1982;96:13–20 [Medline](#)
- Clemis JD, Valvassori GE. Recent radiographic and clinical observations on the vestibular aqueduct: (a preliminary report). *Otolaryngol Clin North Am* 1968;1:339–52 [CrossRef](#)
- Grosser D, Willenborg K, Dellani P, et al. Vestibular aqueduct size correlates with the degree of cochlear hydrops in patients with and without Meniere's disease. *Otol Neurotol* 2021;42:e1532–36 [CrossRef Medline](#)
- Miyashita T, Toyama Y, Inamoto R, et al. Evaluation of the vestibular aqueduct in Ménière's disease using multiplanar reconstruction images of CT. *Auris Nasus Larynx* 2012;39:567–71 [CrossRef Medline](#)
- Lopez-Escamez JA, Carey J, Chung WH, et al; Korean Balance Society. Diagnostic criteria for Meniere's disease. *J Vestib Res* 2015;25:1–7 [CrossRef Medline](#)
- Ascha MS, Manzoor N, Gupta A, et al. Vestibular aqueduct mid-point width and hearing loss in patients with an enlarged vestibular aqueduct. *JAMA Otolaryngol Head Neck Surg* 2017;143:601–08 [CrossRef Medline](#)
- Egami T, Sando I, Black FO. Hypoplasia of the vestibular aqueduct and endolymphatic sac in endolymphatic hydrops. *Otolaryngology* 1978;86:ORL327–39 [CrossRef Medline](#)
- Hebbar GK, Rask-Andersen H, Linthicum FH. Three-dimensional analysis of 61 human endolymphatic ducts and sacs in ears with and without Meniere's disease. *Ann Otol Rhinol Laryngol* 1991;100:219–25 [CrossRef Medline](#)
- Krombach GA, van den Boom M, Di Martino E, et al. Computed tomography of the inner ear: size of anatomical structures in the normal temporal bone and in the temporal bone of patients with Meniere's disease. *Eur Radiol* 2005;15:1505–13 [CrossRef Medline](#)
- Maiolo V, Savastio G, Modugno GC, et al. Relationship between multidetector CT imaging of the vestibular aqueduct and inner ear pathologies. *Neuroradiol J* 2013;26:683–92 [CrossRef Medline](#)
- Basura GJ, Adams ME, Monfared A, et al. Clinical practice guideline: Ménière's disease. *Otolaryngol Head Neck Surg* 2020;162:S1–55 [PMC](#) [CrossRef Medline](#)
- Watanabe Y, Mizukoshi K, Shojaku H, et al. Epidemiological and clinical characteristics of Meniere's disease in Japan. *Acta Otolaryngol Suppl* 1995;519:206–10 [CrossRef Medline](#)
- Bächinger D, Luu NN, Kempfle JS, et al. Vestibular aqueduct morphology correlates with endolymphatic sac pathologies in Meniere's disease: a correlative histology and computed tomography study. *Otol Neurotol* 2019;40:e548–55 [CrossRef Medline](#)
- Bächinger D, Schuknecht B, Dlugaczky J, et al. Radiological configuration of the vestibular aqueduct predicts bilateral progression in Meniere's disease. *Front Neurol* 2021;12:674170 [CrossRef Medline](#)