

Are your **MRI contrast agents** cost-effective?

Learn more about generic **Gadolinium-Based Contrast Agents**.



FRESENIUS
KABI

caring for life

AJNR

Cerebellar venous angioma: "benign" entity?

W E Rothfus, A L Albright, K F Casey, R E Latchaw and H M Roppolo

AJNR Am J Neuroradiol 1984, 5 (1) 61-66
<http://www.ajnr.org/content/5/1/61>

This information is current as
of April 16, 2024.

Cerebellar Venous Angioma: “Benign” Entity?

William E. Rothfus¹
A. Leland Albright²
Kenneth F. Casey²
Richard E. Latchaw^{1,2}
Helen M. N. Roppolo¹

Four patients with bleeding venous angiomas in the cerebellar hemispheres are reported. All of the hemorrhages were subacute; three were recurrent. A literature review substantiated venous angioma as a recognized source of spontaneous cerebellar hemorrhage. Cerebellar venous angiomas may be more prone to bleed than venous angiomas in other locations. Their natural history seems to be similar to that of arteriovenous malformations. Though a minority bleed, the hemorrhagic event can be acute or subacute, recurrent, or catastrophic. Thus the clinical course is not always innocuous.

Venous angiomas are vascular malformations in which veins are the predominant vascular constituent. They were described as distinct clinical entities by Cushing and Bailey [1] in 1928 and since then have been reported sporadically. Because venous angiomas are infrequently symptomatic, their clinical significance remains unclear. When symptomatic, they are associated mainly with seizures or bleeding, although bleeding is considered to occur rarely [2]. During the past 2 years we have examined four patients with cerebellar venous angiomas who had intracerebellar bleeding. We describe the clinical and radiographic features of these cases, and review the pertinent literature to help clarify the natural history of these lesions.

Case Reports

Case 1

A 22-year-old woman had right-sided frontooccipital headaches that began abruptly and persisted for 4 days. When examined, she had mild papilledema; mild appendicular ataxia, especially of the right leg; dysdiadochokinesia of the right arm; and decreased tone in the right extremities. A computed tomographic (CT) scan without contrast enhancement revealed a moderate-sized right cerebellar hematoma. After contrast administration, a curvilinear enhancing structure was identified along the posterior border of the lesion (figs. 1A and 1B). A cerebral angiogram demonstrated right cerebellar mass effect in the arterial phase and a branching collection of enlarged and tortuous medullary veins in the venous phase (fig. 1C), consistent with a venous angioma. Eight days after the headaches began, she became confused and had a right hemiparesis, right seventh nerve paresis, and right gaze paresis. A repeat CT scan showed enlargement of the hematoma from new hemorrhage and hydrocephalus (fig. 1D). An operation was performed immediately. A large cerebellar hematoma was evacuated, the venous angioma was removed, and a ventriculostomy was inserted. Postoperatively, she had residual right-sided dysmetria and dysdiadochokinesia. A postoperative CT scan revealed no residual angioma. The pathology specimen was a vascular malformation composed predominantly of veins. The occurrence of previous and recent hemorrhage around and within the lesion was confirmed by the presence of hemosiderin and hematoidin.

Received May 31, 1983; accepted after revision September 30, 1983.

Presented at the annual meeting of the American Society of Neuroradiology, San Francisco, June 1983.

¹Department of Radiology, Division of Neuroradiology, University of Pittsburgh, School of Medicine, DeSoto at O'Hara St., Pittsburgh, PA 15213. Address reprint requests to W. E. Rothfus.

²Department of Neurosurgery, University of Pittsburgh, School of Medicine, Pittsburgh, PA 15213.

AJNR 5:61-66, January/February 1984
0195-6108/84/0501-0061 \$00.00
© American Roentgen Ray Society

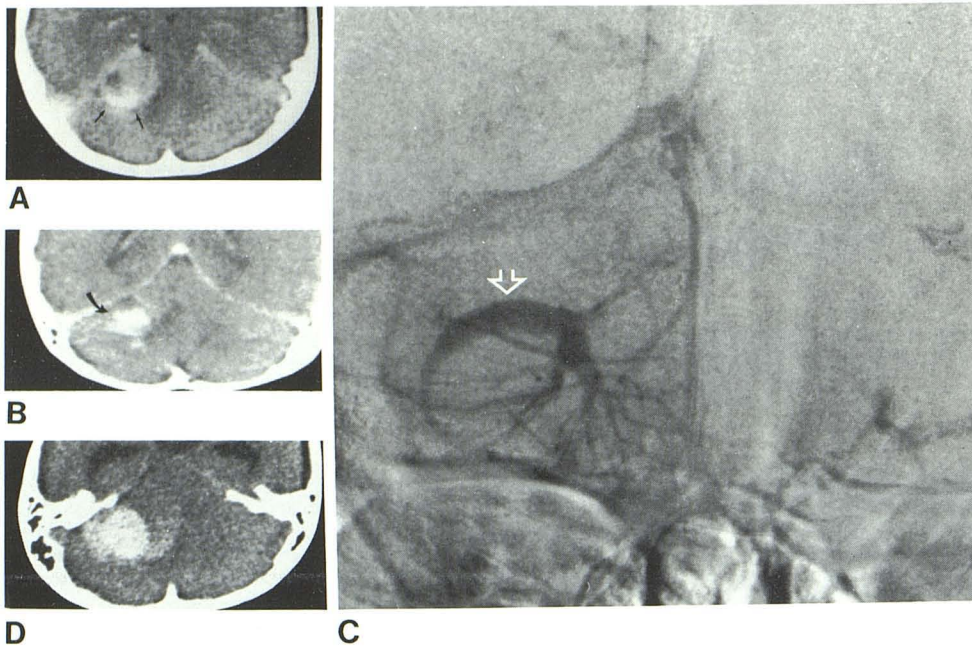


Fig. 1.—Case 1. **A**, Comma-shaped enhancing structure (arrows) in posterior part of right cerebellar hemisphere hematoma. **B**, Coronal scan shows structure runs horizontally across superior aspect of hematoma (arrow). **C**, Venous phase of vertebral angiogram. Enlarged medullary veins drain into large horizontal transcerebellar vein (arrow), which corresponds to density in **A** and **B**. **D**, Noncontrast CT scan 8 days after **A** and **B** shows dense acute hematoma near site of large transcerebellar vein. Note also development of hydrocephalus.

Case 2

A 12-year-old boy was admitted after 2 weeks of progressive headaches, vertigo, ataxia, and vomiting. He also had visual blurring and right arm weakness. He was lethargic, with papilledema, right lateral-gaze nystagmus, right-sided dysmetria and dysidiadochokinesia, and a positive Romberg test. CT revealed an inhomogeneous, hyperdense right cerebellar hemispheric mass. The posterior aspect of the mass enhanced as a curvilinear, branching structure (fig. 2). Moderate hydrocephalus was present. A ventriculoperitoneal shunt was inserted and his ventricles diminished, but his clinical condition did not improve substantially. A craniectomy was performed, and a large hematoma and venous angioma were removed. Postoperatively, his recovery was uneventful and his only neurologic deficit was transient right arm dysmetria. Histologically, the specimen was a venous angioma with evidence of recent and previous hemorrhage. Postoperative CT showed no residual angioma.

Case 3

A nonhypertensive 57-year-old man was evaluated after 1 month of occipital headache, diplopia, and ataxia. On examination, he had right lateral-gaze nystagmus. A CT scan without contrast enhancement revealed an inhomogeneous posterior fossa mass. After contrast administration, fairly well defined regions of enhancement were seen along the posterior, medial, and anterior sides of the mass (figs. 3A and 3B). A vertebral angiogram demonstrated the typical circumferential pattern of enlarged veins of a venous angioma (fig. 3C). An operation was performed, confirming the presence of a venous angioma with an associated hematoma that consisted of new and old blood. Resection was incomplete but bleeding did not recur. The patient recovered without deficit.

Case 4

A nonhypertensive 57-year-old woman was admitted for the second time in 18 months. Both admissions were to evaluate occipital

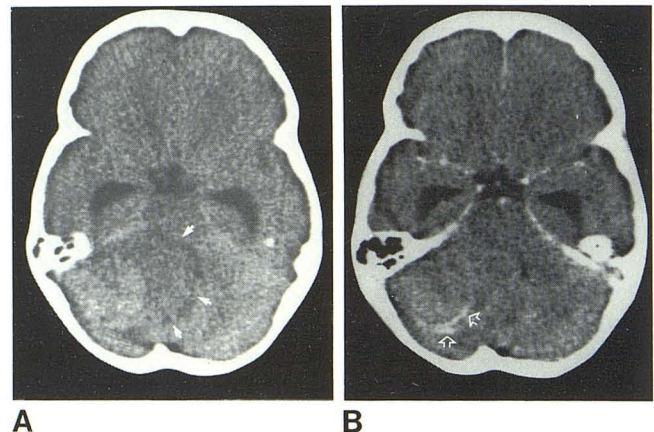


Fig. 2.—Case 2. **A**, Noncontrast scan. Large right cerebellar hematoma (arrows) distorts fourth ventricle. Variance of density within hematoma suggests previous and recent hemorrhage. Hydrocephalus is present. **B**, After contrast administration, thin curvilinear densities in branchlike pattern outline posterior aspect of hematoma (arrows). These relate to area of more acute hemorrhage illustrated in **A**.

headache, tinnitus, vertigo, gait ataxia, and incoordination lasting several days. Her first examination disclosed rotatory nystagmus, lateral-gaze nystagmus, left intention tremor, and a positive Romberg sign. A CT scan during the first admission showed a moderate-sized cerebellar hematoma, with branchlike enhancement at its posterior aspect (figs. 4A and 4B). An angiogram demonstrated a medusoid conglomeration of dilated medullary veins draining into a large transcerebellar vein, indicative of a venous angioma. No operation was performed. A CT scan during the second admission revealed a similarly enhancing structure at the periphery of a resolving hematoma (figs. 4C and 4D). The angiogram was unchanged (figs. 4E and 4F). Again no operation was performed and her symptoms improved. She was still stable after 11 months with ataxia that varied in severity.

Fig. 3.—Case 3. **A**, Noncontrast CT scan. Ringlike area of lucency (*arrowheads*) around resolving left cerebellar hematoma. **B**, Postcontrast scan. Several well defined areas of enhancement around periphery of hematoma. **C**, Vertebral injection, venous phase, after unremarkable arterial phase. Typical pattern of venous angioma. Enlarged medullary veins (*small arrows*) drain into large transcerebellar vein (*large arrow*), which ultimately drains into petrosal vein.

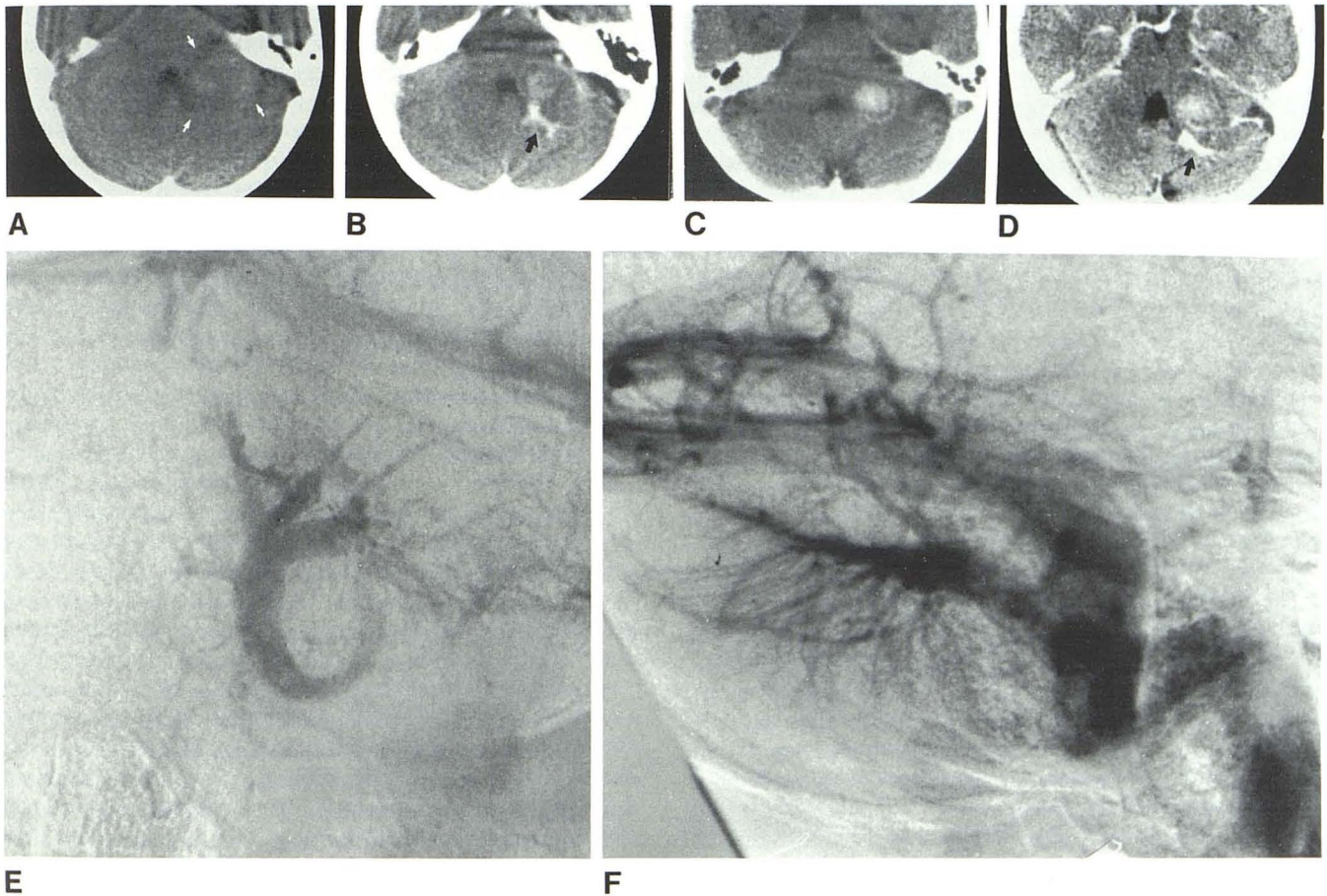
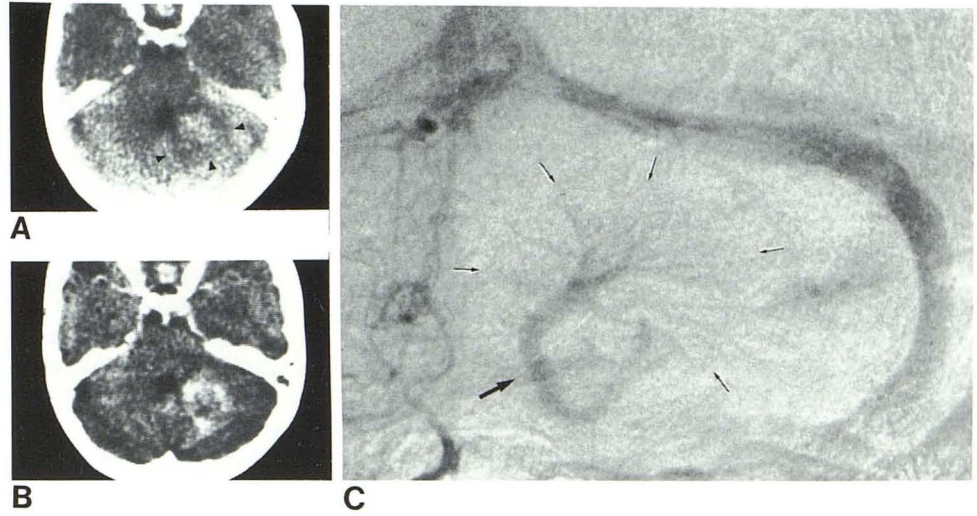


Fig. 4.—Case 4. **A**, Resolving hematoma in left cerebellar hemisphere extends to cerebellopontine angle (*arrows*). **B**, Posterior part of hematoma enhances in branching pattern (*arrow*). **C**, 18 months later. Another resolving hematoma is in exactly same location as previous one. **D**, Enhanced scan.

Prominent branching vascular structures posterior to hematoma (*arrow*). Frontal (**E**) and lateral (**F**) venous phase vertebral angiograms demonstrate venous angioma. Posterosuperior aspect of angioma correlates with branching structures seen on **B** and **D**.

Discussion

Venous angiomas were once considered uncommon lesions. Until recently there were few autopsy reports of these angiomas and even fewer surgical reports [1, 3–6]. However, large autopsy series suggest that venous angiomas are relatively common incidental findings [7, 8]. In fact, McCormick and Sarwar [9, 10] have shown them to be the most common type of angioma found at autopsy, occurring in about 3% of cases. Despite this relatively frequent occurrence, the number of reported cases of symptomatic venous angiomas is low. Most seem to be clinically silent. When symptomatic they most commonly cause seizures, and are said to bleed rarely [2].

Venous angiomas have been diagnosed more frequently since the advent of magnification angiography and CT. The angiographic hallmarks of venous angiomas are enlarged medullary veins. These veins usually converge to form a large central channel that courses transcerebrally or transcerebellarly to end in a cortical vein, dural sinus, or less commonly into the deep venous system [11–18]. The arterial phase is usually completely normal, but occasionally a poorly circumscribed blush, early draining vein, or slightly enlarged arterial branch can be seen [15, 17, 18]. Of interest, a higher frequency of bleeding has been reported for angiomas with typical angiographic features (i.e., no early appearing vessels) as opposed to those with early appearing vessels [14]. The angiograms of our three cases were typical, with normal arterial phases and a caput medusae of veins merging into large central veins, which drain superficially into the petrosal vein.

CT complements angiography in the detection of venous angiomas. Several recent reports describe the appearance of venous angiomas on CT scans [13, 14, 19–26]. Enhancement is the key feature in these reports and takes the form of a distinct round or linear density. There is no mass effect, unless hemorrhage has occurred. The confluence of linear structures (veins) can be seen occasionally, and the large transparenchymal draining vein(s) may be followed on serial scan slices [20, 26]. The CT characteristics alone are not specific enough to diagnose venous angiomas, and angiography is usually required to distinguish them from arteriovenous malformations (AVMs) or small neoplasms.

CT was undeniably helpful in the evaluation of our patients. It accurately identified the location and character of the hemispheric hematomas and identified hematomas as the cause of a worsening clinical condition. Enhanced scans were most informative. In all the cases there was well defined enhancement that was distinct from the hematoma. Although this was a nonspecific finding that could have been mimicked by an AVM or tumor of the cerebellum [27, 28], findings were more specific in two cases. Cases 2 and 4 showed branching enhancing densities that were highly suggestive of vascular structures. In case 4 a large vascular structure could be identified coursing toward the petrosal sinus (not shown), suggesting a transparenchymal draining vein.

Spontaneous cerebellar hemorrhages are usually hypertensive in origin. Angiomatous malformations are the second most frequent cause, with aneurysms, blood dyscrasias, and

infection being responsible for a minority of cerebellar hemorrhages [23, 29–37]. Hypertensive hemorrhages occur most often in the region of the dentate nucleus of one hemisphere, whereas hemorrhages from other causes occur anywhere in the hemisphere or vermis [30, 33, 34]. Angiomatous hemorrhages of any etiology (arteriovenous, venous, cavernous, etc.) are usually located deep in the cerebellar hemisphere, but may extend superficially to the cortex [33]. Hypertensive hemorrhages occur in older age groups, while angiomatous malformations are responsible for most bleeds in younger age groups [38].

Any type of angioma can bleed. In the cerebellum, the angioma that bleeds most often is the AVM. Venous angiomas, however, are second most common [8]. The actual frequency of hemorrhage in cerebellar venous angiomas is uncertain. McCormick et al. [8], in their large autopsy series of posterior fossa angiomas, found evidence of hemorrhage in three (15%) of 20 cases of cerebellar venous angioma. Considering the overall frequency of this type of angioma, hemorrhage may not be as rare as was once believed.

We made an extensive literature search for cases of bleeding cerebellar venous angiomas in order to compare them with our four cases. In all, 20 cases were found that had been documented by histology (autopsy or surgical), by angiography (typical radiologic features discussed above), or both [6–8, 14, 18, 20, 21, 23, 28, 33, 39–41]. These 20 represent a large proportion (i.e., 36%) of the total number of cerebellar venous angiomas described in the literature [2, 11, 18, 22, 23, 25, 26, 42, 43]. In addition, these 20 cases constitute almost half of the total number of reported hemorrhagic venous angiomas, both infra- and supratentorial [1, 3, 5, 11, 13, 16–18, 23, 25, 26, 44–46] (in contrast to a 3:1 predominance of cerebral venous angiomas to cerebellar venous angiomas [7, 8]). These facts imply a possible propensity of cerebellar venous angiomas to bleed and contrast with previous reports that these lesions have a benign clinical course [2, 12, 17, 42].

The 20 patients were 7–65 years old, however, most were in the younger age groups. The most common location of both angioma and hemorrhage was the cerebellar hemisphere. Symptoms sometimes occurred with catastrophic severity, sometimes slowly worsened over several days, and sometimes occurred as multiple episodes over months or years. The sporadic symptoms reported in several cases suggest that some cerebellar venous angiomas bleed subacutely and intermittently. Pathologic proof of subacute bleeding is provided in at least one of the published cases [18]. It is important to note that operative removal of the hematoma was successful in all three of the surgical cases [21, 28, 40].

Our four cases accent several points about hemorrhagic cerebellar venous angiomas. Venous angioma, although uncommon, must be considered in the differential diagnosis of spontaneous cerebellar hemorrhage in any age group. Only two out of the four patients were young. The other two were symptomatic in the sixth decade of life, an age group in which hypertension rather than angioma would normally be considered responsible for spontaneous cerebellar hemorrhage. The initial symptoms in all of our cases included a headache, usually occipitofrontal, with associated cerebellar and brain-

stem signs. Most reported cases have had similar signs and symptoms. All of our cases involved the cerebellar hemisphere, usually near the cerebellopontine angle. Most reported cases were also in the cerebellar hemisphere.

All of our patients had a subacute clinical picture. Two patients (cases 1 and 2) presented with fairly rapidly deteriorating courses. A third (case 3) had a slowly deteriorating course, and the fourth had symptomatic episodes spaced 18 months apart, but without clinical deterioration. All of these patients had subacute bleeds documented by CT scans (resolving hematoma) or pathology specimens (hemosiderin). Acute rebleeding was a significant feature of cases 1, 2, and 4 and was also confirmed by CT or pathology. Rebleeding occurred several days to 18 months postictus. The findings in our cases and those in the literature suggest a natural history much like that of AVMs. That is, some cerebellar venous angiomas (eight [15%] of 55 reported cases) bleed extensively at first, causing rapid, catastrophic clinical deterioration. Others (11 [20%] of 55 reported cases) bleed less profusely and remain static for a few days or years, after which they may rebleed. Apparently, most angiomas do not bleed at all.

The relation of size of venous angioma to bleeding is unclear. All of our patients had moderately large angiomas. Although several authors noted a positive correlation between the size of vascular malformations of any type and frequency of hemorrhage [2, 8], small, occult malformations are known to bleed [33, 39].

Given the possible propensity for cerebellar venous angiomas to bleed and the chance that rebleeding will occur, operative intervention becomes an important consideration. It is, as yet, impossible to predict what course an asymptomatic cerebellar venous angioma will take. Size and location may be indicators of possible future hemorrhage, but larger series are necessary to define prognostic factors. Once an angioma has bled, rebleeding may occur at any time. The extent and rate of resultant clinical decline is thus unpredictable. Indeed, a rebleed may be fatal, as several cases in the literature indicate [6, 14, 18, 40]. It would seem then that expeditious removal of a recognized hemorrhagic cerebellar hemisphere venous angioma may be indicated.

Surgery has been successful in cases of spontaneous (hypertensive and angiomatous) cerebellar hematoma [29, 31, 36, 38, 47, 48]. Both acute and chronic hematomas have been treated by suboccipital craniectomy and evacuation. Most cases with favorable outcome have been those with a good preoperative level of consciousness and those with slowly evolving clinical signs. Because venous angiomas can present with subacute bleeding, their clinical course seems to fit with those cases that predictably would do well with operation. The favorable outcome in our three operated cases substantiates the effectiveness of surgical management of subacutely bleeding cerebellar hemisphere venous angioma, a subgroup of spontaneous cerebellar hemorrhage that may, in fact, be cured by resection.

REFERENCES

- Cushing H, Bailey P. *Tumors arising from the blood vessels of the brain: angiomatous malformations and hemangioblastomas*. Springfield, IL: Thomas, 1928;3-34
- Courville CB. Morphology of small vascular malformations of the brain. With particular reference to the mechanism of their drainage. *J Neuropathol Exp Neurol* 1963;22:274-284
- Brock S, Dyke CG. Venous and arteriovenous angiomas of the brain. A clinical and roentgenographic study of eight cases. *Bull Neurol Inst NY* 1932;2:247-293
- Dandy WE. Venous abnormalities and angiomas of the brain. *Arch Surg* 1928;17:715-793
- Noran HH. Intracranial vascular tumors and malformations. *Arch Pathol Lab Med* 1945;39:393-416
- Wolf A, Brock S. The pathology of cerebral angiomas. A study of nine cases. *Bull Neurol Inst NY* 1935;4:144-176
- Jellinger K. The morphology of centrally-situated angiomas. In: Pia HW, Gleave JRW, Grate E, Zierski J, eds. *Cerebral angiomas. Advances in diagnosis and therapy*. New York: Springer-Verlag, 1975:9-18
- McCormick WF, Hardman JM, Boutler TR. Vascular malformations ("angiomas") of the brain, with special reference to those occurring in the posterior fossa. *J Neurosurg* 1968;28:241-251
- McCormick WF. *Selected topics in cerebrovascular disease*. Presented at the Armed Forces Institute of Pathology neuropathology annual short course, Washington, DC, January 1983
- Sarwar M, McCormick WF. Intracerebral venous angioma. Case report and review. *Arch Neurol* 1978;35:323-325
- Cabanes J, Blasco R, Garcia M, Tamarit L. Cerebral venous angiomas. *Surg Neurol* 1979;11:385-398
- Constans JP, Dilenge D, Vedrenne C. Angiomes veineux cerebraux. *Neurochirurgie* 1968;14:641-650
- Fierstein SB, Pribram HW, Hieshima G. Angiography and computed tomography in the evaluation of cerebral venous malformations. *Neuroradiology* 1979;17:137-148
- Moritake K, Handa H, Mori K, Ishikawa M, Morimoto M, Takebe Y. Venous angiomas of the brain. *Surg Neurol* 1980;14:95-105
- Preissig RS, Preissig SH, Goree JA. Angiographic demonstration of a cerebral venous angioma. *J Neurosurg* 1976;44:628-631
- Scotti LN, Goldman RL, Rao GR, Heniz ER. Cerebral venous angioma. *Neuroradiology* 1975;9:125-128
- Wendling LR, Moore JS Jr, Kieffer SA, Goldberg HI, Latchaw RE. Intracerebral venous angioma. *Radiology* 1976;119:141-147
- Wolf PA, Rosman NP, New PFJ. Multiple small cryptic venous angiomas of brain mimicking cerebral metastases. A clinical pathological, and angiographic study. *Neurology (NY)* 1967;17:491-511
- Becker DH, Townsend JJ, Kramer RA, Newton TH. Occult cerebrovascular malformations. A series of 18 histologically verified cases with negative angiography. *Brain* 1979;102:249-287
- Hacker DA, Latchaw RE, Chou SN, Gold LHA. Bilateral cerebellar venous angioma. *J Comput Assist Tomogr* 1981;5:424-426
- Maehara T, Tasaka A. Cerebral venous angioma: computerized tomography and angiographic diagnosis. *Neuroradiology* 1978;16:296-298
- Michels LG, Bentson JR, Winter J. Computed tomography of cerebral venous angiomas. *J Comput Assist Tomogr* 1977;1:149-154
- Numaguchi Y, Kitamura K, Fukui M, et al. Intracranial venous angiomas. *Surg Neurol* 1982;18:193-202
- Paradatscher K, Fiore DL, Galligioni F, Iraci G. Diagnosis of cerebral venous angioma by rapidly enhanced CT scan. *Surg Neurol* 1980;14:111-113
- Pelz DM, Vinuela F, Fox AJ. Unusual radiologic and clinical presentations of posterior fossa venous angiomas. *AJNR* 1983;4:81-84.
- Senegor M, Dohrmann GJ, Wollmann R. Venous angiomas of

- the posterior fossa should be considered as anomalous venous drainage. *Surg Neurol* **1983**;19:26-32
27. Vincent FM, Bartone JR, Jones MZ. Cerebellar astrocytoma presenting as a cerebellar hemorrhage in a child. *Neurology (NY)* **1980**;30:91-93
 28. Bitoh S, Hasegawa H, Fujiwara M, Sakurai M. Angiographically occult vascular malformations causing intracranial hemorrhage. *Surg Neurol* **1982**;17:35-42
 29. Brennan RW, Bergland RM. Acute cerebellar hemorrhage. Analysis of clinical findings and outcome in 12 cases. *Neurology (NY)* **1977**;27:527-532
 30. Dinsdale HB. Spontaneous hemorrhage in the posterior fossa. A study of primary cerebellar and pontine hemorrhages with observations on their pathogenesis. *Arch Neurol* **1964**;10:200-217
 31. Fisher CM, Picard EH, Polak A, Dalal P, Ojemann RG. Acute hypertensive cerebellar hemorrhage: diagnosis and surgical treatment. *J Nerv Ment Dis* **1965**;140:38-57
 32. Hollin SA, Decker RE, Gross SW. Spontaneous cerebellar hematomas. *Mt Sinai J Med (NY)* **1973**;41:396-406
 33. Hyland HH, Levy D. Spontaneous cerebellar hemorrhage. *Can Med Assoc J* **1954**;71:315-323
 34. Kunze S, Schiefer W. Cerebellar haematomas. In: Pia HW, Langmaid C, Zierski J, eds. *Spontaneous intracerebral haematomas. Advances in diagnosis and therapy*. New York: Springer-Verlag, **1980**:152-154
 35. McCormick WF, Nofzinger JD. "Cryptic" vascular malformations of the central nervous system. *J Neurosurg* **1966**;24:865-875
 36. McKissock W, Richardson A, Walsh L. Spontaneous cerebellar hemorrhage. *Brain* **1960**;83:1-9
 37. Ray-Bellet J. Cerebellar hemorrhage. *Neurology (NY)* **1960**;10:217-222
 38. Erenberg G, Rubin R, Shalman K. Cerebellar haematomas caused by angiomas in children. *J Neurol Neurosurg Psychiatry* **1972**;35:304-310
 39. Crawford JV, Russell DS. Cryptic arteriovenous and venous hamartomas of the brain. *J Neurol Neurosurg Psychiatry* **1956**;19:1-11
 40. Odom G, Tindall GT, Dukes HT. Cerebellar hematomas caused by angiomatous malformations. Report of four cases. *J Neurosurg* **1961**;18:777-782
 41. Iraci G, Galligioni F, Gerosa M, et al. Intracerebral venous angiomas as a cause of exophthalmos. *Ann Ophthalmol* **1979**;11:603-612
 42. Saito Y, Kobayashi N. Cerebral venous angiomas. *Radiology* **1981**;139:87-94
 43. Crevits L, DeReuck J, Vande Veld E, Vander Eecken H. Venous malformations drained by the precentral cerebellar vein. An angiographic and post-mortem study. *Clin Neurol Neurosurg* **1978**;80:149-155
 44. Kamrin RB, Buschsbaum HW. Large vascular malformation of the brain not visualized by serial angiography. *Arch Neurol* **1965**;13:413-420
 45. Margolis G, Odom GL, Woodhall B, Bloor BM. The role of small angiomatous malformations in the production of intracerebral hematomas. *J Neurosurg* **1951**;8:564-575
 46. Pak H, Patel SC, Malik GM, Ausman JI. Successful evacuation of a pontine hematoma secondary to rupture of a venous angioma. *Surg Neurol* **1980**;15:164-167
 47. Lapas C. Angiomas of cerebellum and brainstem. In: Pia HW, Gleave JRW, Grote E, Zierski J, eds. *Cerebral angiomas. Advances in diagnosis and therapy*. New York: Springer-Verlag, **1975**:136-141
 48. Ott KH, Kase CS, Ojemann RG, Mohr JP. Cerebellar hemorrhage diagnosis and treatment. A review of 56 cases. *Arch Neurol* **1974**;31:160-167