

Are your **MRI contrast agents** cost-effective?

Learn more about generic **Gadolinium-Based Contrast Agents**.



FRESENIUS
KABI

caring for life

AJNR

CT scanning phantom for normalization of infant brain attenuation.

J R Thompson, P J Triolo, R J Moore, D B Hinshaw, Jr and A N Hasso

AJNR Am J Neuroradiol 1984, 5 (2) 167-170

<http://www.ajnr.org/content/5/2/167>

This information is current as of April 19, 2024.

CT Scanning Phantom for Normalization of Infant Brain Attenuation

Joseph R. Thompson¹
 Peter J. Triolo¹
 Robert J. Moore²
 David B. Hinshaw, Jr.¹
 Anton N. Hasso¹

The x-ray attenuation values of brain studied with computed tomography (CT) are strikingly affected by the ages of the subjects. Premature neonates, for example, may have brain attenuation values 20–30 H below adult values. These lower attenuation values for developing compared with adult brain can be ascribed partly to machine-related effects (beam-hardening, adult algorithms, scanning geometry, etc.). A scanning phantom made from aluminum was developed that can be used to develop a nomogram for any particular scanner from which normalized brain attenuation may be derived for any small head size. Using this nomogram, predicted neonatal attenuations are still 10–15 H higher than those actually observed in scanning neonates. The model predicts that, at the most, 3–4 H of this discrepancy can be accounted for by less beam-hardening from the lower bone attenuation of the thinner developing skull. Presumably, the rest is from a lower brain density in neonates (higher water content). By normalizing to cerebrospinal fluid (water) with special care to avoid partial-volume artifacts, one can predict attenuation values for developing brain more accurately.

Computed tomography (CT) of the head in the neonate and during brain development presents a perplexing diagnostic problem. The “normal” brain attenuation in this period appears to be lower than that of the adult, yet many of the pathologic processes of this period also manifest attenuation decreases. In studying perinatal asphyxia, Flodmark et al. [1] found poor autopsy correlation with CT when attempting to diagnose areas of low brain density from ischemic brain damage in premature neonates. Areas of hemorrhage showed fairly good correlation. In our experience, even hemorrhage may be diagnosed falsely when the brain about islands of normal tissue is infarcted or severely edematous. These inaccuracies seem to occur because of the poor density resolution of CT scanners, particularly for small heads [2]. Brant-Zawadzki and Enzmann [3] recognized this problem of poor density resolution and for this reason used the differences between mean gray matter and mean white matter attenuations to demonstrate the changes of water content in the brains of neonates with increasing gestational ages rather than relating the mean attenuations themselves to water content.

Because neurologically normal neonates are infrequently examined with CT we have not been able to develop a normal baseline of brain attenuation. In fact it may not be possible to do so without first considering head size. In earlier work we have demonstrated that decreases in head diameter and skull thickness cause an artifactual lowering of the measured attenuation of brain parenchyma using either the EMI 1010B or GE 8800 CT/T scanner [4]. We have now developed a scanning phantom that enables us to simulate scanning in the clinical setting. From phantom scan data one can predict the quantitative decrease in brain attenuation that is to be expected from decreasing calvarial dimensions below those of the standard adult head.

Received July 8, 1983; accepted after revision October 11, 1983.

Presented at the annual meeting of the Radiological Society of North America, Chicago, November 1981.

¹ Department of Radiation Sciences, Section of Neuroradiology, School of Medicine, Loma Linda University, Loma Linda, CA 92350. Address reprint requests to J. R. Thompson.

² Department of Radiation Sciences, Section of Radiation Physics, School of Medicine, Loma Linda University, Loma Linda, CA 92350.

AJNR 5:167–170, March/April 1984
 0195–6108/84:0502–0167 \$00.00
 © American Roentgen Ray Society

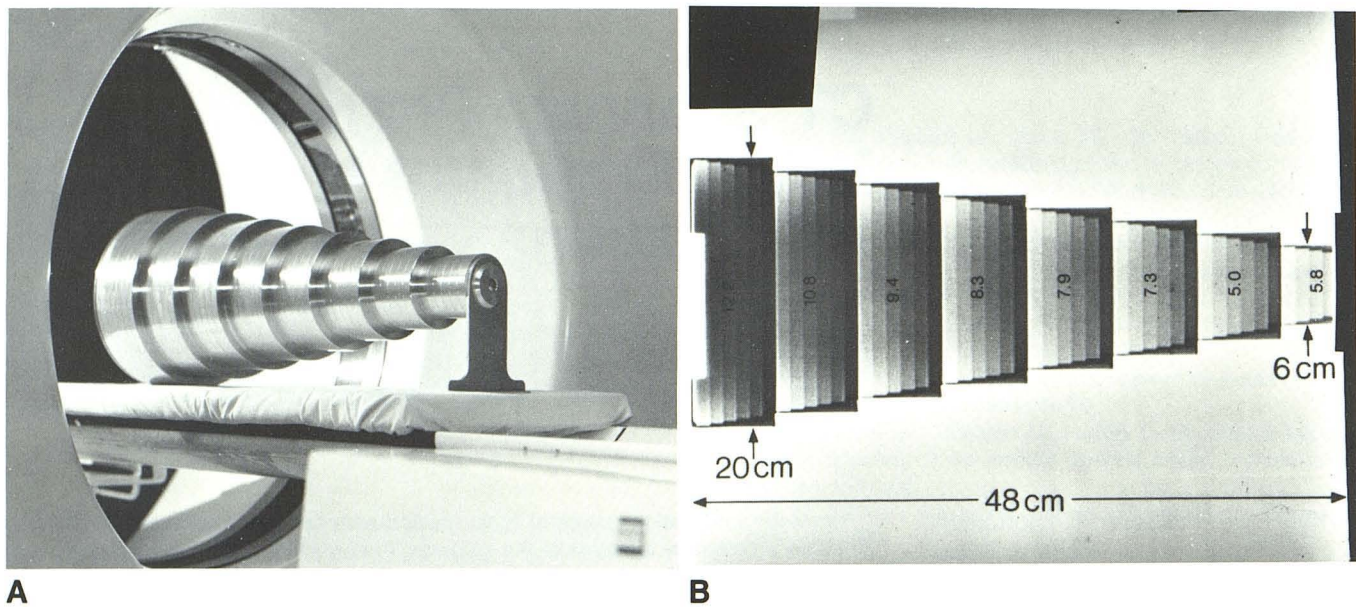


Fig. 1.—A, Aluminum CT scanning phantom designed for determining effects of head diameter and skull thickness on brain attenuation. B, Scanned projection radiograph (ScoutView) of phantom. Variations of measured attenuation (H) for water shown from scans of 4.5-mm-thick rings at each ring diameter.

Materials and Methods

The phantom was machined from three separate pieces of aluminum and welded together to form a series of eight rings decreasing in outer diameter from 20 cm to 6 cm at 2 cm increments (fig. 1). Each ring has five different 1-cm-wide thickness steps increasing from 1.5 mm to 7.5 mm at 1.5 mm thickness increments. While a ring thickness of less than 1.5 mm would have been desirable to simulate less mature calvaria, the strength of such a ring thickness would not be adequate to support the phantom shell when filled with water. A brace supports the smallest ring maintaining the axis of the phantom parallel to a horizontal support. Machined tolerances of all phantom measurements are within 0.0005 inch (0.0127 mm).

Phantom Scanning

The phantom was filled with distilled water and scanned on the GE CT/T 8800 scanner. It was supported within the gantry by a dense polyurethane foam pad placed on the scanning table. Slice location was determined with the localization cursor on a ScoutView digital radiograph. Each image was 1.5 mm thick to avoid partial-volume effects from adjacent phantom rings and was made in the 576/9.6 sec scanning mode at 120 kVp using the maximum milliamperage allowed to maintain the overrange counts below 400. Attenuation measurements of the phantom images were made by measuring the largest region of interest (ROI) square that would fit within the aluminum ring of each displayed scan slice. Acrylic rings of various diameters were also scanned in the above manner to determine water attenuation within rings effectively 0 mm in thickness for aluminum, as the minimum ring thickness of 1.5 mm of aluminum in the phantom is considerably greater than would be representative of most premature and many full-term infant skulls [5].

In vivo Scanning

We sought to average the attenuation for brain to minimize the effects of nonuniformity caused by variations in head shape and skull

thickness. Mean attenuations were measured in 20 radiologically normal adult brains to obtain an average baseline attenuation value. Scanning parameters included 1-cm-thick sectioning, the 576/9.6 sec scanning mode, and 120 kVp, which is a fixed setting on the GE 8800 model. ROIs for attenuation measurements were consistently selected at a level that included the anterior horns and trigones of the lateral ventricles because sections at this level tend to provide more accurate attenuation values than higher or lower cranial sections. The ROI was inscribed about a hemisphere in such a way as to exclude the cerebrospinal fluid (CSF) spaces and also the beam-hardening artifact adjacent to the inner skull table.

Normalization

The thickness measurements of the phantom were transformed into simulated skull measurements by factoring the phantom ring thickness by 1.7, which was derived as follows. Skull bone density was placed at 1.7 g/cm³ to represent an average between diploic and compact bone [6, 7]. This value was then used to determine the linear attenuation coefficient at 70 keV. From comparing attenuation coefficients it was determined that 1 cm of aluminum was approximately equivalent to 1.7 cm of skull bone. No data are available as to the relative density of the calvaria of developing fetal skulls, which have no diploic space.

To simulate brain parenchyma within the phantom we first added a small amount of iodinated contrast material (11 ml of Isopaque 440 making the solution about 0.002% contrast material) to the water within the phantom. However, this caused a false peak in the attenuation curves when compared with distilled water. This was especially noted in the thinner and smaller-diameter rings. We attributed this to the photoelectric effect of iodine, which would be proportionately greater as the beam-hardening effect diminished in the thinner skulls.

The photoelectric and Compton effects of brain parenchyma and water are predictably similar and the attenuation curves should be parallel. Therefore, instead of adding a material to the distilled water within the phantom to evaluate the measured attenuation, we added a normalization constant to the water attenuation curves to simulate

brain parenchyma. Normal attenuation of adult brain measured on our scanner according to the method described was 42 H (SD 1.6 H). Water attenuation measured on the adult head standard phantom ring was 9 H, producing a difference of 33 H. Therefore, we added 33 H to the phantom water curves to obtain a set of curves normalized to adult brain attenuation.

Results

The effect on measured attenuation of water by increasing the simulated skull diameter at a given simulated skull thickness is shown in figure 2. The 4.5-mm-thick aluminum ring represents a medium skull thickness of 7.7 mm. Translating this information to neonates, as one increases the head size from that of a small premature neonate (6 cm) to that of an adult, the attenuation increases by 6 or 7 H.

Looking at various simulated skull thicknesses (fig. 3) with a constant simulated skull diameter, a similar relation is observed. As the skull thickness increases, the measured attenuation of water increases. Attenuation varies more dramatically with small-sized heads than with normal-sized heads as one varies the skull thickness. There is a large range of measured attenuation of water demonstrated with the phantom images. Water in a 6 cm acrylic ring (simulating no real skull as seen in an immature neonate) shows an attenuation of -11 H. This lower value is similar to CSF measurements we have observed clinically in very premature infants who have virtually little but a membranous skull and head diameters in the range of 5-7 cm. On the other hand, water in a 20 cm aluminum ring of 7.5 mm thickness (simulating a normal large head of 13 mm skull thickness) shows an attenuation of 19 H. Thus we see a 30 H difference between the attenuation of water within the smallest thin skull to the largest thick skull encountered in simulated clinical scanning. Since the attenuation coefficients of water and brain at an effective kilovoltage in the diagnostic x-ray range may be assumed to parallel each other, the same spread of attenuation values should be demonstrated for brain as for water with varying head sizes. In fact, we have observed this variation in scanning small infants.

Figure 4 shows the nomogram that was generated from the water phantom data. Skull thickness curves have been calculated from the aluminum/skull ratio, 1.7. Use of the nomogram requires three measurements from the patient's CT scan: head diameter, skull thickness, and the ROI determination of average brain attenuation.

Discussion

In the clinical setting, the decrease in measured brain attenuation that might be caused by a decrease in the skull thickness and/or diameter from that of the adult head size is in the range of 15-20 H. Most of this decrease in attenuation results from diminished beam-hardening when scanning the smaller heads, and no hardware or software improvements have been made by most state-of-the-art CT scanner manufacturers to correct for it. Other factors such as the design of the reconstruction algorithm (tuned to adult heads) also play a role. The effects of beam-hardening have been noted by

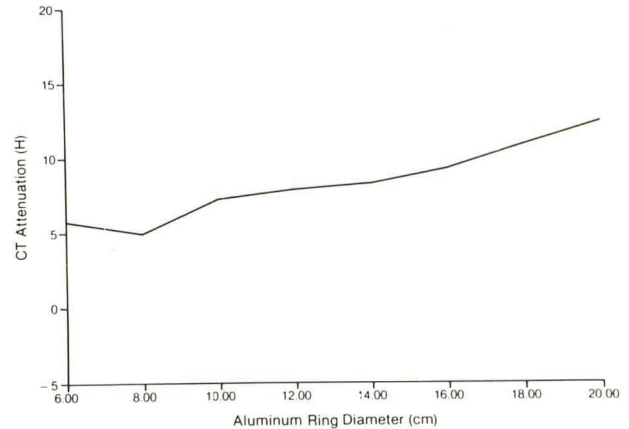


Fig. 2.—Water-filled aluminum scanning phantom. Attenuation of water with varying ring diameters for 4.5-mm-thick ring illustrating effect of skull diameter on measured attenuation.

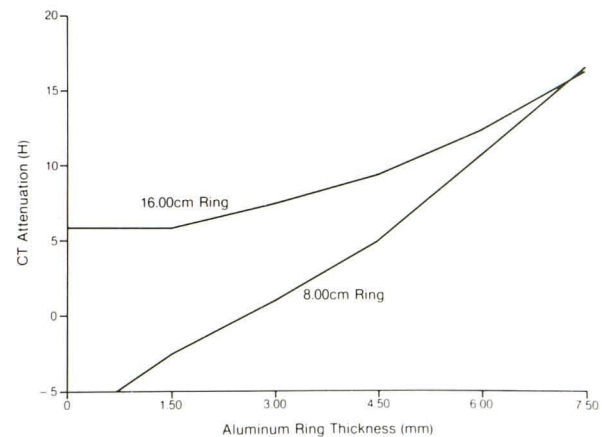


Fig. 3.—Water-filled aluminum scanning phantom. Attenuation of water with varying ring thicknesses for two ring sizes illustrating effect of skull thickness on measured attenuation.

several authors [6-8]. Di Chiro et al. [9] described how it increased the parenchymal attenuation at the skull apex because of the increasing effective skull thickness.

In figure 4 one can observe higher attenuation values for normalized brain with the 12.8-mm-thick skull at the 6 cm skull diameter than are seen with the normal adult skull diameter. This effect is most likely caused by the use of a beam-hardening algorithm correction factor based on adult head size.

From the nomogram normalized to adult brain, parenchymal attenuation for infants in the period of brain development may be predicted. We found, however, that the predicted values were still 10-15 H higher than measured values from clinical CT scanning. This was true only for developing brains because attenuation values for older children and adults correlated with the predictions of the nomogram. Figure 5 shows a range of developing infant brain attenuation for small head sizes that lies between the composite attenuation curves for water and the composite curves for older children and adults.

The attenuation values of CSF and water are nearly iden-

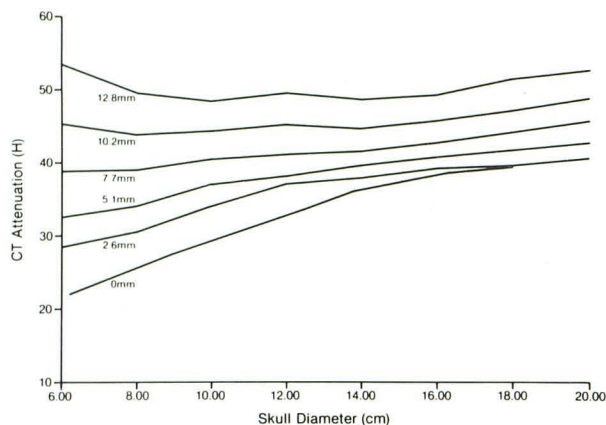


Fig. 4.—Data obtained from scanning water-filled phantom has been plotted to show combined effects of varying simulated skull diameters and thicknesses. Normalization factor of 33 H has been added to measured water attenuations. When added, normalized attenuations approximate those expected from linear attenuation coefficient of adult brain and also approximate attenuations noted when scanning *in vivo*. Values of skull thickness (mm) were determined by multiplying aluminum ring thicknesses (mm) by factor 1.7, bone to aluminum ratio. By knowing an infant's effective head diameter and average skull thickness, normalized brain attenuation may be read from nomogram.

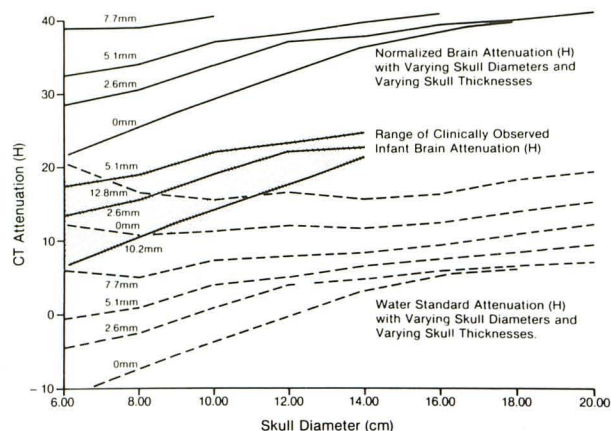


Fig. 5.—Composite attenuation curves. Clinically observed attenuation values of developing brain (*shaded area*) fall below nomogram attenuation values normalized to adult brain. Conversely, clinically observed attenuations of CSF closely approximate CSF (water) attenuations measured from the phantom. CSF does not vary in density with brain development. It follows then, that divergence of developing brain attenuation from that expected from nomogram based on adult brain standard relates to variance in its physiochemical properties.

tical; and it has been shown that even in pathologic states with high CSF protein, the CSF attenuation was elevated by only 4 H [10]. There is no change in CSF composition from neonate to adult. Therefore, the values for water scanned within the phantom should be the same as measured CSF in patients with corresponding head dimensions. In fact, we found this to be true even during the period of brain maturation. We conclude that the lower than predicted attenuations in head scans during the period of cerebral development (*shaded area*, fig. 5) may well be accounted for by the differences in the physiochemical nature of maturing brain parenchyma. Whereas CSF does not change from infancy to adulthood, developing brain is thought to have decreasing water content with age. These factors may account for the differences from nomogram predictions for developing brain and the close correlation with predicted CSF attenuation.

The lack of proven "normal" scans in the premature and neonatal age group makes the determination of a normal brain attenuation value difficult. However, normalization to CSF values can give the radiologist a higher degree of confidence when interpreting scans in premature and very young infants. It appears that CT scanner manufacturers are not sufficiently concerned about this problem to devise pediatric algorithms for improving the density resolution in small heads.

ACKNOWLEDGMENT

We thank Paul Olm for machining an aluminum phantom of such precision for the investigation of brain attenuation.

REFERENCES

1. Flodmark O, Becker LE, Harwood-Nash DC, Fitzhardinge PM, Fitz CR, Chuang SH. Correlation between computed tomography and autopsy in premature and full-term neonates that have suffered perinatal asphyxia. *Radiology* 1980;137:93-103
2. Thompson JR, Moore RJ, Hinshaw DB Jr, Hasso AN. Density resolution artifacts encountered when scanning infant heads with x-ray computed tomography. *Proc SPIE* 1982;347:184-189
3. Brant-Zawadzki MB, Enzmann DR. Using computed tomography of the brain to correlate low white-matter attenuation with early gestational age in neonates. *Radiology* 1981;199:105-108
4. Thompson JR, Triolo PJ, Moore RJ, Hasso AN, Hinshaw DB Jr. A problem in neurodiagnosis, CT attenuation from thin skulls and small heads (abstr). *AJNR* 1982;3:97
5. Ohtsuki F. Developmental changes of the cranial bone thickness in the human fetal period. *Am J Phys Anthropol* 1977;46:141-153
6. Revak CS. Mineral content of cortical bone measured by computed tomography. *J Comput Assist Tomogr* 1980;4:342-350
7. Zatz LM, Alvarez RE. An inaccuracy in computed tomography: the energy dependence of CT values. *Radiology* 1977;124:91-97
8. Rao PS, Alfidi RJ. The environmental density artifact: a beam-hardening effect in computed tomography. *Radiology* 1981;141:223-227
9. Di Chiro G, Brooks RA, Dubal L, Chew E. The apical artifact: elevated attenuation values toward the apex of the skull. *J Comput Assist Tomogr* 1978;2:65-70
10. Norman D, Price D, Boyd D, Fishman R, Newton TH. Quantitative aspects of computed tomography of the blood and cerebrospinal fluid. *Radiology* 1977;123:335-338