

Are your **MRI contrast agents** cost-effective?

Learn more about generic **Gadolinium-Based Contrast Agents**.



FRESENIUS
KABI

caring for life

AJNR

CT recognition of thorotrast-induced intracranial and lumbar arachnoiditis.

A W Kaplan, S S Teng and A H Koo

AJNR Am J Neuroradiol 1984, 5 (3) 323-325

<http://www.ajnr.org/content/5/3/323.citation>

This information is current as
of April 23, 2024.

CT Recognition of Thorotrast-Induced Intracranial and Lumbar Arachnoiditis

Andrew W. Kaplan,^{1,2} Stephen S. Teng,¹ and Andrew H. Koo¹

In the 1930s and 1940s the radioactive contrast material colloidal thorium dioxide (Thorotrast) was frequently used in radiographic examinations. The agent was used mainly for angiography and to a lesser extent for myelography, ventriculography, pyelography, and hepatolienography. The late clinical complications and conventional radiographic manifestations of thorium administration have been well documented. We report a case of chronic arachnoiditis and myelopathy to illustrate the unusual but probably diagnostic computed tomographic (CT) appearance of the head and spine.

Case Report

A 59-year-old man was admitted to Santa Clara Valley Medical Center for treatment of vomiting and hematemesis. He had a history of mental retardation and multiple previous psychiatric admissions. According to a family member the patient had a neurosurgical procedure performed during childhood for a "brain tumor." In addition to the retardation, the patient had chronic neurologic problems including a 20 year history of bowel and bladder incontinence and bilateral deafness with onset 10 years before admission. The family also had noted more recent facial and progressive right leg weakness.

Admission physical examination revealed both motor and sensory neurologic deficits including multiple cranial nerve abnormalities. Right optic nerve atrophy, external ophthalmoplegia, left facial weakness, complete bilateral neurosensory hearing loss, right leg weakness, and bowel and bladder incontinence were among the findings noted. Comprehensive medical and radiologic evaluation was undertaken that included CT scans of the head and spine and lumbar myelography. Noncontrast CT brain scans revealed moderate dilatation of the ventricles. Extensive diffuse high-attenuation densities were present surrounding the pial surfaces of the cerebrum and cerebellum and within the basal cisterns, periventricular subependyma, and the choroid plexus (figs. 1A–1D). CT of the lumbar spine demonstrated similar high density outlining the thecal sac (fig. 1E). Both the intracranial and lumbar radiopaque densities were present but less striking on the plain radiographs. A metrizamide lumbar myelogram showed deformity of the thecal sac with nerve root adhesions consistent with arachnoiditis (fig. 1F).

These findings were initially considered to represent diffuse central nervous system calcification with arachnoiditis probably related to prior granulomatous or inflammatory process. Cerebrospinal fluid analysis and other laboratory studies failed to provide a definitive

diagnosis. A lumbar meningeal biopsy was subsequently performed and demonstrated reactive fibrosis of the dural and epidural tissues with deposition of numerous amorphous refractile granules within the tissues (fig. 1G). Of note is that no dystrophic calcifications were present. When these tissues were subjected to analysis utilizing a multichannel germanium lithium detector, daughter products (²¹²Pb and ²²⁸Ac) from the radioactive decay chain of thorium were detected.

Discussion

Radioactive thorium dioxide has a biologic half-life of 400 years and a physical half-life of 1.39×10^{10} years. The emission consists mainly of alpha particles (90%) and some beta (9%) and gamma (1%) radiations. It was first used as a radiographic contrast medium in 1928 [1], but it was not until 1947 that the first suspected case of thorium induced malignancy was reported [2]. Since then the association of thorium administration with subsequent development of various malignancies has been well documented. Among the tumors reported include meningioma [3], cholangiocarcinoma [4], hepatoma [5], various bone tumors [6], neoplasms of the urinary tract [7–9], multiple myeloma, and leukemia [10]. The exact number of patients who underwent radiologic studies using thorium is uncertain, but it has been estimated that as many as 50,000 patients worldwide had received the agent by 1947 [11].

Thorium was used initially for angiographic studies, and in 1932 was first used as a myelographic agent [12]. Its use for myelography and ventriculography was subsequently limited but continued despite concerns regarding experimental animal studies demonstrating the development of arachnoiditis and hydrocephalus after intrathecal administration [13–15]. When injected into the subarachnoid space Thorotrast is distributed according to the dynamics of the flow of the cerebrospinal fluid. It is eventually deposited in the macrophages and histiocytes of the arachnoid and meninges, along the ependymal lining of the ventricles, and perivascularly in the endoneurium of various cranial nerves and spinal nerve roots. Marked meningeal inflammation and subsequent fibrosis follows. The most frequently reported clinical sequelae include cauda equina syndrome, arachnoiditis, progressive

Received November 3, 1982; accepted after revision January 28, 1983.

¹ Department of Radiology, Santa Clara Valley Medical Center, 751 S. Bascom Ave., San Jose, CA 95128. Address reprint requests to S. S. Teng.

² Present address: Department of Diagnostic Radiology, Oregon Health Sciences University, Portland, OR 97201.

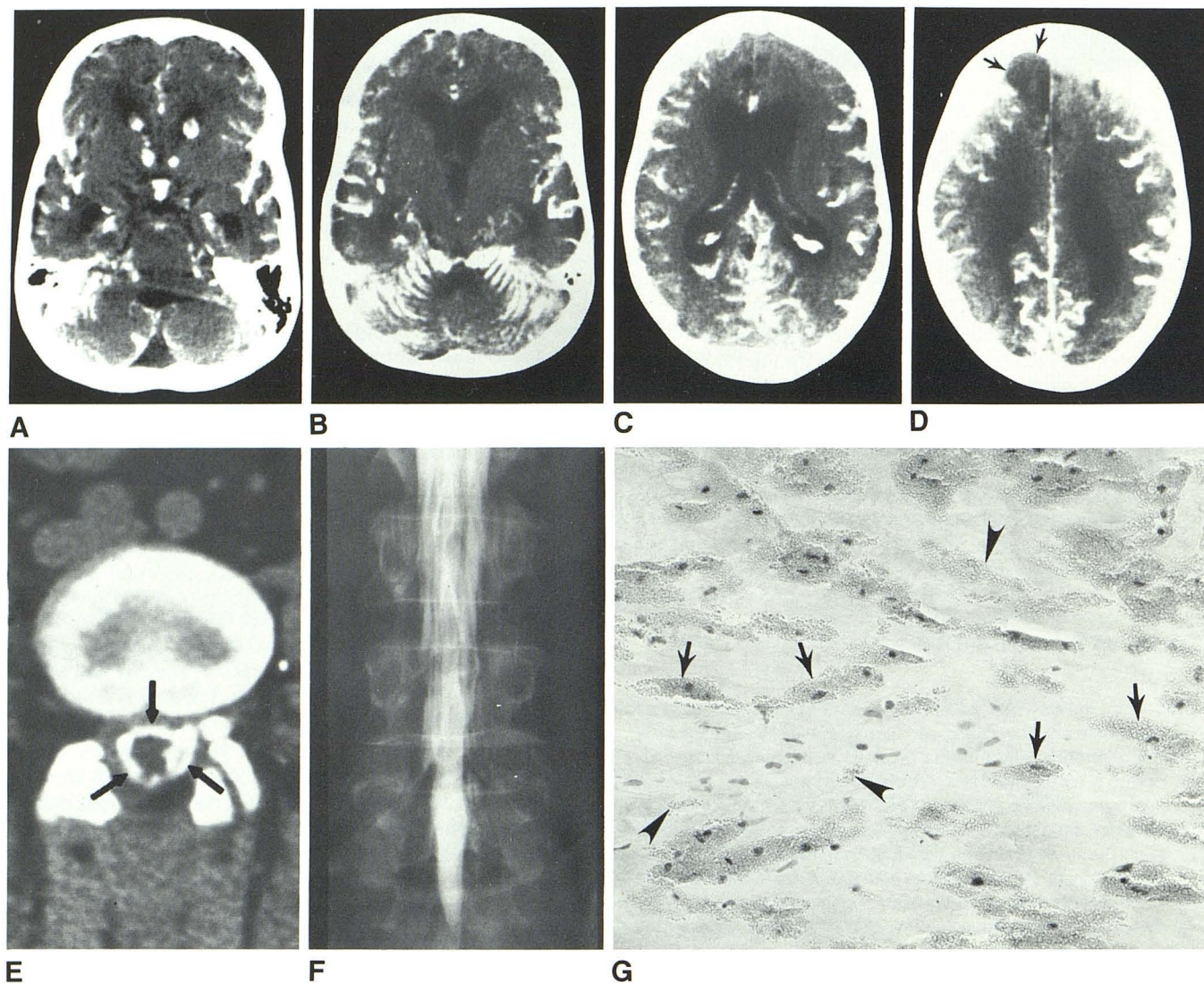


Fig. 1.—A, Nonenhanced CT brain scan. High-density Thorotrast involving choroid plexus, subependyma, and basal arachnoid cisterns. B–D, Thorotrast on pial surfaces of cerebellum and cerebrum. Moderate ventricular dilatation. Right frontal arachnoid cyst (D), possibly related to chronic inflammatory process. CT numbers of high-density material in range of 140–150 H. E, Noncontrast CT of lumbar spine. Similar high-attenuation Thorotrast outlining

thecal sac (arrows). F, Metrizamide lumbar myelogram. Deformity of thecal sac associated with multiple nerve root adhesions consistent with arachnoiditis. G, Photomicrograph of lumbar meningeal biopsy specimen. Clumps of amorphous refractile granules in extracellular tissues (arrowheads) and macrophages (arrows).

myelopathy, and multiple cranial nerve deficits [16–18]. These often develop 10–15 years after myelography. Our patient's symptoms of deafness, facial weakness, ophthalmoplegia, and bowel and bladder incontinence are characteristic complications of intrathecal thorium administration. The lack of a definitive history of prior Thorotrast administration is not unusual and likely attributable to the long interval between the administration of the contrast medium and development of symptoms. In these instances the diagnosis is often made primarily by radiologic studies [19]. In our patient the CT demonstration of diffuse high attenuation involving the meninges of the brain and spinal cord was more striking than the plain radiographic findings. This CT appearance is similar to the findings in a case of intracranial thorium described by Sinnott and Citrin [20].

Arachnoiditis secondary to thorium administration should

be considered in a patient who presents with multiple unexplained neurologic abnormalities including cranial nerve palsies and cauda equina syndrome. The CT demonstration of diffuse abnormal high density surrounding the brain and spinal cord provides strong confirmatory evidence and may be diagnostic of this entity.

ACKNOWLEDGMENTS

We thank Maie Herrick for obtaining the final pathologic diagnosis and Sheila Smith of the Stanford Health Physics Department for technical assistance.

REFERENCES

1. Bluhbaum TH, Frik K, Kalkbrenner A. Eine neue Anwendungsart der Kolloide in der Roentgendiagnostik. *ROFO* 1928;37:18–29

2. MacMahon E, Murphy AS, Bates MD. Endothelial cell sarcoma of liver following Thorotrast injections. *Am J Pathol* **1947**; 23:585-612
3. Kyle RH, Oler A, Lasser EC, Rosomoff HL. Meningioma induced by thorium dioxide. *N Engl J Med* **1963**;268:80-82
4. Dahlgren S. Thorotrast tumors. A review of the literature and report of two cases. *Acta Pathol Microbiol Scand* **1961**;53:147-161
5. Smoron GL, Batliofora HA. Thorotrast-induced hepatoma. *Cancer* **1972**;30:1252-1259
6. Harrist TJ, Schiller AL, Trelstad RL, Mankin HJ, Mays CW. Thorotrast-associated sarcoma of bone. A case report and review of the literature. *Cancer* **1979**;44:2049-2058
7. Griffiths MH, Thomas DP, Xipell JM, Hope RN. Thorotrast-induced bilateral carcinoma of the kidney. *Pathology* **1977**;9:43-48
8. Mihatseh MJ, Rutishauser G. Thorotrast-induced transitional cell carcinoma in a residual ureter after nephrectomy. *Cancer* **1973**;23:139-154
9. Westin J, Lanner LO, Weinfeld A, Zettergren L. Renal pelvic carcinoma after thorotrast pyelography. Case report. *Acta Med Scand* **1973**;194:141-143
10. daSilva Horta J, daMotta LC. Follow-up study of thorium dioxide patients in Portugal. *Ann NY Acad Sci* **1967**;145:830-842
11. Grampa G. Radiation injury with particular reference to Thorotrast. *Pathol Annu* **1971**;6:147-169
12. Radovici A, Meller O. Essai de liquidographie cephalorachidienne. Encephalographie par le Thorotrast sous arachnoidien. *Bull Acad Med (Paris)* **1932**;107:314-317
13. Nosik WA. Intraspinal Thorotrast. *AJR* **1943**;49:214-218
14. Reeves DL, Stuck RM. Clinical and experimental results with Thorotrast. *Medicine* **1938**;17:37-73
15. Stuck RM, Reeves DL. Dangerous effects of Thorotrast used intracranially with special reference to experimental production of hydrocephalus. *Arch Neurol Psychiatr* **1938**;40:86-115
16. Boyd JT, Langlands AO, MacCabe JJ. Long-term hazards of Thorotrast. *Br Med J* **1968**;2:517-521
17. Dale AL, Love G. Thorium dioxide myelopathy. *JAMA* **1967**; 199:606-609
18. Meyer M, Powell MB, Wagner BA, Niwayama G. Thorotrast-induced adhesive arachnoiditis associated with meningioma and schwannoma. *Hum Pathol* **1978**;9:366-370
19. Gondos B. Late clinical and roentgen observations following Thorotrast administration. *Radiology* **1973**;24:195-203
20. Sinnott RG, Citrin CM. Computed tomography of intrathecal Thorotrast. *Neuroradiology* **1981**;20:257-259