

Are your **MRI contrast agents** cost-effective?

Learn more about generic **Gadolinium-Based Contrast Agents**.



FRESENIUS
KABI

caring for life

AJNR

Computed tomography of a false postoperative meningocele.

R G Ramsey and R D Penn

AJNR Am J Neuroradiol 1984, 5 (3) 326-328

<http://www.ajnr.org/content/5/3/326.citation>

This information is current as
of April 19, 2024.

Computed Tomography of a False Postoperative Meningocele

Ruth G. Ramsey¹ and Richard D. Penn²

False meningoceles following laminectomy have been reported; however, calcified postoperative meningoceles have not been demonstrated by computed tomography (CT). These cystic lesions may be considered as postoperative false (or spurious) meningoceles. The development of these changes occurs because a collection of cerebrospinal fluid (CSF) accumulates in the soft tissue through a rent in the dura. The surrounding soft tissues can absorb only a finite amount of fluid; then a connective tissue reaction occurs that walls off the CSF. In rare instances, as seen in our case, the connective tissue can calcify, thus forming a false postoperative meningocele.

Case Report

A 26-year-old man originally was seen after 3 months of low back pain that radiated down the left leg. Myelography demonstrated an intradural defect (fig. 1A) at the L5 level with displacement of the nerve roots of the cauda equina to the right side. There was also a large extradural component of the mass on the left side that displaced the entire lumbar cul-de-sac to the contralateral side. Close examination revealed that there were also additional focal areas of widening of the individual nerve roots of the cauda equina.

The patient was operated through a wide laminectomy at the L4–L5 level and a plexiform neurofibroma was removed. At the operative site, after removal of the neurofibroma, a small posterior hole in the dura was packed with Gelfoam. A dural patch was not put in place at the operative site.

The patient did well for several months and then returned with increasing low back pain. At this time the pain did not radiate down either leg. Myelography revealed a complete block to the flow of contrast material at the L4 level. The block suggested an extradural lesion that dissected superiorly along the left lateral aspect of the canal at the L3 level, displacing the contrast column to the right (fig. 1B). A lateral radiograph (fig. 1C) and anteroposterior tomogram (fig. 1D) revealed pressure erosion of the spinous process of L3 and an expanding lesion with a calcified rim that extended from the L4 level inferiorly to the level of the sacrum.

The calcified cystic lesion, not visible on the myelogram, was readily apparent on the tomograms, while the eggshell-thin calcified rim could be seen on the lateral radiograph projecting posteriorly into the soft

tissues (fig. 1D). These studies were followed by a CT scan of the lumbar region, which demonstrated that water-soluble contrast material, not previously visible, had actually entered into the cystic, calcified, postoperative meningocele (fig. 1E). This false meningocele extended posteriorly from the operative site into the soft tissues of the back. The calcified rim was smooth and well defined and extended posteriorly to just below the skin of the back. The contrast material readily identified on the CT scan could not be appreciated on the initial radiographic studies, even in retrospect.

The patient was reoperated, and, after the calcified roof of the CSF-filled cyst was removed, a 1 cm opening in the dura was visualized and CSF could be identified leaking through this rent in the dura. The calcified, cystic, false meningocele was totally removed and the dural rent was closed with a dural patch. The patient had an uneventful postoperative course and became pain-free.

Discussion

Our case is an example of a postoperative false meningocele that calcified in its peripheral margin. A remarkably similar case of a calcified postoperative meningocele was reported by Rosenblum and DeRow [1] in 1963. We believe that this is the first time this entity has been identified by CT.

A noncalcified, postoperative, false meningocele was reported in 1946 by Hyndman and Gerber [2], and additional reports followed. However, this postsurgical complication appears to be uncommon. Previous reports [1–13] all emphasized that the etiology of these lesions is an opening in the dura that allows CSF to leak into the soft tissues. It appears that these false lumbar meningoceles occur when the dura is inadequately closed after intentional or inadvertent opening of the dura at surgery.

When CSF accumulates in the soft tissues, only a limited amount can be absorbed. When this point is reached a fibrous reactive membrane forms that walls off the collection of CSF. Eventually this nonabsorbing fibrous wall may become calcified, as happened in our case. The interval between operation and onset of symptoms is variable.

Congenital cysts have also been reported, and they may or may not be lined with an arachnoid membrane. They are

Received November 19, 1982; accepted after revision March 1, 1983.

¹ Department of Diagnostic Radiology, Section of Neuroradiology, Rush–Presbyterian–St. Luke's Medical Center, 1753 W. Congress Parkway, Chicago, IL 60612. Address reprint requests to R. G. Ramsey.

² Department of Neurosurgery, Rush–Presbyterian–St. Luke's Medical Center, Chicago, IL 60612.

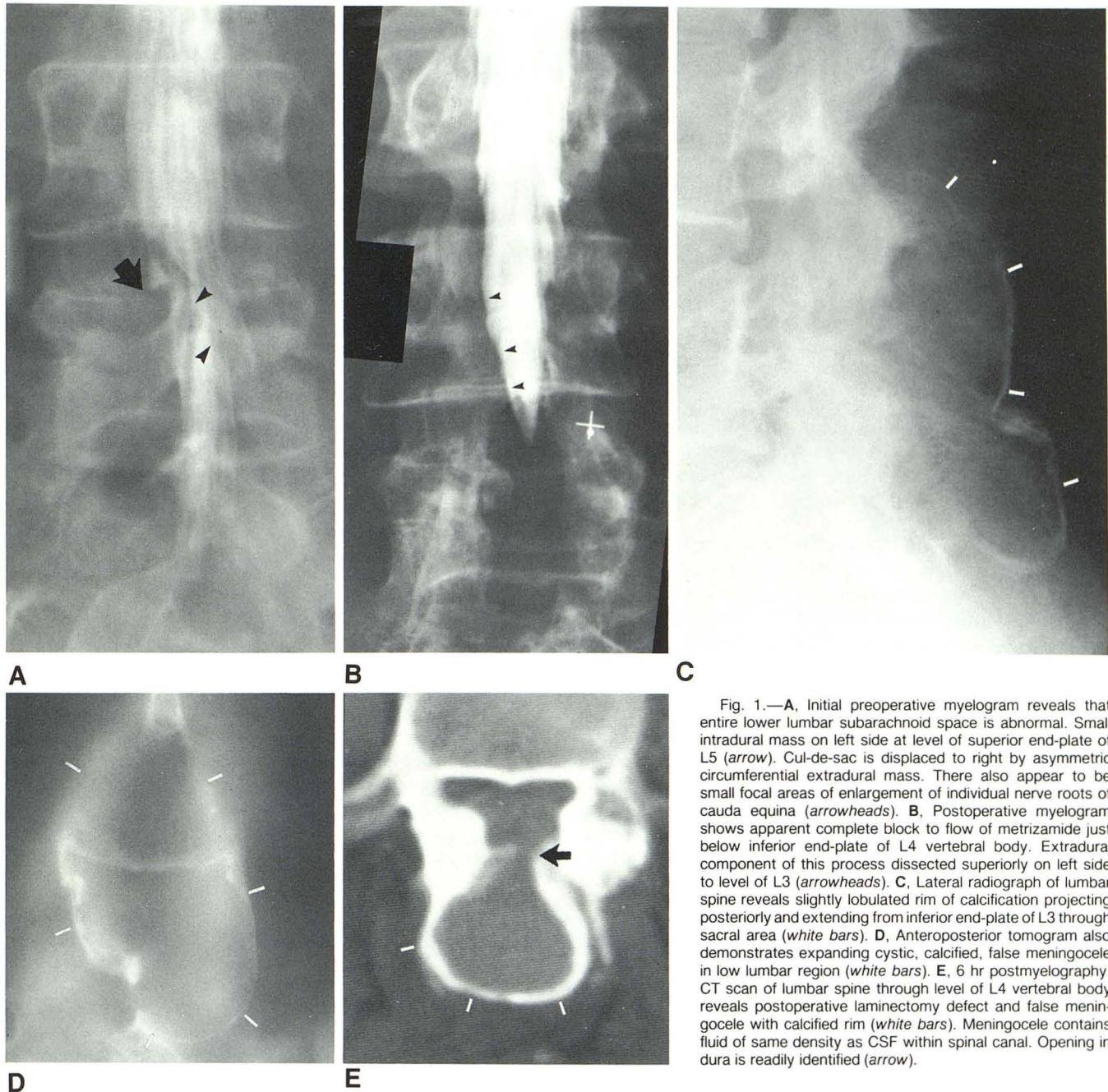


Fig. 1.—A, Initial preoperative myelogram reveals that entire lower lumbar subarachnoid space is abnormal. Small intradural mass on left side at level of superior end-plate of L5 (arrow). Cul-de-sac is displaced to right by asymmetric circumferential extradural mass. There also appear to be small focal areas of enlargement of individual nerve roots of cauda equina (arrowheads). B, Postoperative myelogram shows apparent complete block to flow of metrizamide just below inferior end-plate of L4 vertebral body. Extradural component of this process dissected superiorly on left side to level of L3 (arrowheads). C, Lateral radiograph of lumbar spine reveals slightly lobulated rim of calcification projecting posteriorly and extending from inferior end-plate of L3 through sacral area (white bars). D, Anteroposterior tomogram also demonstrates expanding cystic, calcified, false meningocele in low lumbar region (white bars). E, 6 hr postmyelography. CT scan of lumbar spine through level of L4 vertebral body reveals postoperative laminectomy defect and false meningocele with calcified rim (white bars). Meningocele contains fluid of same density as CSF within spinal canal. Opening in dura is readily identified (arrow).

usually found in the thoracic region and are thought to be secondary to impaired venous drainage from the vertebral bodies in the presence of kyphosis [2]. Other acquired cysts may develop secondary to trauma in which there is a laceration in the dura. One case of an acquired arachnoid cyst was thought to be secondary to a rent in the dura after severe paroxysm of coughing with herniation of the arachnoid through the dural tear [11].

The older literature reports that these cysts may or may not fill with Pantopaque and may even require placing the patient supine for demonstration. These cysts are demonstrated to better advantage with water-soluble contrast material,

and the use of Pantopaque is strongly discouraged. Myelography and even tomography after myelography may not reveal contrast material within the cyst; however, postmyelography CT readily demonstrates the accumulation of even very low concentrations of contrast material, as seen in our case. It is postulated that, with the added technique of postmyelography CT, contrast material will probably be demonstrated in virtually all cases.

Although postoperative false meningoceles have been reported, they are probably rare. However, if symptoms do recur in an individual patient, an acquired cyst should be considered in the differential diagnosis. With surgical removal

of these acquired abnormalities and repair of the dural laceration, the prognosis is good because the lesion is benign. With metrizamide myelography followed by spinal CT, this diagnosis is readily confirmed and the anatomy can be demonstrated to excellent advantage.

REFERENCES

1. Rosenblum DJ, DeRow JR. Spinal extradural cysts: with report of an ossified spinal extradural cyst. *AJR* **1963**;90:1227-1230
2. Hyndman OR, Gerber WF. Spinal extradural cysts, congenital and acquired: report of cases. *J Neurosurg* **1946**;3:474-486
3. Cobb C, Ehni G. Herniation of the spinal cord into an iatrogenic meningocele. Case report. *J Neurosurg* **1973**;39:4:533-536
4. Dobrzaniecki W, Haak E. Meningocele spinalis traumatica spuria. *Ann Surg* **1942**;116:150-153
5. Detoit JG, Fainsinger MH. Spinal extradural cysts. *J Bone Joint Surg [Br]* **1948**;30:613-618
6. Ford LT. Complications of lumbar-disc surgery, prevention and treatment: local complications. *J Bone Joint Surg [Am]* **1968**;50:418-428
7. Good CA, Adson AW, Abbott KH. Spinal extradural cyst (diverticulum of spinal arachnoid): report of case. *AJR* **1944**;52:53-56
8. Miller PR, Elder FW Jr. Meningeal pseudocysts (meningocele spurious) following laminectomy: report of ten cases. *J Bone Joint Surg [Am]* **1968**;50:268-276
9. Pagni CA, Cassinari V, Barnasconi V. Meningocele spurious following hemilaminectomy in a case of lumbar discal hernia. *J Neurosurg* **1961**;18:709-710
10. Rinaldi I, Peach WF Jr. Postoperative lumbar meningocele. Report of two cases. *J Neurosurg* **1969**;30:504-507
11. Swanson HS, Fincher EF. Extradural arachnoidal cysts of traumatic origin. *J Neurosurg* **1947**;4:530-538
12. Turner OA. Spinal extradural cyst: report of case with particular reference to possible diagnostic aid. *Arch Neurol* **1947**;58:593-600
13. Winkler H, Powers JA. Meningocele following hemilaminectomy: report of two cases. *NC Med J* **1950**;11:292-294