

Are your **MRI contrast agents** cost-effective?

Learn more about generic **Gadolinium-Based Contrast Agents**.



FRESENIUS
KABI

caring for life

AJNR

ECG-Synchronized DSA Exposure Control: Improved Cervicothoracic Image Quality

William M. Kelly, Robert Gould, David Norman, Michael
Brant-Zawadzki and Lauranne Cox

AJNR Am J Neuroradiol 1984, 5 (4) 429-432

<http://www.ajnr.org/content/5/4/429>

This information is current as
of April 19, 2024.

ECG-Synchronized DSA Exposure Control: Improved Cervicothoracic Image Quality

William M. Kelly¹
Robert Gould
David Norman
Michael Brant-Zawadzki
Lauranne Cox

An electrocardiogram (ECG)-synchronized x-ray exposure sequence was used to acquire digital subtraction angiographic (DSA) images during 13 arterial injection studies of the aortic arch or carotid bifurcations. These "gated" images were compared with matched "ungated" DSA images acquired using the same technical factors, contrast material volume, and patient positioning. Subjective assessments by five experienced observers of edge definition, vessel conspicuousness, and overall diagnostic quality showed overall preference for one of the two acquisition methods in 69% of cases studied. Of these, the ECG-synchronized exposure series were rated superior in 76%. Linear intensity gradients across vessel margins generally showed improved or unchanged edge definition in the gated subtraction images as compared with their ungated pairs. These results, as well as the relatively simple and inexpensive modifications required, suggest that routine use of ECG exposure control can facilitate improved arterial DSA evaluations of suspected cervicothoracic vascular disease.

Although the appearance of digital subtraction angiography (DSA) equipment on the imaging scene several years ago was heralded with great enthusiasm [1-5], some of that initial excitement has been tempered with clinical experience. Early criticism focused on the inherently poor spatial resolution of first-generation DSA units as compared with direct film-screen radiography. Recent technologic advances such as improved image intensifier design, low-noise video cameras, expanded digital matrices, and more powerful computers have dramatically improved spatial detail and account, in part, for increasing displacement of conventional film-screen technique. The critical attention of users now has shifted to concerns of vessel conspicuousness, edge definition, and reduction of motion artifact.

One approach has been the use of an assortment of postprocessing computer algorithms including remasking, reregistration, smoothing, edge enhancement, and histogram equalization. A complementary approach designed to reduce undesired motion effects is modification of the image acquisition such that image degradation secondary to cardiac motion is minimized. We undertook to evaluate the utility of electrocardiogram (ECG) gating of image acquisition. We expected that ECG gating would improve delineation of large central arteries most affected by pulsatile cardiac activity. Since the adverse effects of misregistration are most apparent at margins of inherently high contrast interface and most difficult to control in grossly pulsative vessels, we confined our consideration to the aortic arch and carotid bifurcations.

Subjects and Methods

Equipment

The DSA unit was a prototype system (Picker International/ADAC Inc.). Images using a 0.6-mm nominal-focal-spot x-ray tube were generated at rates of up to 1.8/sec. The voltage signal output of a standard cardiac monitor, interfaced with the computer-controlled x-ray

This article appears in the July/August 1984 issue of *AJNR* and the October 1984 issue of *JJR*.

Received August 3, 1983; accepted after revision December 17, 1983.

Presented at the annual meeting of the American Society of Neuroradiology, San Francisco, June 1983.

¹All authors: Department of Radiology, M-396, University of California, San Francisco, CA 94143. Address reprint requests to D. Norman.

AJNR 5:429-432, July/August 1984
0195-6108/84/0504-0429 \$2.00

© American Roentgen Ray Society

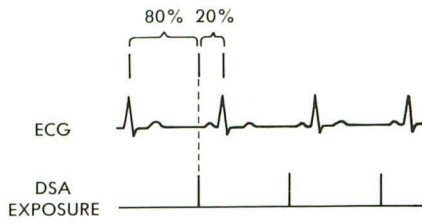


Fig. 1.—ECG-DSA synchronization. R wave of patient's electrocardiogram serves as timing signal for synchronization of DSA exposures. Trigger delay set at 80% of computed R-R interval places each x-ray pulse in late diastole, where minimal cardiovascular motion occurs.

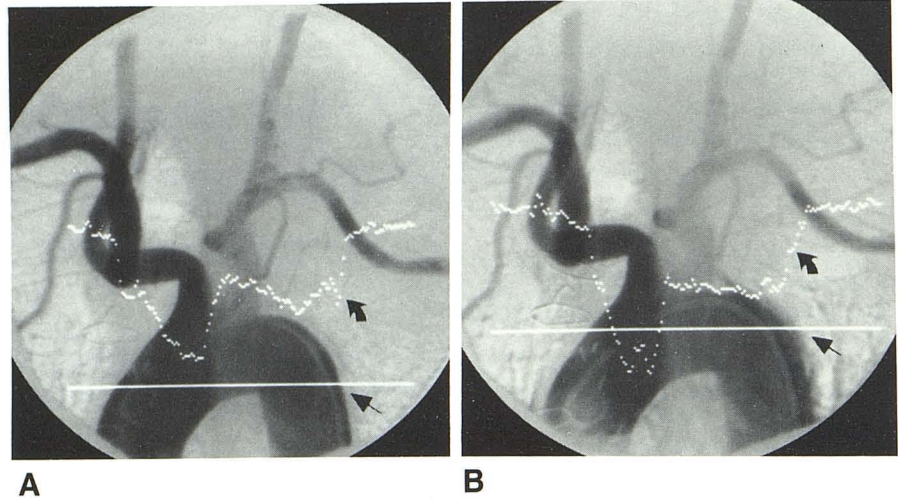


Fig. 2.—Computer-generated displays of relative exposure intensities across vessel margins. Curves plotted indicate density gradients corresponding to pixel values along respective horizontal lines. Gated study (A) shows more rapid gradient (curved arrow) at aortic margin (straight arrow) than corresponding ungated study (B). Edge definition is improved in gated study.

generator, permitted ECG-synchronized exposures in the "gated" series, triggered at a fixed time in the patient's R-R interval. The image intensifier was trimodal (22.9 cm, 15.2 cm, and 11.4 cm diam). The exposure time for each image was 33 msec (one video frame) although the total exposure time per x-ray pulse was 133 msec (three video frames were used for system stabilization). Exposure factors were 65–80 kVp, and 100–400 mA. Subtraction images were recorded with a multiformat camera (Matrix Instruments, Inc.).

Clinical Subjects/Technique

In 10 subjects referred for evaluation of suspected extracranial vascular disease, 26 arterial injection DSA "runs" were performed. The runs were paired, half being gated and half ungated. The radiographic projection was the same in each pair. Subjects were 44–76 years of age. Vascular access was by standard Seldinger puncture of the common femoral artery. Conray 60 (28 mg I/dl) diluted with saline to a 25% solution (12 mg I/dl) was used for both aortic arch and carotid studies. Five paired aortic arch studies were performed in five patients through a 5 French polyurethane pigtail catheter using an injection volume of 40 ml at a rate of 20 ml/sec. Eight paired carotid studies were obtained using a 7 French polyurethane catheter tapered to a 5 French distal limb. Injection volume was 10 ml at a rate of 6 ml/sec. The ungated (unsynchronized) exposure series at a fixed rate of 1.8/sec was followed by a repeat injection with ECG-synchronized exposures at rates varying from 0.8 to 1.8/sec, depending on the patient's heart rate. A preliminary 15-cycle computer analysis of the ECG signal is required for determination of the average R-R interval. X-ray exposures were triggered at 80% of the R-R interval (fig. 1). X-rays were thus triggered in late diastole, the period of least cardiac motion. Post-processing reregistration of subtraction images was performed on several acquisition sequences but was limited to compensation of artifact due to inadvertent patient motion occurring between the mask and contrast image.

Subjective Assessments

Five experienced observers independently examined hard-copy images without knowledge of which images in a pair were gated or ungated. Each of the evaluators was requested to indicate a prefer-

TABLE 1: Acquisition Method of Preferred Image in Cumulative Evaluations (n = 65) of Five Observers

Criterion	No. (%) of Observations		
	Preference Indicated	Ungated Preferred	Gated Preferred
Overall diagnostic quality	45 (69)	11 (24)	34 (76)
Edge definition	35 (54)	9 (26)	26 (74)
Vessel conspicuousness	34 (52)	9 (26)	25 (74)

Note.—Thirteen paired (ungated/gated) DSA studies were evaluated independently by five experienced observers.

ence or lack of preference for one of the two acquisition methods for each of the 13 paired examinations. Evaluation criteria included comparisons of arterial edge definition, vessel conspicuousness, and overall diagnostic quality.

Analytical Measurements

Edge definition was also analyzed objectively by means of a computer-generated graphic display of pixel values across a portion of image indicated by a line designated at the video display terminal. Edge definition was determined by the relative exposure (slope) gradient, displayed graphically. This method permitted direct objective comparison of the two acquisition techniques (fig. 2).

Results

The cumulative observer preferences for gated or ungated images are presented in table 1. When overall image quality was assessed, a preference was indicated in 45 (69%) of 65 comparisons, the gated image being preferred in 76% of these. When edge definition and vessel conspicuousness were judged, a preference was stated in slightly over 50% of comparisons, the gated image being preferred in 74% of these.

An example of motion artifact reduction achieved by ECG gating in a carotid study is illustrated in figure 3. The ungated subtraction image shows blurring of a calcified plaque, due to

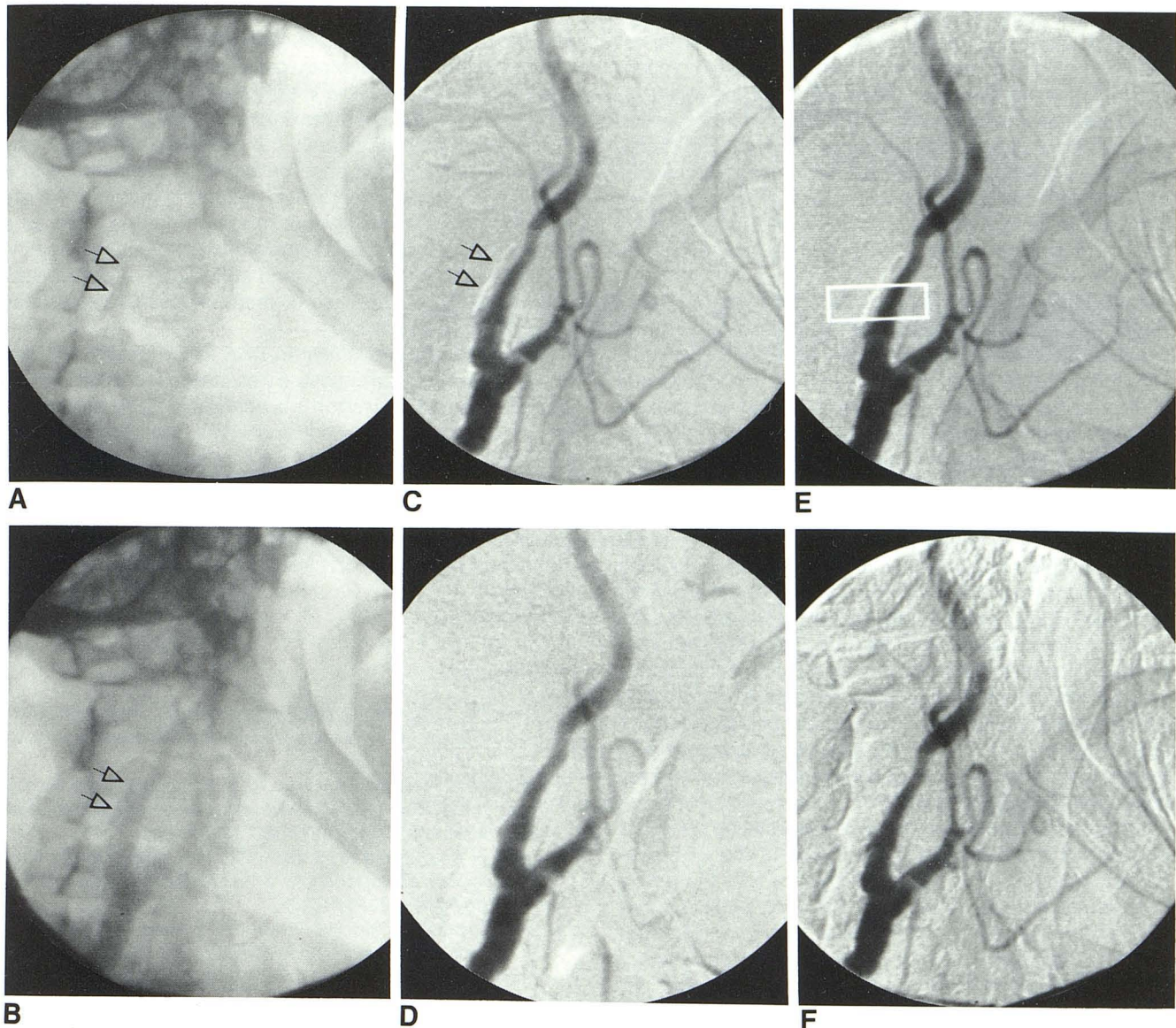


Fig. 3.—Series of DSA images illustrating advantages of ECG-gated exposures for improved registration of calcified carotid plaque. Raw mask image (A) and contrast-laden image (B) show location of calcium within plaque and its relation to vessel lumen (arrows). "Ungated" subtraction image (C) shows

misregistration of plaque (arrows) due to pulsatile motion occurring between mask and raw image. D, Artifact-free "gated" subtraction image of same lesion. E and F, Selective reregistration of ungated DSA indicated by rectangle results in introduction of undesired misregistration along nonvascular interfaces.

misregistration from cardiovascular motion.

In three instances in which ungated DSA images were preferred more often than gated images, the gated study was most often degraded by artifact related to nonvascular motion such as swallowing, breathing, or rotational movement occurring between the mask and contrast image. Occasionally there was preference for the slightly misregistered (due to pulsatile motion) ungated subtraction image in which a calcific plaque could be visualized which was not appreciated on the gated image because of its better registration.

The computer-generated display of linear pixel-value gradients across vessel margins generally provided data showing improved or unchanged edge definition in the gated DSA series as compared with the ungated pair (fig. 2). Exceptions mirrored the corresponding subjective evaluations and again were usually attributable to gross nonvascular motion artifact.

Discussion

The theoretical advantage of ECG exposure control for improved registration of pulsatile vascular structures was confirmed in practice by the overall preference of the observers for ECG-gated images. However, those cases in which ECG gating did not result in significant increase in image quality deserve attention. Several factors may account for a lack of perceived improvement in image quality. Occasionally, an ungated subtraction image may be perfectly registered with respect to pulsatile vessel motion due to fortuitous timing of the mask and raw image exposures; that is, they may happen to occur in the same phase of the cardiac cycle. More rapid framing rates would increase the frequency of such an event but at the cost of extra radiation exposure. Also, effective use of postprocessing algorithms such as remasking

or reregistration may occasionally salvage an otherwise unacceptable ungated subtraction image. However, it is not unusual to find that ensemble pixel-shifting, used to compensate for plaque motion, may artifactually introduce misregistration at adjacent nonvascular high-contrast interfaces, such as cervical spine, larynx, and hyoid bone, that did not participate in the pulsatile motion. Such a result is often counterproductive and may in fact obscure vascular detail in other regions of an image (fig. 3). The availability of region-of-interest reregistration in the near future may help avoid this problem.

With respect to carotid bifurcation imaging, the frequent absence of calcium within plaques results in homogeneous density of the unopacified vessels and bordering tissues before the arrival of contrast material. Thus, the deleterious effects of pulsatile motion often escape being encoded as misregistration on a subtraction image. In the chest, however, there is an intrinsic and constant density differential at the interface of the aorta and adjacent aerated lung on masked images. This interface undergoes oscillatory motion related to both cardiac activity and respiration. Although breathing can be interrupted temporarily with patient cooperation, the effects of pulsatile vessel motion which sometimes detract from pulsed DSA image quality can be minimized by the gating technique used herein. The anatomic juxtaposition of aerated lung against the mediastinal structures accounts for the more consistently visible improvements in subtraction image quality when ECG gating is used for arch studies. One might extrapolate that similar results may be achieved with pulmonary arteriography; encouraging results have been achieved in a recent clinical trial [6].

The observation that extraneous motion artifact contributed to suboptimal subtraction images in three of the ECG-synchronized acquisitions serves to emphasize that the gating method is not immune to the misregistration problems that often compromise routine DSA studies. However, the suggestion that misregistration of calcific plaques on ungated subtraction images may be desirable or advantageous for diagnostic purposes is untenable. Such lesions are clearly visible on both the raw mask and the contrast-laden images (fig. 3). In fact, our convention is to photograph hard copies of selected raw images both for this reason as well as to benefit the surgeon in terms of orientation and treatment planning.

Technical modifications may be desirable for gated DSA studies in patients with slow heart rates. For instance, at a cardiac rate of 50 beats/min, gated exposures occur at 1.2 sec intervals. Such a slow imaging rate may be insufficiently rapid to ensure capture of maximum contrast-material density during bolus transit through the vessel lumen. This may translate to diminished edge definition as compared with a fortuitously timed and more rapid ungated acquisition. A more prolonged injection of contrast material may be used as a compensatory technique to obtain adequate gated images in such patients. Alternatively—and preferably—a gating algorithm that incorporates two or more exposures per cardiac cycle might be devised.

Although the improvement in DSA image quality afforded by ECG-synchronized exposure was often minor in this series, we believe gated acquisition is a worthwhile technical adjunct. The procedure entails no additional time, uses an ECG monitor which is typically in use at most installations, and requires only relatively minor software modifications. For cervicothoracic studies, this method offers improved visualization of vessel margins and enables more accurate diagnosis of atheromatous stenoses, particularly when accompanied by calcification.

REFERENCES

1. Ovitt TW, Capp MP, Fischer HD, Nudelman S. The development of a digital video subtraction system for intravenous angiography. *Proc SPIE* **1978**;167:61-66
2. Kruger RA, Mistretta CA, Houk TL, et al. Computerized fluoroscopy in real time for noninvasive visualization of the cardiovascular system. *Radiology* **1979**;130:49-57
3. Strother CA, Sackett JF, Crummy AB, et al. Clinical applications of computerized fluoroscopy: the extracranial carotid arteries. *Radiology* **1980**;136:781-783
4. Christenson PC, Ovitt TW, Fisher HD III, Frost MM, Nudelman S, Roehrig H. Intravenous angiography using digital video subtraction: intravenous cervicocerebrovascular angiography. *AJNR* **1980**;1:379-386, *AJR* **1980**;135:1145-1152
5. Chilcote WA, Modic MT, Pavlicek WA, et al. Digital subtraction angiography of the carotid arteries: a comparative study in 100 patients. *Radiology* **1981**;139:287-295
6. Ludwig JW, Verhoeven LAJ, Kersbergen JJ, Overtom TTC. Digital subtraction angiography of the pulmonary arteries for the diagnosis of pulmonary embolism. *Radiology* **1983**;147:639-645