

Are your **MRI contrast agents** cost-effective?

Learn more about generic **Gadolinium-Based Contrast Agents**.



FRESENIUS
KABI

caring for life

AJNR

**Primary extradural intracranial hydatid disease:
CT appearance.**

A Ba'assiri and F S Haddad

AJNR Am J Neuroradiol 1984, 5 (4) 474-475

<http://www.ajnr.org/content/5/4/474.citation>

This information is current as
of April 17, 2024.

Primary Extradural Intracranial Hydatid Disease: CT Appearance

Aouni Ba'assiri¹ and Fouad S. Haddad²

Hydatid disease has been reported with varying frequency in most body organs. Computed tomography (CT), with its tremendous impact on neuroradiology, now has a major role in diagnosing intracerebral hydatidosis [1]. Primary intracranial epidural hydatids are extremely rare, and, in a review of the English-language literature, we were unable to find any bona fide case unassociated with cranial or cerebral involvement. We recently encountered such a case, which was studied by CT and verified surgically.

Case Report

An 18-year-old man had intermittent headaches for several years that worsened in the last 2 months. There was no history of recent trauma, vomiting, convulsions, or sensory or motor symptoms. The patient had worked as a machinist for the past 3 years with no history of prolonged canine contact.

Physical examination revealed a healthy young man in no distress. There was a definite left nasal quadrantanopia. The patient was otherwise well. Skull and chest films were normal. Routine blood tests were normal with 2% eosinophils. Weinberg and indirect hemagglutination tests were normal. CT revealed a relatively large cystic lesion in the epidural space of the posterior fossa and occipital region on the left (figs. 1A–1C). No intrinsic enhancement of the lesion was noted. Pressure erosion of the adjacent bone was seen (fig. 1D).

The lesion was considered surgical, probably a cholesteatoma, as there was a definite visual field loss, and a craniotomy revealed a multilocular epidural hydatid cyst that was removed. The underlying dura was normal. The inner table was eroded by the mass, but there was no evidence to suggest that the cyst arose from the diploic space. The patient was discharged after a radioisotopic liver-spleen scan was normal.

Discussion

The intracranial epidural space is most commonly infested with hydatids by direct extension from the calvarium. One to two percent of hydatid cysts are localized in the skeleton and only 3%–4% of these are in the skull [2]. The diploic space is primarily involved with an expansile, osteolytic process lead-

ing to bulging and thinning of the tables. Eventually, the extradural space may get involved [3, 4]. The extradural space may also rarely get infested by intracerebral cysts through an apparently healthy dura mater [5].

Our case showed no evidence of primary calvarial involvement or intracerebral hydatidosis, and the disease was completely restricted to the extradural space. Samiy and Zodeh [3] encountered a case of numerous extradural hydatids with normal skull films that showed circumscribed erosion of the inner table at craniotomy. It was interpreted as a primary calvarial lesion, but the authors did not elaborate more on the relation of the cysts to the bone [3]. Robinson [6] doubted the existence of such a condition, that is, primary extradural hydatidosis; he claimed that extradural vessels that may carry the hexacanth embryo are few or nonexistent. It is very likely that the sparse blood supply to this region has rendered it an extraordinary site of infestation. The only known way, however, by which the hexacanth embryo travels in the body is via the blood stream, and we believe the epidural involvement in this case is a rare, though definite, manifestation of this phenomenon.

Obviously, with the advent of CT, it is possible to encounter and diagnose more of these cases. The CT appearance is not diagnostic, and differentiation from other epidural cystic lesions, such as cholesteatoma, dermoid, epidural abscess, and chronic epidural hematoma, may not always be possible, especially since serologic tests are usually negative and of no help in the diagnosis of isolated infestation of the central nervous system. A thorough familiarity of the radiologist with the patient's history and clinical presentation, as well as a critical review of the conventional skull radiographs for the presence of lytic lesions, bone sinus, and fracture, may help a great deal in reaching a presumptive preoperative diagnosis.

A high index of suspicion in the appropriate geographic location is warranted to keep this rare, though distinct, entity in the radiologist's differential diagnosis, as surgical removal of the intact cyst is required to prevent progressive neurologic deficit caused by the natural tendency of these cysts to enlarge.

Received January 12, 1983; accepted after revision May 9, 1983.

¹ Department of Diagnostic Radiology, American University of Beirut Medical Center, Beirut, Lebanon. Address reprint requests to A. Ba'assiri.

² Department of Neurosurgery, American University of Beirut Medical Center, Beirut, Lebanon.

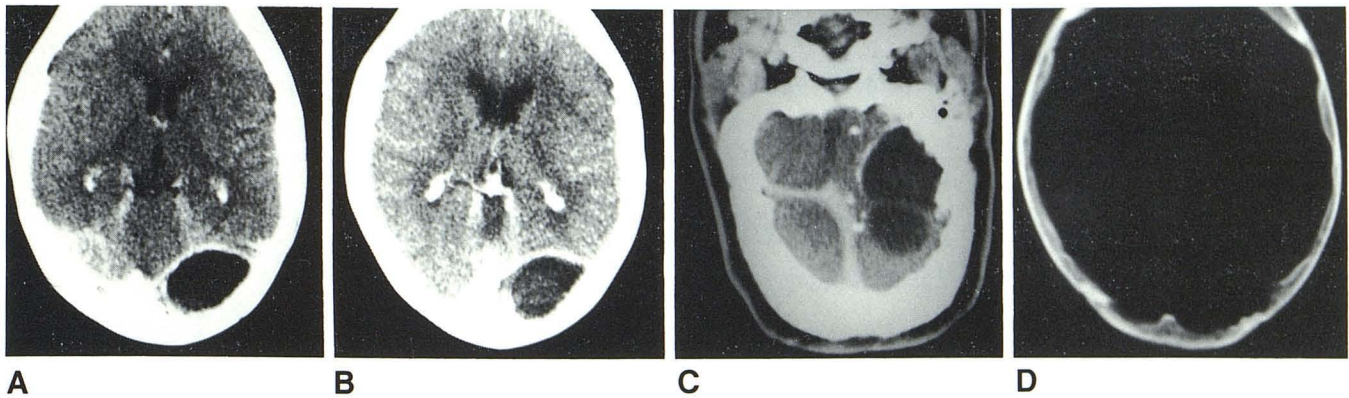


Fig. 1.—**A** and **B**, Homogeneous, cystic, nonenhancing lesion with convex inner margin indicating extradural location above and below level of tentorium. **C**, Coronal scan shows extent of lesion in posterior fossa and left occipital

region. **D**, Wide window setting reveals scalloping of inner table of occipital bone on left, characteristic of prolonged external pressure.

REFERENCES

1. Abbasioun K, Rahmat H, Ameli NO, Tafazoli M. Computerized tomography in hydatid cyst of the brain. *J Neurosurg* **1978**;49:408-411
2. Deve F. *L'echinococcose osseuse*. Montevideo, Uruguay: Montevideo, **1948**
3. Samiy H, Zodeh FA. Cranial and intracranial hydatidosis with special reference to x-ray diagnosis. *J Neurosurg* **1965**;22:425-433
4. Teymoorian GA, Bogheri F. Hydatid cyst of the skull: report of four cases. *Radiology* **1976**;118:97-100
5. Griponissiotis B. Hydatid cyst of the brain and its treatment. *Neurology (NY)* **1957**;7:789-792
6. Robinson RG. Complications neurologiques de la maladie hydatique. *World Neurol* **1961**;2:426-434