

Are your **MRI contrast agents** cost-effective?

Learn more about generic **Gadolinium-Based Contrast Agents**.



FRESENIUS
KABI

caring for life

AJNR

Detection of intracranial bleeding by ^{99m}Tc sulfur colloid scintigraphy.

G N Sfakianakis and E Sfakianaki

AJNR Am J Neuroradiol 1985, 6 (1) 126-127

<http://www.ajnr.org/content/6/1/126.2.citation>

This information is current as
of April 19, 2024.

Aging Brain and Skull

In her article in the May/June 1984 issue of *AJNR*, Dr. LeMay [1] provides a comprehensive review of the computed tomographic (CT), pneumoencephalographic, and radiographic changes of the brain and skull as seen in the aging population. She concludes that further understanding of the involutory changes in the brain may require other, more sensitive methods of investigation than are now available. One cannot disagree with that. One can disagree, however, with the statement that "regression of the brain with aging is a normal process" [1]. While she may be using *normal* in the sense defined by *Webster's New Collegiate Dictionary* (ninth edition), "as occurring naturally," I prefer to use the word *common*, "occurring or appearing frequently." To state that regression of the brain is a normal process may mislead students and scientists alike to think that large ventricles are a normal finding; thus, they may cease trying to understand the aging process. Such a statement is tantamount to saying that atherosclerosis is a normal process simply because it is seen so often on chest radiographs. On the other hand, if one takes the position that involutory changes in the brain are common but *abnormal*, the continued exploration of the causes of this phenomenon is given due importance.

There are quite a few "aged" persons, some as old as 80, whose ventricles and sulci on CT resemble those of a 25- or 30-year-old. A subjective evaluation of some of these patients suggests that they may be mentally sharper than age-matched patients with enlarged ventricles. I may be nit-picking, but I maintain that this has some conceptual importance.

David O. Davis
University Hospital
George Washington University Medical Center
Washington, DC 20037

REFERENCE

1. LeMay M. Review. Radiologic changes of the aging brain and skull. *AJNR* 1984;5:269-275, *AJR* 1984;143:383-389

Reply

There are many neuropathologic studies showing brain changes (e.g., decrease in weight, decrease in size of the massa intermedia, loss of neuronal and glial cells, decrease in cell and nucleolar size, decrease in dendritic synaptic spines and processes) that seem to be age-related. References to some of these studies were included in my review, and an excellent review of the involutory changes

documented by neuropathologic studies has been published recently by Kemper [1].

I certainly agree with Dr. Davis that large ventricles in older persons should not be considered "normal." Many years ago, when I first met Dr. Paul Yakovlev, the wonderful neuropathologist whose extensive collection of whole-brain serial sections at the Armed Forces Institute of Pathology is available for research studies, he asked me if I thought the ventricles enlarged with age. I replied that pneumoencephalographic studies suggested that the third ventricle enlarged with age, but that there was great variation in the size of the lateral ventricles. "Yes," he said, "as we age, the midportion of our brain regresses and we become sadder and more lonesome; but the main mass of the brain need not regress—or that is what I like to tell myself."

One of the tasks of the future, radiologically as well as neuropathologically, is to investigate what is abnormal—why great variation occurs in ventricular size and in the width of the superficial sulci.

Marjorie LeMay
Harvard University Health Services
Cambridge, MA 02138

REFERENCE

1. Kemper TL. Neuroanatomical and neuropathological changes in normal aging and in dementia. In: Albert ML, ed. *Clinical neurology of aging*. Oxford: Oxford University Press, 1984:9-52

Detection of Intracranial Bleeding by ^{99m}Tc Sulfur Colloid Scintigraphy

Scintigraphy with ^{99m}Tc sulfur colloid has been used to diagnose hepatosplenic injuries [1]. The same radiopharmaceutical has been used to localize gastrointestinal bleeding [2]. Whereas hepatosplenic scintigraphy is based on the phagocytic activity of the reticuloendothelial cells, detection of active bleeding is made possible by extravasation of a fraction of the injected agent while the remainder accumulates in the liver and spleen [3]. This technique also can detect internal bleeding in other parts of the body, as long as the site of hemorrhage is within the field of view of the gamma camera. The following case report illustrates this point.

A 5-year-old girl was referred to the nuclear medicine laboratory for hepatosplenic scintigraphy after being involved in a motor vehicle accident. Evidence of abdominal wall trauma, tenderness on clinical examination, a slight drop in hematocrit, and a low-normal blood pressure suggested the possibility of trauma to the liver or spleen. On arrival in the laboratory, the child was confused, disoriented, and crying; she later complained of headache. Routine liver-spleen scin-

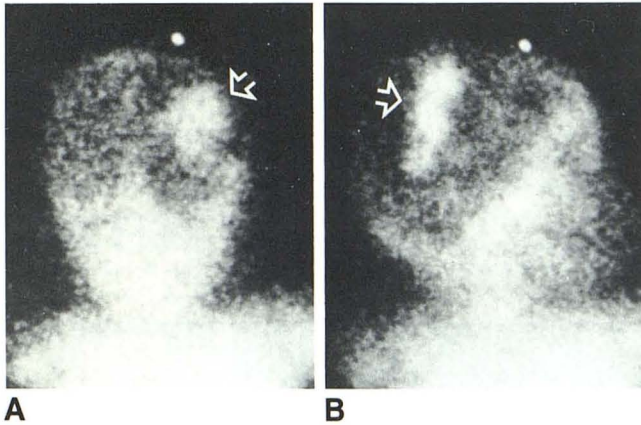


Fig. 1.—Posterior (A) and right lateral (B) cranial scintigrams obtained 1 hr after injection of ^{99m}Tc sulfur colloid. Right parietal accumulation of radionuclide (arrows) indicates active intracranial bleeding. Bone marrow activity in skeleton and pulmonary activity are physiologic findings.

tigraphy was performed after intravenous injection of 1 mCi (37 MBq) of ^{99m}Tc sulfur colloid. The scintigram was normal. Because of the nature of the accident and the clinical indications, posterior and lateral head scintigrams were obtained to explore the possibility of active bleeding in this region. These images (fig. 1) showed discrete activity in the right parietal region, suggesting intracranial bleeding. The

diagnosis was confirmed by cranial computed tomography, which demonstrated an epidural hematoma.

This case emphasizes the ability of ^{99m}Tc sulfur colloid scintigraphy to detect active bleeding in areas of the body other than the abdomen. To be detected by this method, bleeding must be active at the time of injection of the radiopharmaceutical; however, intermittent bleeding can be detected by a similar technique using ^{99m}Tc (in vivo)-labeled erythrocytes [4]. In the appropriate clinical settings, this technique may provide useful information. In particular, in children with injuries, it may orient the diagnostic workup toward a site of trauma not obvious on clinical examination.

George N. Sfakianakis

Eleni Sfakianaki

Jackson Memorial Hospital

University of Miami School of Medicine

Miami, FL 33101

REFERENCES

1. Howman-Giles R, Gilday DL, Venugopal S, Shantding B, Ash JM. Splenic trauma: non-operative management and long-term follow-up by scintiscan. *J Pediatr Surg* **1978**;13:121-126
2. Alavi A, Ring EJ. Localization of gastrointestinal bleeding: superiority of ^{99m}Tc sulfur colloid compared with angiography. *AJR* **1981**;137:741-748
3. Alavi A. Detection of gastrointestinal bleeding with Tc-99m sulfur colloid. *Semin Nucl Med* **1982**;12:126-138
4. Winzelberg GG, McKusick KA, Froelich JW, Callahan RJ, Strauss HW. Detection of gastrointestinal bleeding with Tc-99m-labeled red blood cells. *Semin Nucl Med* **1982**;12:139-146