

Are your **MRI contrast agents** cost-effective?

Learn more about generic **Gadolinium-Based Contrast Agents**.



FRESENIUS
KABI

caring for life

AJNR

Computed Tomography in the Prediction of Outcome in Head Injury

Maurice H. Lipper, P. R. S. Kishore, Gregory G. Enas, Alvaro A. Domingues da Silva, Sung C. Choi and Donald P. Becker

AJNR Am J Neuroradiol 1985, 6 (1) 7-10

<http://www.ajnr.org/content/6/1/7>

This information is current as of April 27, 2024.

Computed Tomography in the Prediction of Outcome in Head Injury

Maurice H. Lipper¹
 P. R. S. Kishore¹
 Gregory G. Enas²⁻⁴
 Alvaro A. Domingues da Silva³⁻⁵
 Sung C. Choi²
 Donald P. Becker³

To determine the prognostic significance of computed tomographic (CT) findings in head injury, retrospective analysis was performed in 128 randomly selected severe head-injury patients managed with a standardized protocol. The minimal criterion for entry into this study was that the patients were unable to obey simple commands or utter formed words. Serial CT was performed on admission and 3–5 days, 2 weeks, 3 months, and 1 year after injury. A scale of severity of abnormalities was devised taking into account the size of the traumatic lesions on CT. The CT findings using the proposed scale were correlated with the clinical outcome and analyzed using linear logistic regression. Other characteristics such as midline shift, multiplicity, and corpus callosum and brainstem lesions were not included in the analysis either because they did not affect the prognosis or because too few of these lesions were present for statistical analysis. The correct prediction rate of outcome using the proposed scale for CT findings alone was found to be 69.7%. When CT findings were combined with the Glasgow Coma Scale score this rate was increased to 75.8%.

Much interest has been focused on the prediction of outcome after head injury [1–11]. Narayan et al. [12] have shown that although the clinically assessed neurologic status of the patient and other indicants such as age are important in determining outcome, the predictive power is increased when information from multimodality evoked potentials, intracranial pressure monitoring, and computed tomographic (CT) scans is used. CT was shown to have predicted efficacy in a general sense, but all the available data from CT were not considered in that evaluation. In most cases, the presence or absence of a lesion on CT, but not its size, was used.

This article appears in the January/February 1985 issue of *AJNR* and the March 1985 issue of *AJR*.

Presented at the annual meeting of the American Society of Neuroradiology, Chicago, April 1981.

This work was supported by National Institutes of Health grant NS 12587.

¹ Department of Radiology, Box 615, Medical College of Virginia, Virginia Commonwealth University, Richmond, VA 23298. Address reprint requests to M. H. Lipper.

² Department of Biostatistics, Medical College of Virginia, Virginia Commonwealth University, Richmond, VA 23298.

³ Department of Neurosurgery, Medical College of Virginia, Virginia Commonwealth University, Richmond, VA 23298.

⁴ Lilly Research Laboratories, Division of Eli-Lilly and Co., Indianapolis, IN 47285.

⁵ Rua Hiroko Yoshimoto, 134, Londrina-PR, CEP: 86.1000, Brazil.

AJNR 6:7–10, January/February 1985
 0195–6108/85/0601–0007 \$00.00
 © American Roentgen Ray Society

Materials and Methods

A retrospective analysis of CT findings was performed in 128 severe head-injury patients. The minimal criterion for entry into the study was that the patients were unable to obey simple commands or utter formed words. Sequential serial CT scans were obtained on admission, 3–5 days, 14 days, 90 days, and 1 year after injury. The examinations were performed on a Delta scanner with a 256 × 256 matrix. Four conventional slices of the intracranial contents were obtained, including the uppermost surface of the cerebral hemispheres and, whenever possible, the posterior fossa. Each scan slice produces two images, each of which represents a brain section about 1.0 cm in thickness, resulting in eight images, which should adequately cover the entire brain.

For the purposes of this study the initial admission CT scans were examined to determine the number of slices on which hemorrhagic lesions were visible. The outcome of these patients was assessed at the end of 3 months or 1 year according to the scale proposed by Jennett and Bond [13]. For the purposes of discussion, good recovery or moderate disability is considered good outcome, and severe disability, vegetative state, and death as poor outcome. Other factors, such as bilaterality of lesions, multiplicity, midline shift, and development of new lesions, were also considered. Using this analysis the prognostic significance of the initial CT findings on their own was determined as well as the prognostic significance

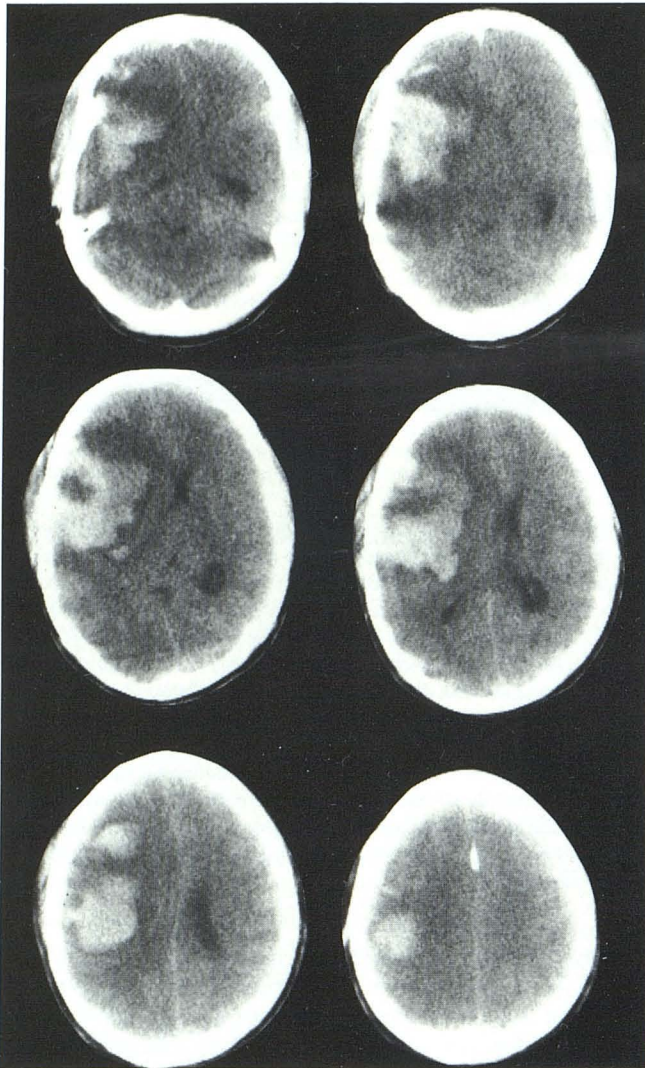


Fig. 1.—Initial CT study. Right hemispheric intracerebral hematoma on six successive slices.

of CT findings combined with the Glasgow Coma Scale (GCS) of the patient [14].

Data analysis was performed using the multiple linear logistic model [15, 16]. This model expresses the log-ratio of relative odds associated with each outcome as a simple sum of the prognostic indicants, each weighted by a regression coefficient, and a constant term. Maximum likelihood estimates of the regression coefficients associated with each potential prognostic indicant in the model were obtained. The CT score (CTS) indicating the information contained on the CT scan associated with outcome is given by the formula, $CTS = -0.62X_1 + 1.32$, where X_1 is given by $X_1 = 0$ if there are no hemorrhagic lesions; 1 if the lesion is seen on one or two slices; 2 if three or four slices; 3 if five or six slices, and 4 if seven or eight slices. A patient with a CTS of less than zero is predicted to have a poor outcome. Otherwise the patient is predicted to do well. As an example, consider the patient whose CT scan is illustrated in figure 1. A large hemispheric intracerebral hematoma is present on six CT slices. Thus, $X_1 = 3$, and, using the above formula, $CTS = -(0.62 \times 3) + 1.32 = -0.54$. Since $-0.54 < 0$, the patient is predicted to have a poor outcome. This patient was indeed severely disabled.

We also attempted to determine a combined scale using the initial CT findings and the GCS, commonly used in head-trauma centers to

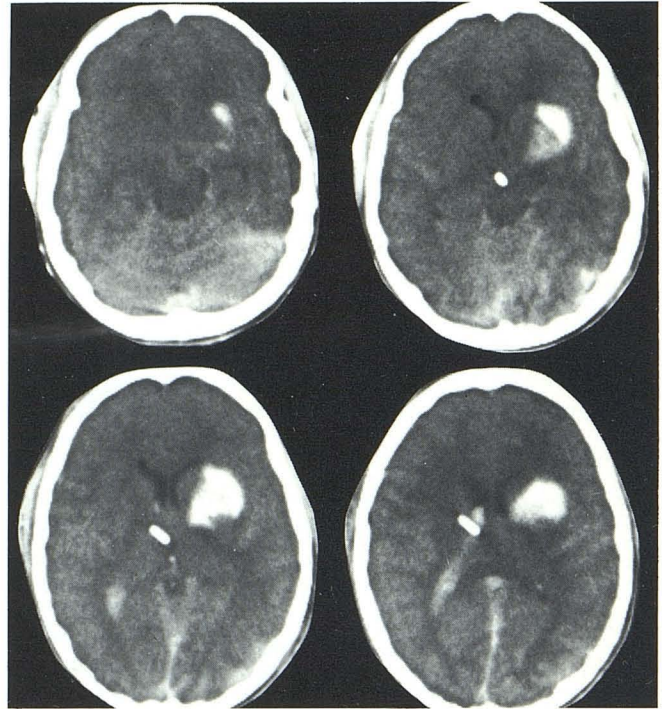


Fig. 2.—Left intracerebral hematoma and intraventricular hemorrhage on four successive CT slices.

assess a patient's status, for determining prognosis. The score associated with this information is given by the formula, $CT-GCS = 0.48 GCS - 0.56X_1 - 1.95$. Patients whose CT-GCS falls below zero are predicted to do poorly. This can be illustrated by the case shown in figure 2, where a left basal ganglion hematoma together with intraventricular hemorrhage is seen on four slices, giving an X_1 of 2. Here $CTS = -(0.62 \times 2) + 1.32 = 0.08$, and the patient is predicted to do well. However, when we consider the patient's GCS, which was 3, and using the CT-GCS formula, we obtain $CT-GCS = (0.48 \times 3) - (0.56 \times 2) - 1.95 = -1.63$. Using this more informative score we predict that the patient will do poorly. Indeed this was proved correct as the patient died shortly after the initial CT study.

Results

In the 128 randomly selected patients with hemorrhagic lesions on initial CT, a clear relation was demonstrated between outcome and the size of the lesions as measured by the number of slices on which hemorrhagic areas are seen, as demonstrated in table 1. The difference in outcomes between patients with normal CT scans and those with lesions present is significant, with 80% of patients with normal CT scans having a good outcome ($p = 0.0001$). An exception to this occurred in patients who developed secondary complications or had undetected brainstem lesions. The only areas where a clear trend was not seen were in those patients with isolated extra- or intraaxial hematomas. In addition, we found that 100% of patients having both intra- and extraaxial hemorrhagic lesions ended up with a poor outcome. Of the seven patients who had bilateral hemorrhagic lesions, four (57%) had a poor outcome; although this is not statistically significant, it has been shown that by including those patients who developed bilateral lesions within the first week after admission, a poor outcome of 75% is found. These findings

TABLE 1: Prognostic Significance of Lesion Size in Head Injury

No. of Scans with Hemorrhagic Lesions	No. of Patients by Final Outcome (%)		Total
	Good	Poor	
None	55 (80)	14 (20)	69
One or two	5 (63)	3 (37)	8
Three or four	12 (50)	12 (50)	24
Five or six	9 (37)	15 (63)	24
Seven or eight	1 (33)	2 (67)	3

Note.—A good outcome is defined as good outcome and moderate disability; a poor outcome is defined as severe disability, vegetative state, and death.

are confirmed by Sweet et al. [17]. Patients with corpus callosum lesions also have a poor outcome: four (80%) of five, as reported by Zimmerman et al. [18]. A similar poor outcome has been documented in patients with brainstem lesions [19]. However, because of the low incidence of brainstem and corpus callosum lesions in our sample, a statistical trend using these factors was not investigated. This also applies to the incidence of intraventricular hemorrhage, which only occurred in 5% of our sample.

By using a CTS of less than zero in predicting a poor outcome, 69.7% of our patients were correctly classified. By including the GCS in the model as previously explained, 75.8% of patients were correctly classified. These rates are expected to be somewhat lower when the rules are used for a prospective study.

Midline shift is another significant prognostic indicant by itself. Table 2 indicates that 64% of the patients with midline shift of greater than or equal to 3.8 mm did poorly ($X_1^2 = 7.46; p = 0.0006$).

Discussion

Despite several attempts to predict the outcome after head injury, our ability to do so has remained elusive. When one discards factors such as age, patients under 20 having a better outcome than the older population [7, 10, 12, 20], the time elapsed between injury and medical care [21], and associated systemic insults that are more likely to result in poor outcomes, the most commonly discussed clinical prognostic indicants are the initial neurologic examination, the depth of coma, and intracranial pressure [6–10, 12, 14, 22, 23]. The GCS is a good indicator [14], but it has its limitations. Nevertheless, as shown in a recent study by Young et al. [24] as well as by others, it is well known that over 95% of the patients with a score of 4 or less are likely to have a poor outcome compared with those with a score of 8 or more. However, a significant number of patients fall in the group between 5 and 7, and in this group the GCS is not very helpful, with 50% of patients having an unpredictable outcome. Intracranial pressure is also considered to be a valuable tool in predicting outcome [22]. Only 25% of patients with normal pressure are likely to have poor outcome, whereas 100% of people with an intracranial pressure of 60 mm Hg or greater are likely to have a poor prognosis. However, many patients have intracranial pressures between these two categories, and it is difficult to predict outcome in these patients lower when the rule is applied prospectively. When a further using intracranial pressure alone. It is also noted that most

TABLE 2: Prognostic Significance of Midline Shift on Outcome in Head Injury

Outcome	No. of Patients by Amount of Midline Shift (%)	
	<3.8 mm	≥3.8 mm
Good	57 (70)	17 (37)
Poor	25 (30)	29 (63)
Total	82	46

patients with normal CT scans have normal intracranial pressures and go on to have a good outcome [22]. If one considers all these variables, including the early CT and clinical findings and late CT changes, one is likely to find better correlation with the outcome, as suggested by Van Dongen and Braakman [25].

Since the various clinical parameters used for prognosis are based on neurologic dysfunction, which apparently results from structural damage to the brain, and since this structural damage is currently best detected by CT, it is only logical for us to investigate the predictive power of CT for the outcome in head-injury patients. In fact, of 230 consecutive patients who were admitted into our head-injury program, 18 had total flaccidity on admission, and as can be expected, 16 of these had a poor outcome with only two making a good recovery. The only correlative factor in these two patients was a normal CT study.

Clear trends of outcome are seen in patients with certain CT findings. Patients who have a normal CT scan on admission do well, with 80% of them having a good outcome [22]. The exceptions are patients who develop secondary complications such as hydrocephalus [26] or who have undetected brainstem lesions [19]. Another group where a clear trend is seen are patients who have both intra- and extraparenchymal lesions on CT; 67% of these patients have a poor outcome [22]. A clear trend is also seen in patients with bilateral hemorrhagic lesions; 75% of them end up in a persistent vegetative state or death [17]. Also well documented in the literature is the group of patients who suffer midline lesions. Corpus callosum and brainstem lesions are also known to portend a poor outcome [18, 19].

Therefore, we attempted to devise a scale in which the size of the hemorrhagic lesions on CT could be used statistically to indicate prognosis. The number of slices on which a hemorrhagic lesion is seen on CT is used to devise a statistical model. In this particular study we used a linear logistic regression model. The logistic model has been shown to be effective in predicting outcome in severe head injury [12, 15]. Its interpretability is easily manifest, since the model related a simple sum of each CT factor multiplied by a weight, known as a regression coefficient, to the relative odds of having a poor outcome. Thus, a simple scoring procedure may be developed for predicting outcome from CT indicants. The score is easily computed, and prediction may be obtained by observing whether or not the score is greater than or less than zero. A patient with a CTS of less than zero was predicted to have a poor outcome. When this rule was applied retrospectively to our series of 128 patients, 69.7% were correctly classified, although this rate is likely to be slightly breakdown of the number of slices in which a hemorrhagic lesion was present was performed as indicated in table 1, it

can be seen that 80% of the patients with no hemorrhagic lesion had a good outcome, with the other 20% showing a poor outcome. As the number of slices on which a hemorrhagic lesion is seen increases, a corresponding decrease in the number of good outcomes and increase in the poor outcomes is seen. When the lesion was demonstrated on seven or eight slices, two-thirds of the patients suffered a poor outcome. We decided not to use other factors such as bilateral, midline, and brainstem lesions, because, although these were found to have a profound effect on outcome, too few were present in our series to convey any statistical significance. The extent of midline shift did not add significantly to the prognostic capability of our model, although as demonstrated in table 2, midline shift by itself proved a good prognostic indicant, with 63% of patients with midline shift of greater than or equal to 3.8 mm having a poor prognosis.

Edema was not included in our study because of difficulties in interpretation. Diffuse edema may be difficult to diagnose, as no area of normal brain may be available for comparison. In these cases one may see decrease in size of the ventricular system. However, this may also be the result of increased cerebral blood volume as a response to trauma. In addition, not all low-density areas seen on CT represent edema. Tentorial herniation was not considered, again because it was not easily identifiable in all cases, and it was therefore believed that its inclusion would complicate the scale.

We further attempted to increase the prognostic value of the initial CT scan by combining it statistically with the GCS score, commonly used in head-trauma centers to assess patient status. The resultant score computed from our data was expressed as the CT-GCS. Patients whose CT-GCS fell below zero were predicted to do poorly, and 75.8% of patients were found to be correctly classified by this method. This result is especially significant when one considers the instances in which a low GCS score may actually give a pessimistic outlook by itself, even though CT showed that actual brain damage was minimal. It is in these cases that the size of the lesions gives valuable additional information for prognostic purposes.

REFERENCES

1. Auer L, Gell G, Richling B, Oberbauer R. Predicting outcome after severe head injury—a computer assisted analysis of neurological symptoms and laboratory values. *Acta Neurochir [Suppl] (Wien)* **1979**;28:171–173
2. Braakman R, Gelpke GJ, Habbema JDF, Maas AIR, Minderhoud JM. Systematic selection of prognostic features in patients with severe head injury. *Neurosurgery* **1980**;6:362–370
3. Cooper PR, Maravilla V, Moody S, Clark WK. Serial computerized tomographic scanning and the prognosis of severe head injury. *Neurosurgery* **1979**;5:566–569
4. Greenberg RP, Newlon PG, Hyatt MS, Narayan RK, Becker DP. Prognostic implications of early multimodality evoked potentials in severe head-injured patients: a prospective study. *J Neurosurg* **1981**;55:227–236
5. Habbema JDF, Braakman R, Avezaat CJJ. Prognosis of the individual patient with severe head injury. *Acta Neurochir [Suppl] (Wien)* **1979**;28:158–160
6. Jennett B, Teasdale G, Braakman R, Minderhoud J, Heiden J, Kurze T. Prognosis of patients with severe head injury. *Neurosurgery* **1979**;4:283–289
7. Jennett B, Teasdale G, Braakman R, Minderhoud J, Knill-Jones R. Predicting outcome in individual patients after severe head injury. *Lancet* **1976**;1:1031–1034
8. Knoblich OE, Gaab M. Prognostic information from EEG and ICP monitoring after severe closed head injuries in the early post-traumatic phase. *Acta Neurochir [Suppl] (Wien)* **1979**;28:58–62
9. Lobato RD, Rivas JJ, Portillo JM, et al. Prognostic value of the intracranial pressure during the acute phase of severe head injuries. *Acta Neurochir [Suppl] (Wien)* **1979**;28:70–73
10. Overgaard J, Hvid-Hansen O, Land AM, et al. Prognosis after head injury based on early clinical examination. *Lancet* **1973**;2:631–635
11. Teasdale G, Parker L, Murray G, Knill-Jones R, Jennett B. Predicting the outcome of individual patients in the first week after severe head injury. *Acta Neurochir [Suppl] (Wien)* **1979**;28:161–164
12. Narayan RK, Greenberg RP, Miller JD, et al. Improved confidence of outcome prediction in severe head injury. A comparative analysis of the clinical examination, multi-modality evoked potentials, CT scanning, and intracranial pressure. *J Neurosurg* **1981**;54:751–762
13. Jennett B, Bond M. Assessment of outcome after severe brain damage. A practical scale. *Lancet* **1974**;2:480–484
14. Teasdale G, Jennett B. Assessment of coma and impaired consciousness. A practical scale. *Lancet* **1974**;2:81–84
15. Stablein DM, Miller JD, Choi SC, Becker DP. Statistical methods for determining prognosis in severe head injury. *Neurosurgery* **1980**;6:243–248
16. Press SJ, Wilson S. Choosing between logistic regressions and discriminant analysis. *J Am Stat Assoc* **1978**;73:699–705
17. Sweet RC, Miller JD, Lipper MH, Kishore PRS, Becker DP. The significance of bilateral abnormalities on the CT scan in patients with severe head injury. *Neurosurgery* **1978**;3:16–21
18. Zimmerman RA, Bilaniuk LT, Gennarelli T. Computed tomography of shearing injuries of the cerebral white matter. *Radiology* **1978**;127:393–396
19. Tsai FY, Heal JS, Itabashi HH, Huprich JE, Hieshima GB, Sæggal HD. Computed tomography of posterior fossa trauma. *J Comput Assist Tomogr* **1980**;4:291–305
20. Teasdale G, Skene A, Parker L, Jennett B. Age and outcome of severe head injury. *Acta Neurochir [Suppl] (Wien)* **1979**;28:140–143
21. Seelig JM, Becker DP, Miller JD, Greenberg RP, Ward JD, Choi SC. Traumatic acute subdural hematoma: major mortality reduction in comatose patients treated within four hours. *N Engl J Med* **1981**;304:1511–1518
22. Kishore PRS, Lipper MH, Becker DP, Domingues da Silva AA, Narayan RK. Significance of CT in head injury: correlation with intracranial pressure. *AJNR* **1981**;2:307–311, *AJR* **1981**;137:829–833
23. Miller JD, Gudeman SK, Kishore PRS, Becker DP. CT scan, ICP and early neurological evaluation in the prognosis of severe head injury. *Acta Neurochir [Suppl] (Wien)* **1979**;28:86–88
24. Young B, Rapp RP, Norton JA, Haack D, Tibbs PA, Bean JR. Early prediction of outcome in head-injured patient. *J Neurosurg* **1981**;54:300–303
25. Van Dongen KJ, Braakman R. Late computed tomography in survivors of severe head injury. *Neurosurgery* **1980**;7:14–22
26. Gudeman SK, Kishore PRS, Becker DP, et al. Computerized tomography in the evaluation of incidence and significance of post-traumatic hydrocephalus. *Radiology* **1981**;141:397–402