

Are your **MRI contrast agents** cost-effective?

Learn more about generic **Gadolinium-Based Contrast Agents**.



FRESENIUS
KABI

caring for life

AJNR

Chronic seizure disorders: contribution of MR imaging when CT is normal.

D W Laster, J K Penry, D M Moody, M R Ball, R L Witcofski and
A R Riela

AJNR Am J Neuroradiol 1985, 6 (2) 177-180

<http://www.ajnr.org/content/6/2/177>

This information is current as
of April 20, 2024.

Chronic Seizure Disorders: Contribution of MR Imaging When CT Is Normal

D. Wayne Laster¹
J. Kiffin Penry²
Dixon M. Moody¹
Marshall R. Ball¹
Richard L. Witcofski¹
Anthony R. Riela²

One hundred consecutive patients with complex partial seizures were studied by magnetic resonance (MR) imaging and computed tomography (CT). Thirty-four patients had seizures of more than 5 years' duration, yet neurologic examinations and previous pre- and postinfusion CT scans had been normal. MR imaging demonstrated surgical lesions of potentially therapeutic significance in four of these 34 patients. Two patients underwent surgery with removal of a thrombosed arteriovenous malformation and a glioma. Although CT has been found to detect structural abnormalities, its yield of therapeutically significant abnormalities has been low.

Over the past decade computed tomography (CT) has been the imaging method of choice in the evaluation of patients with signs and symptoms of intracranial pathology. Recent developments in proton magnetic resonance (MR) imaging have rapidly led to its preeminence over CT in the detection of cerebral abnormalities [1, 2]. MR imaging has been shown to detect more lesions in demyelinating disease than does CT, and its ability to detect primary brain tumors appears to rival CT [3-7]. A potential important application of MR imaging may lie in the study of patients with seizure disorders. The CT detection of structural brain abnormalities of surgical therapeutic significance in chronic (>5 years) cryptogenic seizures is around 1% [8]. We investigated the potential of MR imaging in patients with chronic complex partial seizures, normal neurologic examinations, and normal CT. Our results are reported.

Subjects and Methods

Studies were performed on an MR resistive magnet imager manufactured by Picker International operating at a frequency of 6.4 MHz with a magnetic field of 0.15 T (1500 G). MR images in the transverse, sagittal, and coronal planes were obtained using inversion-recovery (IR) and spin-echo (SE) pulse sequences. Initially, patients were studied using single-section image acquisition, and the rest were studied with either four, eight, or 16 contiguous multislices. Slice thickness was 1 cm in all cases. Images were generated by filtered back-projection or two-dimensional Fourier transform on a 256 × 256 matrix.

MR studies were performed in 35 patients with complex partial seizure disorders of greater than 5 years' duration. All patients had normal neurologic examinations. Previous normal pre- and postinfusion CT scans were available; however, a repeat examination was performed within 1 month of the abnormal MR study.

Results

Four (11.7%) of 34 patients were shown by MR studies to have lesions in various parts of the temporal lobe. Histologic confirmation of two lesions revealed a thrombosed arteriovenous malformation (AVM) and a glioma. Surgery was contemplated in the other two patients. Details of the four patients with abnormal MR are described.

Received July 18, 1984; accepted after revision November 5, 1984.

A. R. Riela is a Neurology fellow.

Presented at the annual meeting of the American Society of Neuroradiology, Boston, June 1984.

¹Department of Radiology, Bowman Gray School of Medicine, Wake Forest University, 300 S. Hawthorne Rd., Winston-Salem, NC 27103. Address reprint requests to D. W. Laster.

²Department of Neurology, Bowman Gray School of Medicine, Wake Forest University, Winston-Salem, NC 27103.

AJNR 6:177-180, March/April 1985
0195-6108/85/0602-0177

© American Roentgen Ray Society

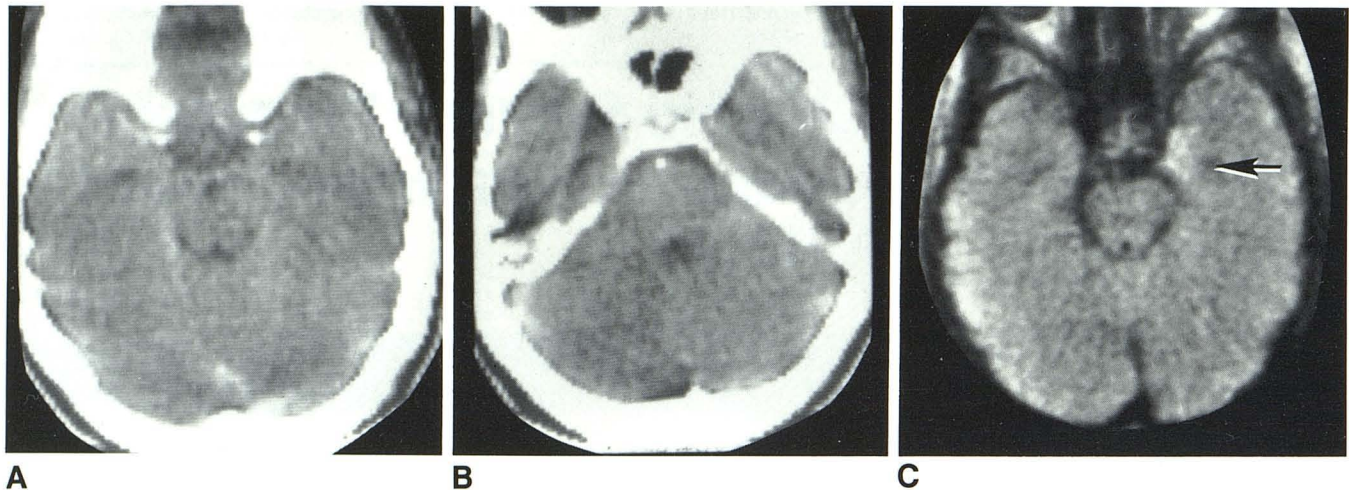


Fig. 1.—Case 1. **A** and **B**, Contiguous 8-mm-thick postinfusion CT scans. Absence of temporal lobe abnormality. **C**, SE 1080/80 image. Slightly dilated temporal horn (arrow) and area of high signal intensity in uncus medially.

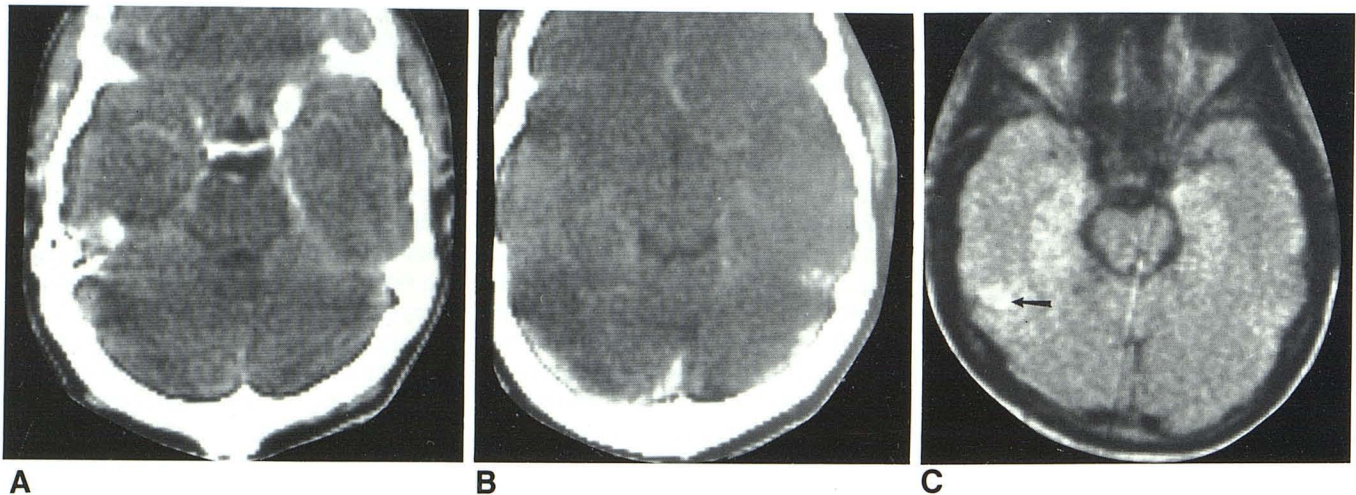


Fig. 2.—Case 2. **A**, Contiguous 8-mm-thick normal postinfusion CT scans. **B**, SE 1080/80 image. Abnormal high signal in right posterior middle temporal gyrus (arrow).

Case Reports

Case 1

A 16-year-old right-handed girl had experienced febrile seizures since age 3 months and poorly controlled general clonic-tonic seizures since age 3 years. Electroencephalography (EEG) demonstrated generalized slow waves with multifocal sharp spikes. Recent deep electrode studies at another institution to determine the possibility of surgery were inconclusive. Pre- and postinfusion CT scans were normal (figs. 1A and 1B). MR using an SE pulse sequence with a repetition time (TR) of 1080 msec and an echo time (TE) of 80 msec (SE 1080/80) demonstrated an area of high signal intensity in the medial left temporal lobe (fig. 1C). Faint visualization of the temporal horn was seen and no mass effect was present. The location of this abnormality in the medial aspect of the temporal tip is compatible with mesial temporal sclerosis, the most common abnormality (50%–60%) found in patients undergoing surgery for chronic temporal epilepsy [9]. Temporal lobectomy was contemplated pending seizure control.

Case 2

A 30-year-old right-handed man had a 10 year history of poorly controlled complex partial seizures. Pre- and postinfusion CT scans were normal (figs. 2A and 2B). EEG demonstrated right inferior frontal and temporal spike waves. An SE 1080/80 pulse sequence demonstrated an irregularly shaped focal lesion of high signal intensity in the right lateral aspect of the middle temporal gyrus (fig. 2C). A thrombosed AVM was removed at surgery.

Case 3

An 18-year-old right-handed woman had a 5 year history of complex partial seizures. EEG demonstrated frequent epileptic discharges from the left temporal region. Pre- and postinfusion CT scans were normal (figs. 3A–3D). An IR 1400/400 image demonstrated a comma-shaped lesion of low signal intensity in the medial left temporal lobe (fig. 3E). Abnormal high signal intensity was present on the multislice SE sequence using 80 msec TEs and 4000 msec TRs (fig. 3F). Surgery was contemplated with glioma and hamartoma being diagnostic considerations.

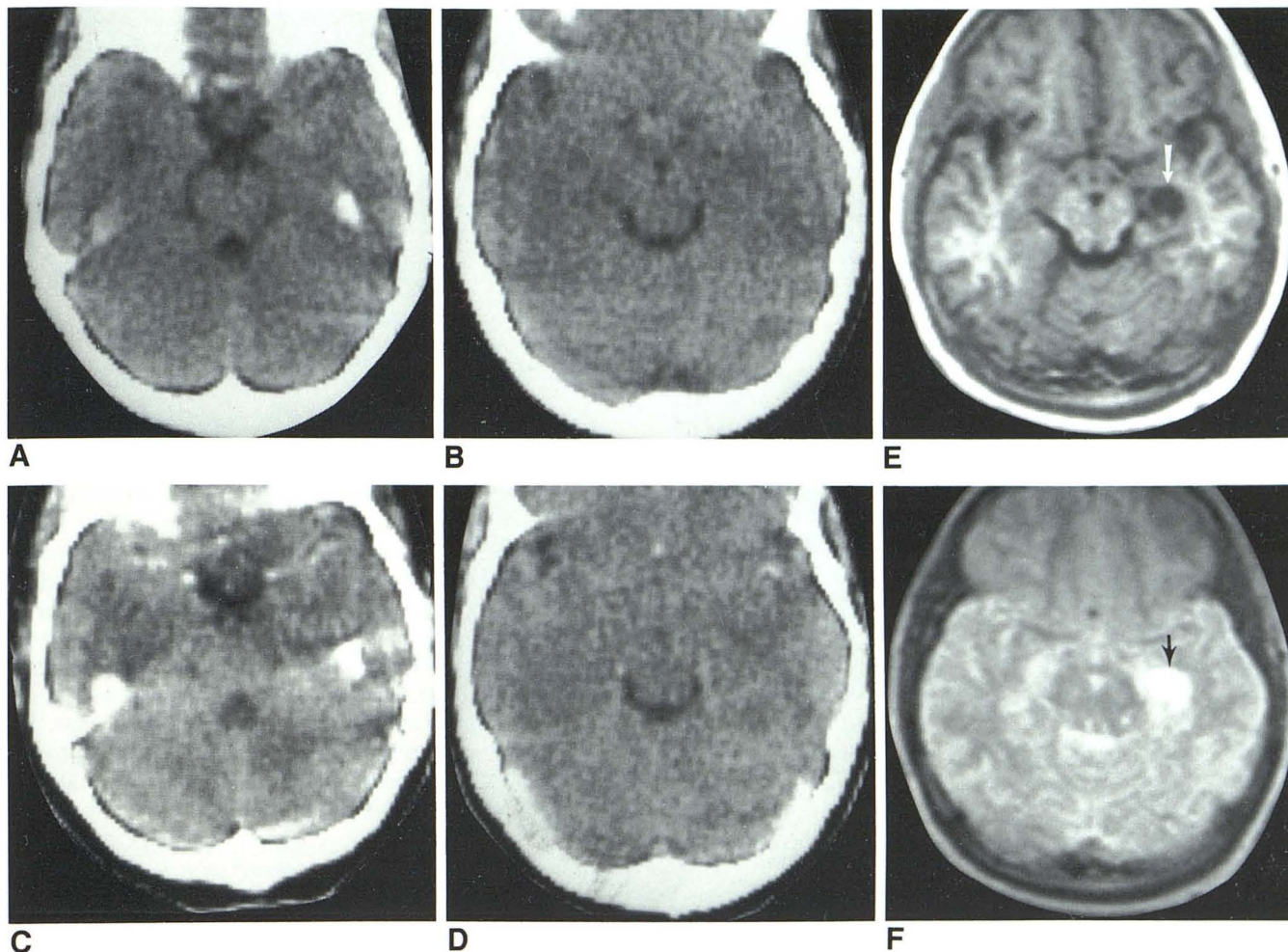


Fig. 3.—Case 3. **A** and **B**, Contiguous 8-mm-thick normal unfused CT scans. **C** and **D**, Normal postinfusion CT scans. **E**, IR 1400/400 image. Comma-shaped lesion of low signal intensity in left medial temporal lobe (*arrow*). **F**, SE 4000/80 image. Abnormal comma-shaped area of high signal intensity in medial temporal lobe (*arrow*).

Case 4

A 9-year-old right-handed boy had had complex partial seizures since age 4. Physical examination was normal and EEG demonstrated bitemporal spikes. Multiple previous unfused and infused CT scans were normal as was a recent scan (figs. 4A–4C). MR demonstrated an area of abnormal high signal intensity in the right medial hippocampus on multislice axial and coronal SE 3000/80 images (figs. 4D and 4E). An astrocytoma was removed at surgery.

Discussion

In 1976, Bachman et al. [10] reported on CT scanning in children with chronic seizure disorders. Structural abnormalities were identified in 30% of the cases, however, only 2% of the abnormalities were significant therapeutically. Their research emphasized the role of normal CT scans in ruling out progressive disease. Others subsequently discussed the usefulness of CT scanning in the investigation of seizure disorders of varying duration, time of onset, and etiology [11–14].

Jabbari et al. [15] noted that CT scans revealed only four (2.8%) surgically correctable lesions in 143 chronic epileptics in whom invasive neuroradiologic studies did not justify surgery. Gilsanz et al. [16] likewise found that CT revealed intracranial mass lesions in 2.4% of their patients with normal neurologic findings while suffering from presumed cryptogenic epilepsy. One case of histologically proven mesial temporal sclerosis that manifested as an arcuate, nonenhancing calcification on CT was reported by Jabbari et al. [17] in 1979. In general, surgically correctable lesions were not detected by CT in patients with a long duration of seizures (>5 years) or an absence of neurologic signs or symptoms [8].

Our study suggests that MR should be the imaging method of choice in cases of chronic and presumed cryptogenic epilepsy. These results point to a tremendous potential for the use of MR in evaluating chronic seizure disorders. The detection of surgically correctable abnormalities by MR imaging in the presence of normal CT scans may herald a new era in seizure management.

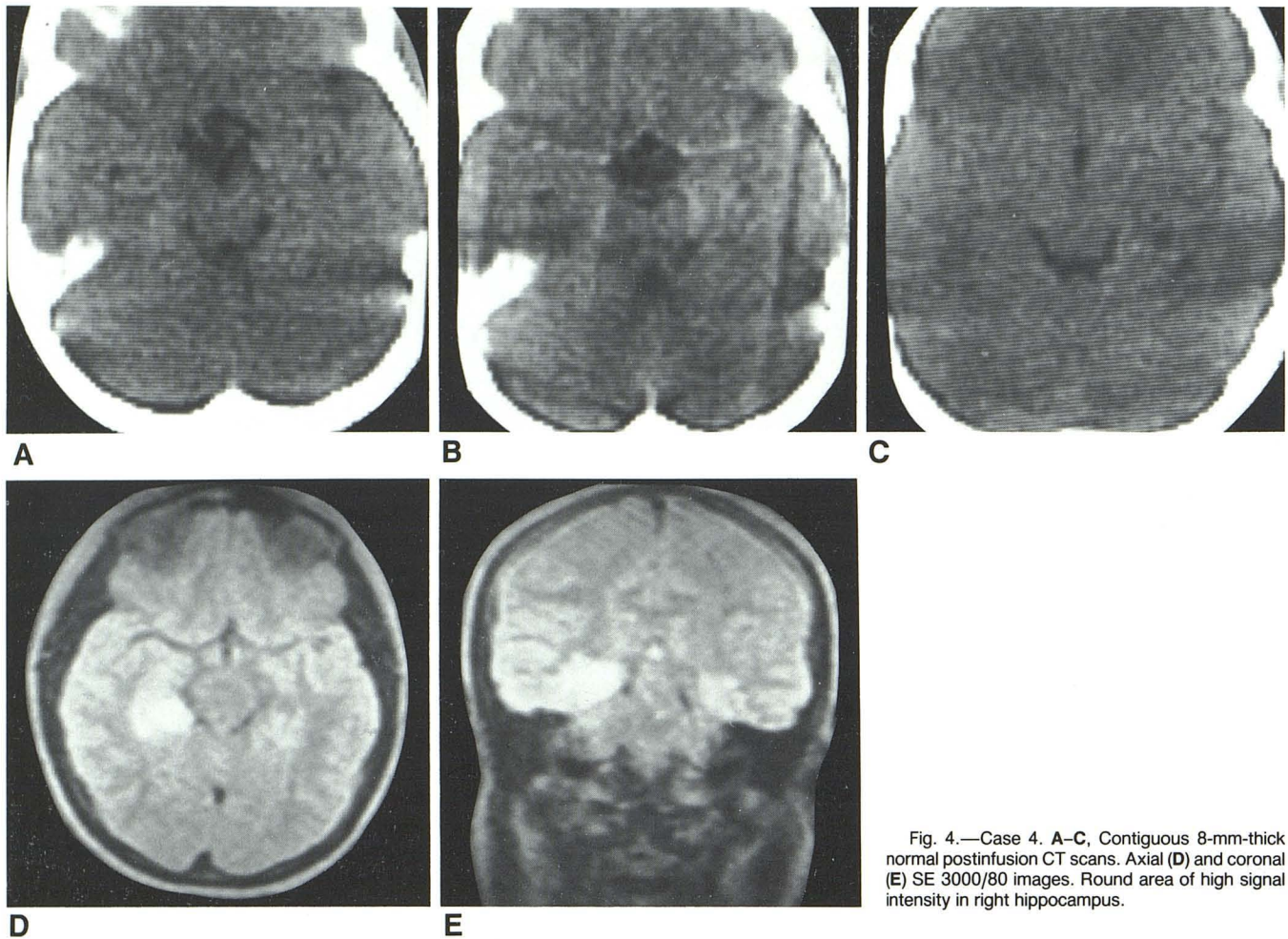


Fig. 4.—Case 4. A–C, Contiguous 8-mm-thick normal postinfusion CT scans. Axial (D) and coronal (E) SE 3000/80 images. Round area of high signal intensity in right hippocampus.

REFERENCES

1. Brant-Zawadzki MB, Davis PL, Crooks LE, et al. NMR demonstration of cerebral abnormalities: comparison with CT. *AJNR* **1983**;4:117–124, *AJR* **1983**;140:847–854
2. Zimmerman RA, Bilaniuk LT, Goldberg HI, et al. Cerebral NMR imaging: early results with a 0.12 T resistive system. *AJNR* **1984**;5:1–7, *AJR* **1983**;141:1187–1193
3. Young IR, Randell CP, Kaplan PW, James A, Bydder GM, Steiner RE. Nuclear magnetic resonance (NMR) imaging in white matter disease of the brain using spin-echo sequences. *J Comput Assist Tomogr* **1983**;7:290–294
4. Johnson MA, Penneck JM, Bydder GM, et al. Clinical NMR imaging of the brain in children: normal and neurologic disease. *AJNR* **1983**;4:1013–1026, *AJR* **1983**;141:1005–1018
5. Levene MI, Whitelaw A, Dubowitz V, et al. Nuclear magnetic resonance imaging of the brain in children. *Br J Med* **1982**;285:774–776
6. Randell CP, Collins AG, Young IR, et al. Nuclear magnetic resonance imaging of posterior fossa tumors. *AJNR* **1983**;4:1027–1034, *AJR* **1983**;141:489–496
7. vonEinsiedel GH, Löffler W. Nuclear magnetic resonance imaging of brain tumours unrevealed by CT. *Eur J Radiol* **1982**;2:226–234
8. McGahan JP, Dublin AB, Hill RP. The evaluation of seizure disorders by computerized tomography. *J Neurosurg* **1979**;50:328–332
9. Falconer MA, Taylor DC. Surgical treatment of drug-resistant epilepsy due to mesial temporal sclerosis. *Arch Neurol* **1968**;19:353–361
10. Bachman DS, Hodges FJ III, Freeman JM. Computerized axial tomography in chronic seizure disorders of childhood. *Pediatrics* **1976**;58:828–832
11. Scollo-Lavizzari G, Eichorn K, Wüthrich R. Computerized transverse axial tomography (CTAT) in the diagnosis of epilepsy. *Eur Neurol* **1977**;15:5–8
12. Bauer G, Mayr U, Pallua A. Computerized axial tomography in chronic partial epilepsies. *Epilepsia* **1980**;21:227–233
13. Gastaut H, Gastaut JL. Computerized transverse axial tomography in epilepsy. *Epilepsia* **1976**;17:325–336
14. Bogdanoff BM, Stafford CR, Green L, Gonzalez CF. Computerized transaxial tomography in the evaluation of patients with focal epilepsy. *Neurology (NY)* **1975**;25:1013–1017
15. Jabbari B, Huott AD, Di Chiro G, Martins AN, Coker SB. Surgically correctable lesions detected by CT in 143 patients with chronic epilepsy. *Surg Neurol* **1978**;10:319–322
16. Gilsanz V, Strand R, Barnes P, Nealis J. Results of presumed cryptogenic epilepsy in childhood by CT scanning. *Ann Radiol (Paris)* **1979**;22:184–187
17. Jabbari B, Di Chiro G, McCarty JP. Mesial temporal sclerosis detected by computed tomography. *J Comput Assist Tomogr* **1979**;3:527–529