

Computed Tomography in Preeclampsia-Eclampsia Syndrome

Robert L. Waldron II,¹ Don C. Abbott,² and Devi Vellody³

Excellent postmortem clinicopathologic studies of eclampsia have been published [1-4]. However, only a few antemortem studies using computed tomographic (CT) evaluation have been reported [5-7]. We present the CT findings in preeclampsia and eclampsia.

Case Reports

Case 1

A 19-year-old primigravida delivered a normal full-term infant. She had been hypertensive during the latter stages of pregnancy. She developed cortical blindness, headache, and proteinuria. On physical examination, blood pressure was 170-180/100. The fundi were not well seen, vision was limited to light perception, and the pupils were equal and reactive to light. No sensory or motor deficit was noted. Deep tendon reflexes were normal. A CT scan of the head was obtained (fig. 1A). A diagnosis of preeclampsia with cortical blindness was made and the patient was treated appropriately. Vision improved to 20/20 within 48 hr. At follow-up examination 2 weeks later, she was normotensive without antihypertensive medication. Repeat CT at 5 weeks (fig. 1B) was normal.

Case 2

A 20-year-old gravida 2, primipara presented 4 weeks before her estimated date of confinement with a history of several hours of posterior headache and visual disturbance. Twenty-four hours after admission, visual disturbance persisted and vision was limited to light perception. Blood pressure was 120-130/90-100. The patient's blood pressure continued to be slightly elevated immediately after delivery; about 2½ hr after delivery, the patient had a grand mal seizure followed by respiratory arrest. Resuscitation was successful. Urinalysis showed proteinuria. A CT scan of the head was obtained (figs. 2A-2C). A diagnosis of eclampsia was made and she was treated appropriately, with rapid clinical improvement occurring over the next 24 hr. A follow-up CT scan obtained 3 weeks later was normal (figs. 2D-2F).

Discussion

On the basis of autopsy findings, Sheehan and Lynch [4] classified cerebral vascular lesions of toxemia of pregnancy into five major groups: (1) patches of petechial hemorrhage

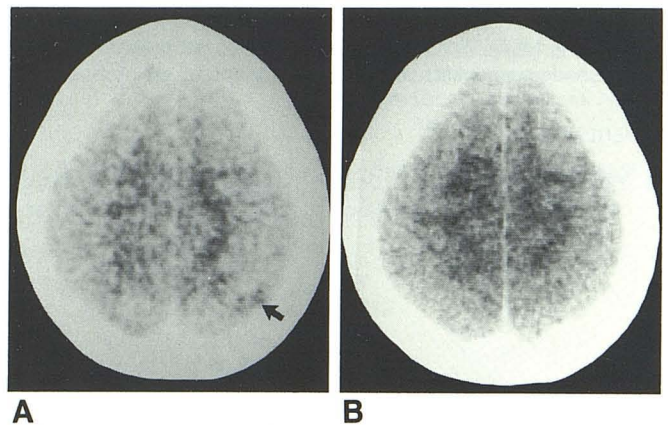


Fig. 1.—Case 1: Preeclampsia. **A**, Initial CT scan. High parietal, cortical low-density zone in superior parietal lobule on left (*arrow*). This lesion did not enhance. There were other, smaller low-density foci on left side in a more rostral cut. No CT abnormality was discernible in regions of visual pathways or visual cortex, however. **B**, Same level as **A**, 5 weeks later. Low-density zone in superior parietal lobule has reverted to normal, as did the more rostral abnormalities.

in the cerebral cortex; (2) multiple small areas of ischemic softening scattered throughout the brain (usually not hemorrhagic); (3) small areas of hemorrhage into the subcortical white matter, usually localized to the upper part of the hemisphere; (4) a single large hemorrhage in the white matter; and (5) hemorrhage in the basal ganglia or pons, often with rupture into the lateral ventricles. Gaitz and Bamford [7] have reported a case similar to our two cases, involving multiple areas of decreased density that reverted to normal on follow-up examination at 10 days. These findings were believed to be due to reversible ischemic lesions and, thus, would correspond to Sheehan and Lynch's group 2 findings at autopsy [4]. In our case 1, multiple gray-matter low-density foci had reverted to normal in 5 weeks. In our case 2, multiple gray- and white-matter low-density foci had reverted to normal at follow-up 3 weeks later. In both cases, the findings were believed to represent reversible ischemic lesions.

Received November 2, 1983; accepted after revision January 18, 1984.

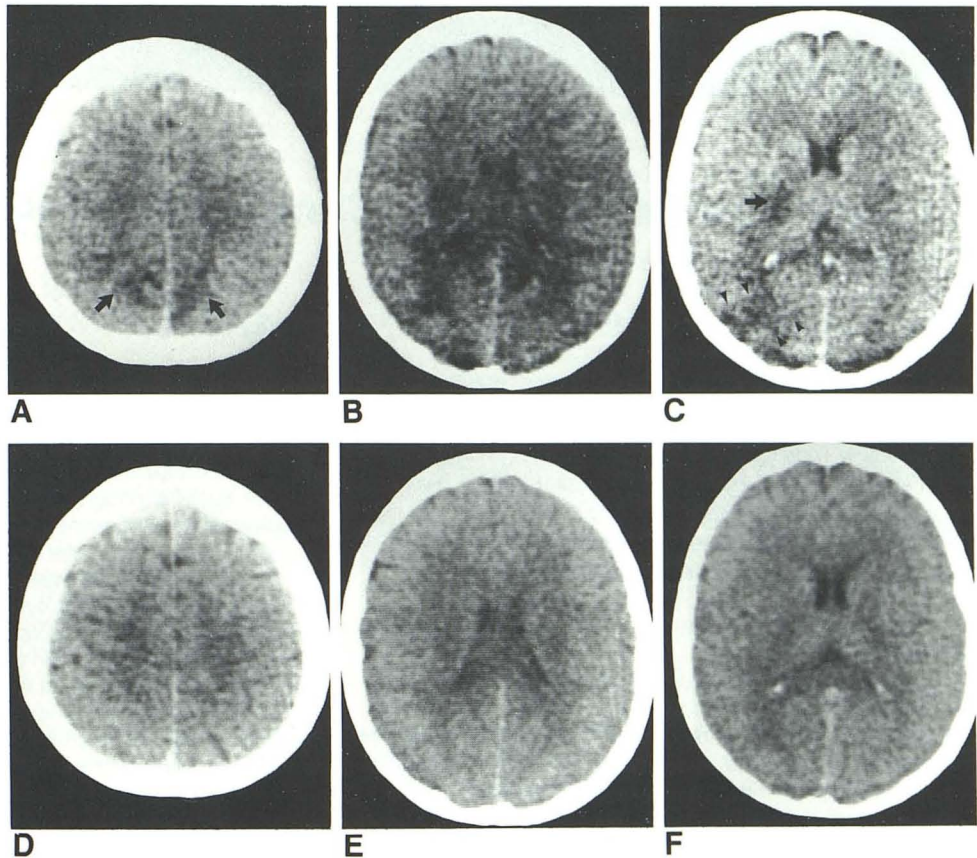
Presented at the annual meeting of the Southeastern Neuroradiological Society, Point Clear, AL, September 1983.

¹ Department of Radiology, Richland Memorial Hospital, 3301 Harden St., Columbia, SC 29203. Address reprint requests to R. L. Waldron.

² Department of Neurology, Richland Memorial Hospital, Columbia, SC 29203.

³ Department of Internal Medicine, Moncreif Army Hospital, Fort Jackson, SC 29207.

Fig. 2.—Case 2: Eclampsia. A–C, Initial CT scan. A, High parietal low-density areas in precuneus bilaterally, involving cortex and adjacent white matter (arrows). B, Bilateral low-density areas in corona radiata and optic radiations, greater on right. C, Low-density focus in right internal capsule (arrow) and right occipital lobe, involving cortex and adjacent white matter (arrowheads). None of the lesions in A–C showed enhancement. D–F, Same levels as A–C, respectively, 3 weeks later. All low-density lesions have reverted to normal.



In our patient with preeclampsia (case 1), the CT findings were more subtle than, but similar to, those in our patient with eclampsia; abnormalities in both cases resolved. Our cases demonstrate that both the clinical and the CT findings can revert to normal in preeclampsia and eclampsia. In the case of Gaitz and Bamford's patient [7], the CT findings returned to normal, but the patient was left with considerable neurologic deficit.

REFERENCES

1. Chapman K, Karini R. A case of post-mortem eclampsia of late onset confirmed by autopsy. *Am J Obstet Gynecol* 1973; 117:858-861
2. Jewett JF. Fatal intracranial edema from eclampsia. *N Engl J Med* 1973;289:276-277
3. Parks J, Pearson JW. Cerebral complications occurring in the toxemia of pregnancy. *Am J Obstet Gynecol* 1943;45:774-785
4. Sheehan HL, Lynch JB. Cerebral lesions. In: Sheehan HL, ed. *Pathology of toxemia of pregnancy*. Baltimore: Williams & Wilkins, 1973:524-584
5. Baker DA, Catalano P, Makowski P, Gibson M. Value of computed tomography (CT) in an obstetrical emergency. *Diagn Gynecol Obstet* 1982;4:53-56
6. Beck DW, Menezes HA. Intracerebral hemorrhage in a patient with eclampsia. *JAMA* 1981;246:1442-1443
7. Gaitz JP, Bamford CR. Unusual computed tomographic scan in eclampsia. *Arch Neurol* 1982;39:66