

Are your **MRI contrast agents** cost-effective?

Learn more about generic **Gadolinium-Based Contrast Agents**.



FRESENIUS
KABI

caring for life

AJNR

CT findings in adult Reye syndrome.

J A Ruskin and V M Houghton

AJNR Am J Neuroradiol 1985, 6 (3) 446-447

<http://www.ajnr.org/content/6/3/446.citation>

This information is current as
of April 19, 2024.

CT Findings in Adult Reye Syndrome

James A. Ruskin¹ and Victor M. Haughton¹

Reye syndrome, a condition of unknown etiology, is characterized by encephalopathy and fatty infiltration of the liver after viral infections, notably influenza B and varicella [1]. A history of relatively large doses of aspirin ingested during the infection is usually elicited [2]. Reye syndrome is seen most often in children ages 6 months to 15 years; the computed tomographic (CT) findings in childhood Reye syndrome have been described. Ten cases have been documented in adults, but no CT abnormalities have been described.

Case Report

A 35-year-old man with a history of chronic headaches and aspirin ingestion of up to eight tablets a day was otherwise in good health until 5 days before admission. At that time he had symptoms of viral gastroenteritis, which progressed to severe emesis and increasing obtundation. He was seen initially at a community hospital, where he was examined, intubated, and transferred to Froedtert Memorial Lutheran Hospital. Physical examination revealed a temperature of 39.4°C, blood pressure of 125/90 mm Hg, and regular pulse of 135 beats/min. The patient was comatose and breathing with the aid of a respirator. He was in decerebrate posture and was unresponsive to pain. Hepatomegaly was present. The physical examination was otherwise negative. Initial hemoglobin and hematocrit were 17.8 g/dl and 52%, respectively. White blood cell count was 11,700/mm³ with no shift. Electrolytes were as follows: sodium, 146 mEq/L; potassium, 2.6 mEq/L; chloride, 103 mEq/L; bicarbonates, 26 mEq/L; glucose, 147 mEq/L; BUN, 21 mg/dl; and creatinine, 1.2 mg/dl. Liver function tests were abnormal with an SGPT of 810 IU/L, SGOT of 489 IU/L, and ammonia of 192 µg/dl. He had a salicylate level of 20 mg/dl. On cannulation of the subarachnoid space by lumbar puncture, the opening pressure was 17 cm of H₂O, and the cerebrospinal fluid cell count was 2 lymphocytes/mm³. The glucose and protein were within normal limits; the VDRL and cultures were negative. A liver biopsy showed microvesicular changes confirming the diagnosis of Reye syndrome.

The patient had persistent fevers up to 41.7°C and seizures; renal failure developed. He remained in a coma and responded only to deep pain. CT 1 day after admission demonstrated diffuse cerebral edema with compression of the ventricles and loss of gray-/white-matter differentiation (fig. 1A). The patient received exchange transfusions and osmotic agents. Three days later, with his condition unchanged, CT demonstrated dilated ventricles and slightly greater

gray-/white-matter differentiation than previously (fig. 1B). A third CT scan on hospital day 6 showed decreased dilatation of the ventricles and more normal gray/white differentiation (fig. 1C). Additional CT scans 2 and 3 weeks after admission showed diminishing density of white matter and progressive ventricular enlargement compatible with leukoencephalopathy (fig. 1D). After 4 weeks in the hospital he was weaned from the respirator but remained unresponsive except to painful stimuli.

Discussion

In our case of Reye syndrome, CT initially showed cerebral edema with loss of gray/white differentiation, developing subsequently into a pattern of leukoencephalopathy, with dilated ventricles and a marked increase in gray-/white-matter differentiation. CT findings in childhood Reye syndrome are similar. Diffuse cerebral edema with compression of the ventricles is seen acutely, although without a decrease in gray-/white-matter differentiation. In children with severe disease, residual changes of frontal and temporal gray- and white-matter low density and marked ventricular dilatation develop similar to the pattern of leukoencephalopathy seen in our case [3].

Of the nine previously reported cases of adult Reye syndrome, only two had CT scans; both were reported as normal [4, 5]. The normal findings in previous cases of adult Reye syndrome may be due to the timing of the scan. Our case showed a nearly normal CT appearance of the brain on hospital day 6. The normal findings may also have been related to less severe disease.

Cerebral edema has a number of possible etiologies including anoxia, severe trauma, drug reactions, and encephalitis. No other cause of edema was obvious in our case. Since the CT findings resembled those in childhood Reye syndrome and the liver biopsy was positive, the most probable etiology was Reye syndrome.

The differential diagnosis of a leukoencephalopathic pattern on CT includes adrenoleukoencephalopathy, multiple sclerosis, progressive multifocal leukoencephalopathy, and anoxic encephalopathy [6]. A preexisting leukoencephalopathy in our previously asymptomatic patient without a significant family history was unlikely.

Received December 7, 1983; accepted February 6, 1984.

¹ Department of Radiology, Medical College of Wisconsin, Froedtert Memorial Lutheran Hospital, 9200 W. Wisconsin Ave., Milwaukee, WI 53226. Address reprint requests to V. M. Haughton.

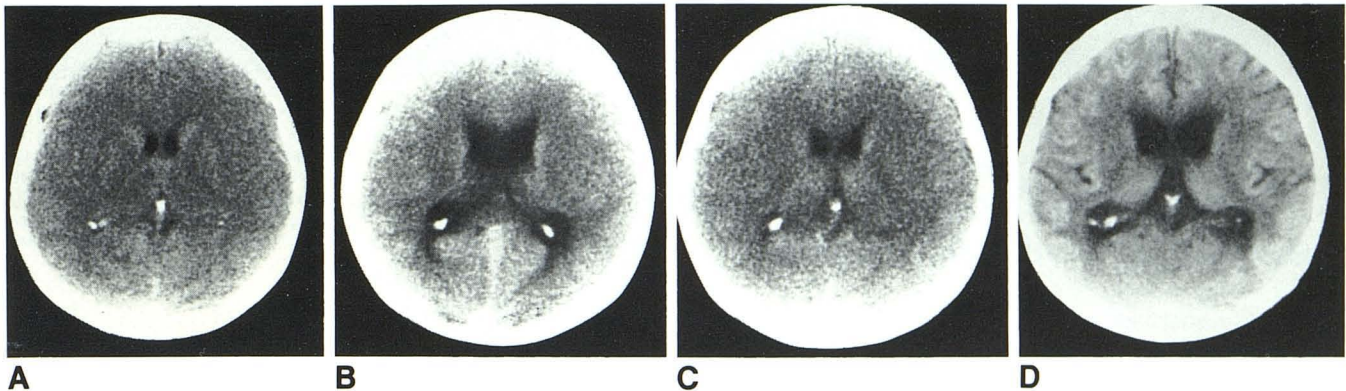


Fig. 1.—Progressive changes in adult Reye syndrome on unenhanced CT scans. **A**, Initial study. Diffuse cerebral edema with compression of ventricles and loss of gray-/white-matter differentiation. **B**, Day 3. Dilated ventricles and

increased gray-/white-matter differentiation. **C**, Day 6. Nearly normal appearance of brain. **D**, 3 weeks. Pattern of leukoencephalopathy has developed.

The pathologic findings of Reye syndrome have been described. Grossly in the acute stage the brain is edematous. There is sharp demarcation of the gray-/white-matter interface on brain section because of cerebral edema and demyelination. The deep white matter is swollen and the ventricles compressed [7]. Microscopically there is no evidence of inflammation. Swelling of the astrocytes and myelin bleb formation are present. These findings are compatible with an acute cytotoxic injury [8].

CT examination is not essential in the diagnosis of Reye syndrome, since CT findings when present are nonspecific. Reye syndrome must be considered when a patient has an appropriate history, abnormal liver function tests, and negative spinal tap. Diagnosis can be confirmed by liver biopsy. Once the diagnosis has been considered it must be remembered that cerebral edema is a major life-threatening complication of Reye syndrome. The CT examination may be useful in monitoring cerebral edema and determining prognosis.

REFERENCES

- Schubert WK, Bobo RC, Partin JC, Partin JS. Reye's syndrome. *DM* 1975;22:1-40
- Starko KM, Ray CG, Dominguez LB, et al. Reye's syndrome and salicylate use. *Pediatrics* 1980;66:859-864
- Russell EJ, Zimmerman RD, Leeds NE, French J. Reye syndrome. Computed tomographic documentation of disordered intracerebral structure. *J Comput Assist Tomogr* 1979;3:217-220
- Stillman A, Gitter H, Shillington D, et al. Reye's syndrome in the adult: case report and review of the literature. *Am J Gastroenterol* 1983;78:365-368
- Morse RS, Holmes AW, Levin S. Reye's syndrome in an adult. *Am J Dig Dis* 1975;20:1184-1190
- Huckman MS. Computed tomography in the diagnosis of degenerative brain disease. *Radiol Clin North Am* 1982;20:169-183
- Evans H, Bourgeois CH, Comer DS, Keschamras N. Brain lesions in Reye's syndrome. *Arch Pathol Lab Med* 1970;90:543-546
- Partin JC, Partin JS, Schubert WK, McLaurin RL. Brain ultrastructure in Reye's syndrome (encephalopathy and fatty alteration of the viscera). *J Neuropathol Exp Neurol* 1975;34:425-444