

Are your **MRI contrast agents** cost-effective?

Learn more about generic **Gadolinium-Based Contrast Agents**.



FRESENIUS  
KABI

caring for life

# AJNR

## Spontaneous closure of a dural arteriovenous fistula associated with acute hearing loss.

J A Landman and I F Braun

*AJNR Am J Neuroradiol* 1985, 6 (3) 448-449

<http://www.ajnr.org/content/6/3/448.citation>

This information is current as  
of April 19, 2024.

## Spontaneous Closure of a Dural Arteriovenous Fistula Associated with Acute Hearing Loss

Jeffrey A. Landman<sup>1</sup> and Ira F. Braun<sup>1</sup>

Dural arteriovenous malformations (AVMs) are a rare entity, accounting for 10%–15% of cranial AVMs. Sporadic reports of spontaneous regression of these arteriovenous shunts have appeared in the literature and support this event. However, the mechanism of regression has to date only been speculative. We report a case of spontaneous disappearance of an arteriovenous fistula in the middle ear associated with acute hearing loss and propose a hypothesis for its occurrence.

### Case Report

A 60-year-old woman had a 2 year history of pulsatile tinnitus behind the right ear. A right neck and cranial bruit was audible. She gave no history of previous trauma, hearing loss, or vertigo. A tentative diagnosis of jugulotympanic paraganglioma (glomus tumor) was made, and the patient was referred for arteriography. A fistula between the inferior tympanic branch of the ascending pharyngeal artery and the jugular vein was identified (fig. 1A). Direct coronal computed tomographic (CT) scans were obtained with the patient in a prone position with her neck hyperextended about 45°. She experienced total loss of hearing in her right ear, as well as cessation of her pulsatile tinnitus during scanning. Angiography was repeated 6 weeks after the CT scan. The ascending pharyngeal artery could not be subselected, and, thus, a global external carotid angiogram was obtained. The previously demonstrated fistula could not be identified (fig. 1B).

### Discussion

Dural AVMs are arteriovenous fistulas usually between the external carotid artery and dural venous structures. The vascular supply to dural AVMs has been well described in the literature [1–4]. The meningohypophyseal vessels emanating from the cavernous part of the internal carotid artery, the superficial temporal artery, the ascending pharyngeal artery, the occipital artery, and the middle meningeal artery have all been implicated.

Symptomatically, Obrador et al. [3] defined the clinical presentation in a review of 96 patients with intradural AVMs. Of the 96 patients, 68% complained of bruits secondary to

their arteriovenous shunts, and 50% experienced headache associated with the arteriovenous fistulas. Initial symptoms included papilledema in 24%, confusion and mental change in 12%, hemiparesis in 12%, meningeal signs in 13%, and associated subarachnoid hemorrhage in 20%.

Spontaneous closure of arteriovenous fistulas has been reported [5, 6]. Magidson and Weinberg [7] reported a case of spontaneous closure of a dural AVM they believed occurred secondary to elevation of venous pressure with concomitant stasis of venous flow, producing increased intracranial pressure and resulting in thrombosis of the venous sinus into which the arteriovenous shunt communicated. This theory has also been invoked by several other authors. Olutola et al. [8] reported a case of regression of a dural arteriovenous fistula that they proposed was secondary to actual thrombosis of the fistula itself. However, subarachnoid hemorrhage, edema, mass effect, parenchymal hemorrhage, and vascular spasm were all present in association with this arteriovenous fistula. It has been shown that these factors alone or in combination have resulted in closure of AVMs [9]. In addition, total disappearance has also been reported in association with sudden hemiplegia and the use of oral contraceptives [10, 11].

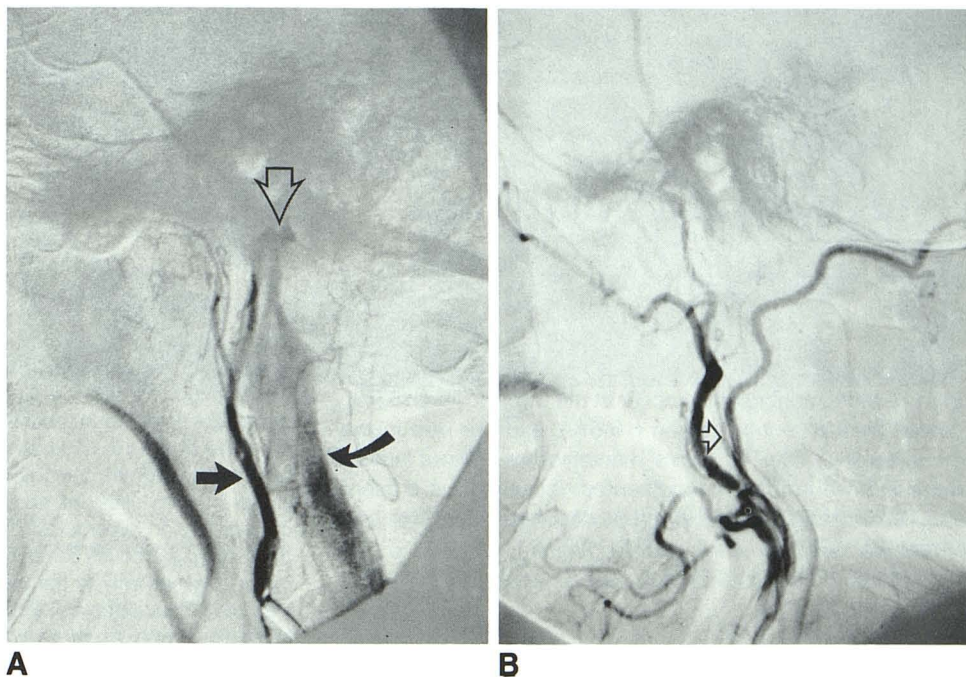
We present a case of spontaneous regression of a dural arteriovenous fistula. The patient experienced sudden hearing loss after being placed in the CT scanner with her neck hyperextended for coronal scanning. Gooding and Stimac [12] have shown that turning the patient's head causes functional obstruction of the jugular vein. We propose that by hyperextending our patient the relative stasis of venous blood induced by compression of her jugular vein led to thrombosis of her fistula and, thus, resolution of her symptoms. In addition, since the cochlear veins drain into the jugular vein, we suggest that the thrombus migrated to this vessel or that this maneuver caused an increase in venous pressure in it [13]. Increased venous pressure secondary to functional jugular vein obstruction in the presence of an arteriovenous fistula gave rise to retrograde flow and, thus, stasis in the jugular vein and, secondarily, in the cochlear venous system. We suggest that this event led to her acute hearing loss.

Received January 17, 1984; accepted after revision April 25, 1984.

<sup>1</sup> Department of Radiology, Section of Neuroradiology, Emory University School of Medicine, 1365 Clifton Rd., N.E., Atlanta, GA 30322. Address reprint requests to J. A. Landman.



Fig. 1.—A, Lateral subtracted angiogram. Catheter in ascending pharyngeal artery (straight solid arrow) with filling of fistula (open arrow) through inferior tympanic artery from ascending pharyngeal artery. Shunting through fistula into jugular vein (curved arrow). B, Global external carotid subtracted arteriogram, lateral view, 6 weeks after onset of acute hearing loss. Faint opacification of ascending pharyngeal artery (arrow) without previously noted fistula or jugular vein.



#### ACKNOWLEDGMENT

We thank Pierre Lasjaunias for help in manuscript preparation.

#### REFERENCES

1. Houser OW, Baker HL, Rhoton AL, Okazaki H. Intracranial dural arterial venous malformations. *Radiology* **1973**;105:55-64
2. Newton TH, Weidner W, Greitz T. Dural arterial venous malformation in the posterior fossa. *Radiology* **1968**;90:27-35
3. Obrador S, Soto M, Silvela J. Clinical syndromes of arterial venous malformations of the transverse-sigmoid sinus. *J Neurol Neurosurg Psychiatry* **1975**;38:436-451
4. Urdanibia JF, Silvela J, Soto M. Occipital dural arterio-venous malformations. *Neuroradiology* **1974**;7:57-64
5. Kosnik J, Hunt WE, Miller CA. Dural arteriovenous malformations. *J Neurosurg* **1974**;40:322-329
6. Kühner A, Krastel A, Stoll W. Arterio-venous malformations of the transverse dural sinus. *J Neurosurg* **1976**;45:12-19
7. Magidson MA, Weinberg PE. Spontaneous closure of a dural arterio-venous malformation. *Surg Neurol* **1976**;6:107-110
8. Olutola PS, Eliam M, Molot M, Talalla A. Spontaneous regression of a dural arterio-venous malformation. *Neurosurgery* **1983**;12:687-690
9. Nehls DG, Pittman HW. Spontaneous regression of arterio-venous malformations. *Neurosurgery* **1982**;11:776-780
10. Höök O, Johnson C. Intracranial arterio-venous aneurysms: a follow-up study with particular attention to their growth. *Arch Neurol Psychiatry* **1958**;80:39-54
11. Hansen JH, Søggaard I. Spontaneous regression of an extra- and intra-cranial arterio-venous malformation: case report. *J Neurosurg* **1976**;45:338-341
12. Gooding CA, Stimac GK. Jugular vein obstruction caused by turning of the head. *AJNR* **1983**;4:1223-1226, *AJR* **1984**;142:403-406
13. Anson BJ, Donaldson JA. *Surgical anatomy of the temporal bone*, 3d ed. Philadelphia: Saunders, **1981**:313-325, 662-669