

Are your **MRI contrast agents** cost-effective?

Learn more about generic **Gadolinium-Based Contrast Agents**.



FRESENIUS
KABI

caring for life

AJNR

Lumbar vertebral reformation after traumatic compression fracture.

R Beerman, H D Batt and B A Green

AJNR Am J Neuroradiol 1985, 6 (3) 455-456

<http://www.ajnr.org/content/6/3/455.citation>

This information is current as
of April 17, 2024.

Lumbar Vertebral Reformation after Traumatic Compression Fracture

Richard Beerman,¹ Harold D. Batt,¹ and Barth A. Green²

Surgeons who manage patients with unstable thoracolumbar vertebral-body compression fractures are familiar with the often dramatic restoration of vertebral height after distraction and internal fixation with Harrington rods [1]. Since this finding is rarely discussed in the radiology literature, though briefly mentioned by Cerullo and Meyer [2], we present an illustrative case.

Case Report

A 29-year-old man fell a distance of 8 feet (2.5 m) onto his buttocks and later complained of pain in the lower back and coccygeal region.

On physical examination, there was tenderness in the L1 area. Neurologic examination was normal.

Initial radiographs (fig. 1A) of the lumbosacral spine revealed a compression fracture of the L1 vertebra; subsequent myelography demonstrated an extradural block at the same level. At surgery, a standard posterior exposure of the dorsal arches of T10–L3 was performed. Distraction hooks were placed carefully under the laminae of T10 and L3 after hemilaminectomies at these levels. Harrington rods were passed through the hooks, and the injury site was distracted until the normal vertebral height and adjacent interspace integrity was reestablished. All the exposed facet joints were then drilled out and autogenous iliac graft fragments impacted into the defects. The laminar surfaces were decorticated and additional iliac

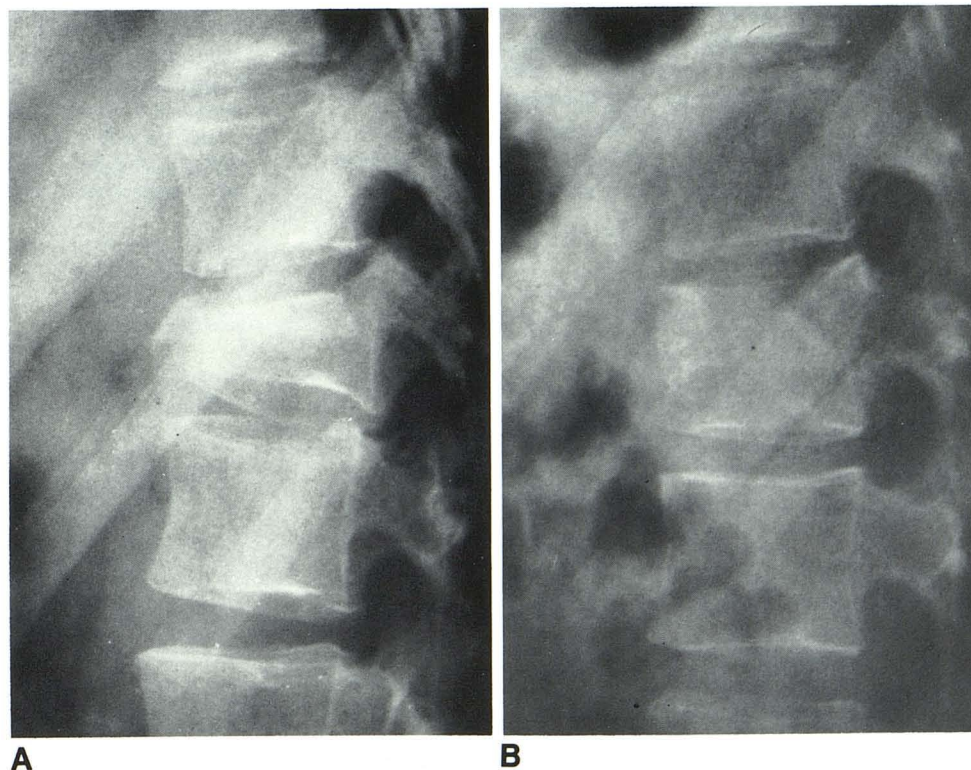


Fig. 1.—A, Initial radiograph. Compression fracture of L1 vertebra. B, 8 months after surgery. Satisfactory alignment and reformation of vertebral body.

Received March 5, 1984; accepted May 18, 1984.

¹ Department of Radiology (R-103), University of Miami School of Medicine and Jackson Memorial Hospital, P.O. Box 016960, Miami, FL 33101. Address reprint requests to R. Beerman.

² Department of Neurological Surgery, University of Miami School of Medicine and Jackson Memorial Hospital, Miami, FL 33101.

bone graft was applied.

The patient did well after surgery. He was ambulatory with a polypropylene thoracolumbar support orthosis and was maintained in the brace for 12 weeks. Postoperative radiographs (fig. 1B) demonstrated satisfactory alignment and restoration of vertebral-body height with minimal residual deformity.

Discussion

When a vertebral body is fractured by compression, the cancellous bony trabeculae are forced together, resulting in loss of height. The anterior longitudinal ligament is attached to the cortical shell of the vertebral body. If this ligament remains intact, intraoperative distraction pulls it taut, restoring the height of the cortical shell. However, since the internal cancellous fractured bone fragments remain impacted, there remains a bony defect inside the cortical shell [3]. Since the cancellous trabeculae are required for support, the fractured vertebral body would promptly collapse with weight bearing. In the past, healing of the fractured vertebral body required up to 6–8 months of bed rest or casting, with all the clinical variables affecting the duration of the healing process [4].

Various techniques have been attempted to maintain the vertebral body in a stable position to allow healing with minimal spinal deformity. However, the prolonged immobilization was associated with complications such as decubitus ulcers, urinary tract infections, thrombophlebitis, and pulmonary embolism. Therefore, immobilization was usually limited and the resultant spinal deformity was accepted [5]. Since the advent of Harrington rod instrumentation, the injured vertebral bodies can be maintained in satisfactory position and the patient does not have to be immobilized during the healing process [6]. This not only decreases the complications associated with prolonged immobilization but also maintains satisfactory alignment and prevents spinal deformity.

Restoration of vertebral-body height after traumatic compression fracture has been reported to occur without surgical intervention in children. This is probably due to longitudinal growth from each end-plate. One study of children showed more residual deformity of the vertebral body after healing if the patient was over 10 years old [7]. Pathologic compression fractures of vertebral bodies in children also have undergone reformation after treatment of the underlying disease [8].

Until recently, restoration of vertebral-body height was seldom observed after traumatic compression fractures in adults. With new techniques, however, radiologists will see this result more often.

REFERENCES

1. Connolly J. Evaluation and management of injuries to the thoracic and lumbar spine. In: Connolly J, ed. *Depalmas the management of fractures and dislocations*, 3d ed. Philadelphia: Saunders, 1981:416–428
2. Cerullo L, Meyer P. Surgical stabilization of spinal cord injury. In: Calenoff L, ed. *Radiology of spinal cord injury*. St. Louis: Mosby, 1981:226–249
3. Conwell H, Reynolds FC. Injuries of spine. In: Conwell H, Reynolds FC, eds. *Key and Cromwells management of fractures, dislocations and sprains*, 7th ed. St. Louis: Mosby, 1961:266–290
4. Gehweiler J, Osborne RL Jr, Becker RF. *The radiology of vertebral trauma*. Philadelphia: Saunders, 1980:281–286
5. Guttman L. *Spinal cord injuries. Comprehensive management and research*. Oxford: Blackwell Scientific, 1973:122–156
6. Green BA, Callahan RA, Klose KJ, Delatorre J. Acute spinal cord injury: current concepts. *Clin Orthop* 1981;154:125–135
7. Horal J, Nachenson A, Schiller S. Clinical and radiological long-term follow-up of vertebral fractures in children. *Acta Orthop Scand* 1972;43:491–503
8. Caffey J. The vertebral column. In: *Pediatric x-ray diagnosis*, 6th ed. Chicago: Year Book Medical, 1972:1377–1380