

Are your **MRI contrast agents** cost-effective?

Learn more about generic **Gadolinium-Based Contrast Agents**.



**FRESENIUS
KABI**

caring for life

AJNR

Sonographic Appearance of the Torcular Herophili

Sharon R. Segal and Henrietta Kotlus Rosenberg

AJNR Am J Neuroradiol 1985, 6 (6) 919-922

<http://www.ajnr.org/content/6/6/919>

This information is current as
of April 18, 2024.

Sonographic Appearance of the Torcular Herophili

Sharon R. Segal¹
Henrietta Kotlus Rosenberg¹

The sonograms of 12 infants aged 2 days to 7 months were evaluated to determine if the torcular Herophili could be demonstrated routinely on cranial sonography. Sonography, which was performed for a variety of indications (prematurity, seizures, hydrocephalus, sepsis, congenital anomalies, and subarachnoid hemorrhage) demonstrated the torcular Herophili in all cases. It appeared as a variable-sized, anechoic, and triangular or elongated structure inferior to the occipital lobes, posterior to the cerebellum, and just inside the cranial vault. Correlation with computed tomographic scans was available in four patients. A detailed description of the normal anatomy of the torcular Herophili is provided. Knowledge of the variable sonographic appearance of the torcular Herophili is important to distinguish it from a pathologic entity.

Unless the torcular Herophili and dural sinuses are usually prominent, they may not be routinely demonstrated on cranial sonograms. These structures and their variable appearances have been well documented with computed tomography (CT) [1, 2] but not previously with sonography. We wish to review the anatomy of the confluence of the sinuses and present the spectrum of sonographic findings of this important venous structure.

Our initial attention to the torcular Herophili sonographically was established when we examined a 5-day-old 38 week gestation boy with hypoglycemia and seizures. We noted a 3.0 × 3.4 × 0.8 cm anechoic area inferior to the occipital lobes in the midline, suggesting a subdural collection or a prominent torcular Herophili. The examination was otherwise unremarkable (figs. 1A and 1B). A CT scan the same day demonstrated no evidence of abnormal dural collection or hemorrhage (fig. 1C). The final conclusion of the sonographic examination was that the findings did indeed represent the dural sinuses.

Normal Anatomy

The cerebral veins, which do not accompany the arteries, arise from the cortical substance, forming a pial plexus. After a variable distance these veins pass through the subarachnoid space into larger intercommunicating channels, the dural sinuses. These sinuses, located between the meningeal and periosteal layers of the dura, are lined with endothelium, with walls that are composed of the tough fibrous tissue of the dura [3].

The superior sagittal sinus courses within the superior margin of the falx cerebri until it approaches the torcular Herophili at the occipital protuberance. The sinus caliber progressively enlarges as it travels caudally [3].

The inferior sagittal sinus extends caudally along the free border of the falx. At the anterior border of the tentorium, it is joined by the great vein of Galen, which drains the deep structures of the brain; the two veins join to form the straight sinus. This sinus runs backward and downward along the line of attachment of the falx and tentorium to join the superior sagittal sinus near the internal occipital

This article appears in the November/December 1985 issue of *AJNR* and the January 1986 issue of *AJR*.

Received August 29, 1984; accepted after revision April 11, 1985.

¹ Department of Radiology, Subdivision of Ultrasound, Children's Hospital of Philadelphia, 1 Children's Center, Philadelphia, PA 19104. Address reprint requests to H. K. Rosenberg.

AJNR 6:919-922, November/December 1985

0195-6108/85/0606-0919

© American Roentgen Ray Society

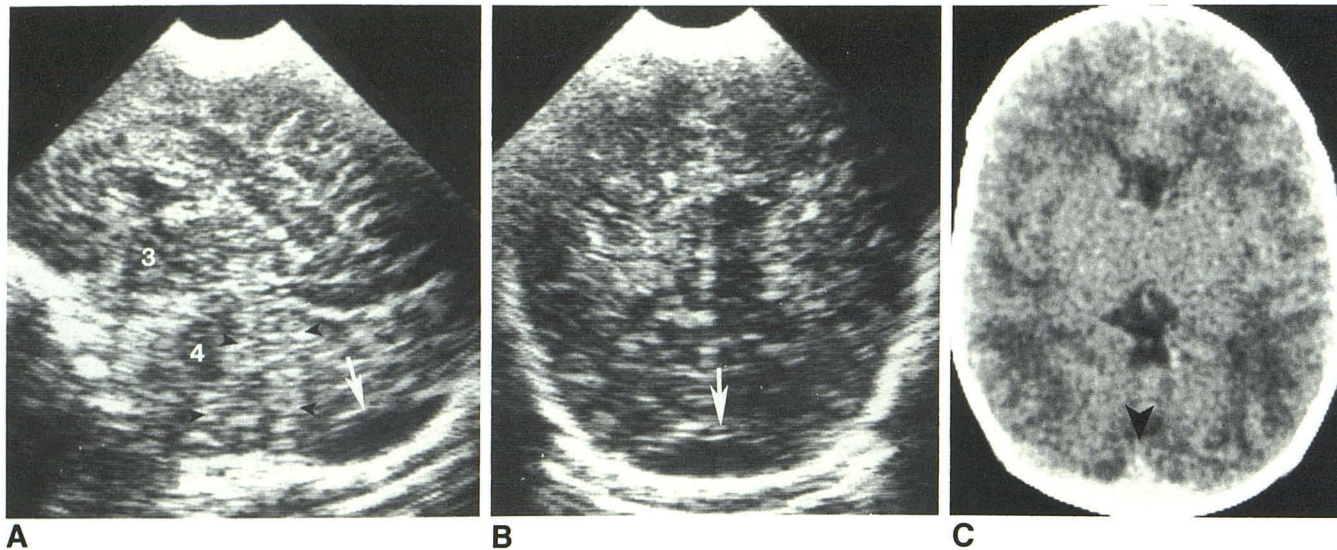


Fig. 1.—A, Midsagittal section of brain demonstrating torcular Herophili. Anechoic structure (arrow) posterior to cerebellum (arrowheads) and inferior to (occipital lobes) cerebral hemispheres consistent with confluence of sinuses. 3

= third ventricle; 4 = fourth ventricle. B, Posterior coronal view. Torcular Herophili (arrow). C, Contrast-enhanced axial CT scan. Torcular Herophili (arrowhead).

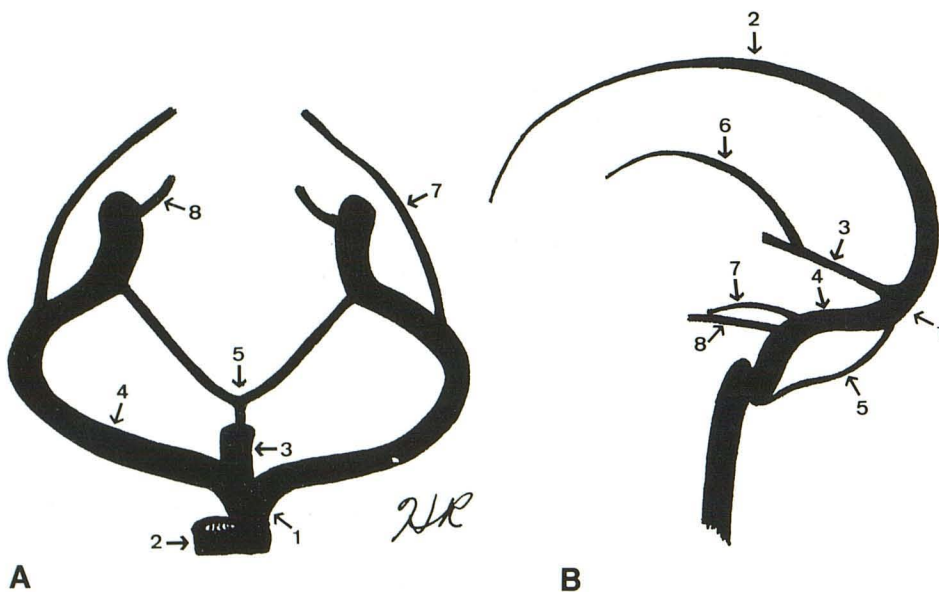


Fig. 2.—Venous anatomy in coronal (A) and sagittal (B) planes. 1 = torcular Herophili; 2 = superior sagittal sinus; 3 = straight sinus; 4 = transverse sinus; 5 = occipital sinus; 6 = inferior sagittal sinus; 7 = superior petrosal sinus; 8 = inferior petrosal sinus.

protuberance [3].

The transverse sinuses continue from the occipital protuberance. Usually these channels slope downward along the groove on either side of the occipital bone, then anteriorly along the mastoid portion of the parietal and temporal bones, ending at the jugular foramen. The anteroinferior continuation of these channels are the sigmoid sinuses [4].

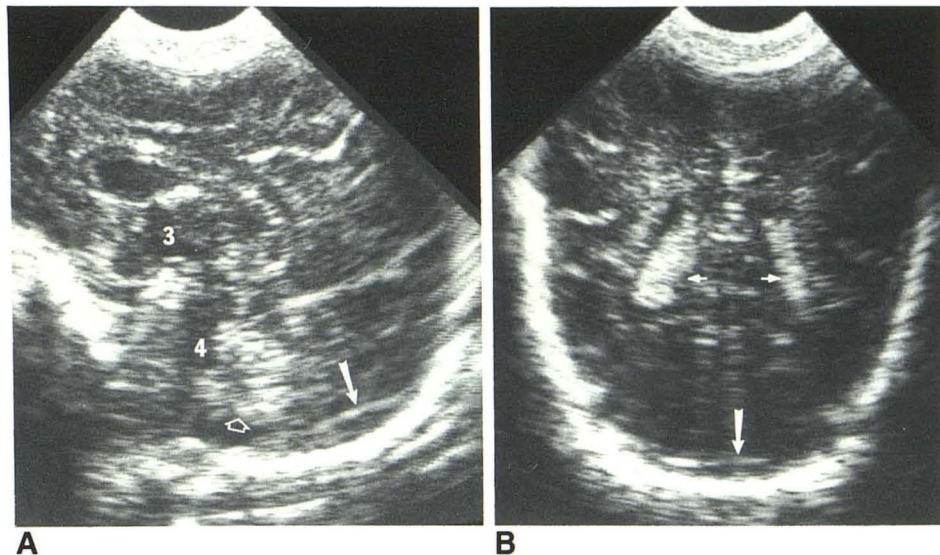
The torcular Herophili is formed by the joining of the superior sagittal sinus, the transverse sinuses, and the straight sinus (fig. 2). On angiography the torcular Herophili and transverse sinuses usually form an inverted T with the superior sagittal sinus. Venous drainage often is asymmetric [5]. A small unpaired occipital sinus from the area of the foramen magnum rises in the falx cerebelli to join the torcular Herophili [3].

Wide variation is demonstrated by this confluence. Rarely is there actual union of these sinuses. Often the superior sagittal sinus turns to the right to become continuous with the transverse sinus while the straight sinus bends to the left as the left transverse sinus [3]. The torcular Herophili may be displaced from the midline by a superior extension of a large cisterna magna. The confluence may lie as much as 1 cm anterior to the occipital bone or to one side of the midline [2].

Subjects and Methods

A prospective evaluation was done to establish whether or not the torcular Herophili could be demonstrated routinely on cranial sonograms. We performed real-time cranial sonographic examinations in

Fig. 3.—**A**, Midsagittal section of brain. Routine appearance of torcular Herophili (solid arrow) posterior to cerebellum (open arrow) and inferior to occipital lobes. 3 = third ventricle; 4 = fourth ventricle. **B**, Posterior coronal view. Torcular Herophili (long arrow). Choroid plexuses (short arrows).



12 infants referred for miscellaneous indications (prematurity, six; hydrocephalus, one; seizures, two; sepsis, one; multiple congenital anomalies, one; and subarachnoid hemorrhage on CT, one). The age of the patients ranged from 2 days to 7 months. Gestational ages ranged from 28 to 42 weeks. Four patients had CT scans within 8 days of sonography and the areas of interest were compared.

The sonograms were obtained with the ATL Mark 100 real-time unit (3.0, 5.0, and 7.5 MHz transducer). Coronal and sagittal views were obtained in all the patients. The CT scans were obtained with the GE 8800 scanner and the axial views were reviewed.

Results

The torcular Herophili was identified on all images. It appeared similar on sonograms and on CT scans in all but two cases. One patient demonstrated prominent dural sinuses on sonography and not on CT, while a second patient demonstrated prominent confluence of sinuses on CT and not on sonography.

Best demonstration of the torcular Herophili was made with careful examination of the posterior fossa, with steep angling posterior to the cerebellum. The torcular Herophili was imaged as an anechoic, triangular, or elongated structure just inside the cranial vault, inferior to the occipital lobes, posterior to the cerebellum. The size of the structure was variable (fig. 3).

Discussion

The normal anatomy of the brain has been well demonstrated sonographically [6–12]. Recently, Monsaingeon et al. [13] reported the normal arterial vascular anatomy of the brain. The arterial supply, including branches of the internal carotid artery and the vertebral artery distribution, were demonstrated. The venous anatomy has not been described. However, with careful examination of the area posterior to the cerebellar hemispheres and inferior to the occipital lobes, one can see

the torcular Herophili. Attenuation by the echogenic cerebellar hemispheres may impede satisfactory imaging unless appropriate posterior angling is done.

In conclusion, demonstration of the torcular Herophili and dural sinus drainage of the neonatal brain can be performed routinely. The torcular Herophili may vary in size and configuration as an anechoic, triangular, elongated structure inferior to the occipital lobes just behind the cerebellum. This anatomic structure should be recognized sonographically to obviate pathologic study by other methods.

REFERENCES

1. Naidich TP, Pudlowski RM, Leeds NE, Naidich JB, Curisolm AJ, Rifkin MD. The normal contrast-enhanced computed axial tomogram of the brain. *J Comput Assist Tomogr* 1977;1:16–29
2. Lee SH, Rao KCVG. *Cranial computed tomography*. New York: McGraw Hill, 1983;48:690
3. Carpenter M, Sutin J. *Human neuroanatomy*. Baltimore: Williams & Wilkins, 1981:712, 732–737
4. Netter F. *The Ciba collection of medical illustrations*. Summit, NJ: Ciba, 1972:34
5. Osborn AG. *Introduction to cerebral angiography*. Hagerstown, MD: Harper & Row, 1980:340–341
6. Pigadas A, Thompson JR, Grube G. Normal infant brain anatomy: correlated real-time sonograms and brain specimens. *AJNR* 1981;2:339–344, *AJR* 1981;137:815–820
7. Shuman WP, Rogers JV, Mack LA, Ellsworth CA, Christie DP. Real-time sonographic sector scanning of the neonatal cranium: technique and normal anatomy. *AJNR* 1981;2:349–356, *AJR* 1981;137:821–828
8. Slovis TL, Kuhns LR. Real-time sonography of the brain through the anterior fontanelle. *AJR* 1981;136:277–286
9. Grant EG, Schellinger D, Borts FT, et al. Real-time sonography of the neonatal and infant head. *AJR* 1980;1:487–492, *AJR* 1981;136:265–270
10. Edwards MK, Brown DL, Muller J, Grossman CB, Chua GT. Cribside neurosonography: real-time sonography for intracranial

- investigation of the neonate. *AJNR* **1980**;1:501-505, *AJR* **1981**;136:271-276
11. Babcock DS, Han BK. The accuracy of high resolution, real-time ultrasonography of the head in infancy. *Radiology* **1981**; 139:665-676
 12. Goodwin L, Quisling RG. The neonatal cisterna magna: ultrasonic evaluation. *Radiology* **1983**;149:691-695
 13. Monsaingeon S, Tuabault S, Bomsel F. Normal vascular anatomy of transfontanellar real-time ultrasound in the newborn. *Ann Radiol* **1984**;27:228-234