

Are your **MRI contrast agents** cost-effective?

Learn more about generic **Gadolinium-Based Contrast Agents**.



FRESENIUS  
KABI

caring for life

**AJNR**

**Use of coils for transcatheter carotid occlusion.**

I F Braun, J C Hoffman, Jr, W J Casarella and P C Davis

*AJNR Am J Neuroradiol* 1985, 6 (6) 953-956

<http://www.ajnr.org/content/6/6/953.citation>

This information is current as  
of April 18, 2024.

## Use of Coils for Transcatheter Carotid Occlusion

Ira F. Braun,<sup>1</sup> James C. Hoffman, Jr., William J. Casarella, and Patricia C. Davis

The preferred treatment of various internal carotid aneurysms deemed surgically inaccessible involves the occlusion of the carotid artery with subsequent thrombosis of the aneurysm. Carotid occlusion can be accomplished surgically either by abrupt ligation or with the use of a controlled gradual occlusive device such as a Selverstone clamp [1, 2]. Recently a transcatheter detachable balloon system was described that accomplishes this task without surgery [3].

The use of coils or occluding spring emboli (Cook, Bloomington, IN) for transcatheter arterial occlusion, first described by Gianturco et al. [4] in 1975, has received little attention in the neuroradiologic literature, save for two case reports involving branches of the external carotid artery, a venous sac [5, 6], and a case of vertebral artery occlusion for control of hemorrhage [7]. To our knowledge no cases have been reported using this device for transcatheter carotid occlusion. We report the use of coils for this purpose in two patients with internal carotid aneurysms: one in conjunction with detachable balloons and one in which coils were used as the only therapy in an effort to prevent exsanguination.

### Case Reports

#### Case 1

An 18-year-old woman was admitted 1 year after acute onset of horizontal field-gaze diplopia immediately after a 5 day febrile illness diagnosed as a "viral syndrome." Her right eye was noted to turn in on primary gaze. In the last several months preceding admission the patient complained of fluctuating pupil size accompanied by photophobia of the right eye without complaints of inflammation or redness, which had subsequently resolved spontaneously. No other neurologic symptoms were elicited. Neurologic examination revealed a complete paralysis of lateral gaze in the right eye associated with dilated and tortuous episcleral vessels in both eyes. No other ocular abnormalities were seen. The examination was otherwise unremarkable.

After a CT scan of the cavernous region and orbits revealed bilateral parasellar enhancing mass lesions, an angiogram was obtained. Bilateral cavernous carotid aneurysms were documented, with only the symptomatic one shown (fig. 1A). Since her only complaint was purely paralysis of lateral gaze on the right, it was elected not to intervene and follow her closely.

About 2 months after the initial workup the patient started com-

plaining of intolerable bouts of severe pain over her right eye accompanied by occasional bursts of paroxysmal left eye pain. This, together with her incomplete abduction palsy, prompted intervention.

It was decided clinically by the neurosurgeon involved that the best treatment would be a superficial temporal artery to middle cerebral artery (STA-MCA) bypass, purely performed as a "safeguard" measure, to be followed immediately by balloon occlusion of the right internal carotid artery.

After an uneventful bypass procedure and after regaining consciousness after anesthesia, the patient was brought to the neuroangiographic suite for balloon occlusion. Five Debrun detachable balloons (Ingenor Medical, Paris) were prepared according to the instructions for attachment supplied by the manufacturer the day before the procedure. Leaks were discovered in three of these balloons on the day of the procedure. However, we elected to proceed since we feared that the STA-MCA bypass would thrombose if the procedure were delayed until the next day. A no. 16 detachable Debrun balloon was maneuvered into the precavernous carotid artery and inflated for 20 min under systemic heparinization and constant neurologic monitoring to test tolerance to carotid occlusion. After it was deemed that she could tolerate occlusion, this balloon was detached. As the second "safety" balloon was being readied for more proximal detachment, it was noted that the first balloon was slowly leaking. The second "safety" balloon was then quickly put into position just proximal to the first balloon and inflated with subsequent complete deflation of the first balloon. After considerable difficulty the second balloon was then detached. At this time it was noted that this balloon had inadvertently folded over on itself and was detached in this position. Immediately after detachment, the second balloon was noted to change shape somewhat and had migrated about 1 cm rostrally. Since no additional balloons were available, and fearing deflation of the second balloon, five 5 mm coils were deposited into the lumen of the internal carotid artery starting just proximal to the second balloon and ending just distal to the carotid bifurcation (fig. 1B). Heparinization was then reversed with protamine, and the postembolization angiogram (fig. 1C) revealed complete carotid occlusion with filling of a middle cerebral artery branch via the STA-MCA. The patient tolerated this procedure well but was noted to be somewhat lethargic with slight left-hand weakness on the first postembolization day. CT revealed a small area of lucency in the right frontal region that was interpreted as representing a watershed infarct. The patient was treated with volume expansion, and both her level of consciousness and her decreased strength in the left hand reverted to normal before discharge 1 week later. At discharge it was noted that her right sixth nerve palsy had somewhat improved and her orbital pain had resolved.

Received December 28, 1984; accepted after revision April 9, 1985.

<sup>1</sup> All authors: Department of Radiology, Emory University Hospital, 1364 Clifton Rd., N.E., Atlanta, GA 30322. Address reprint requests to I. F. Braun.

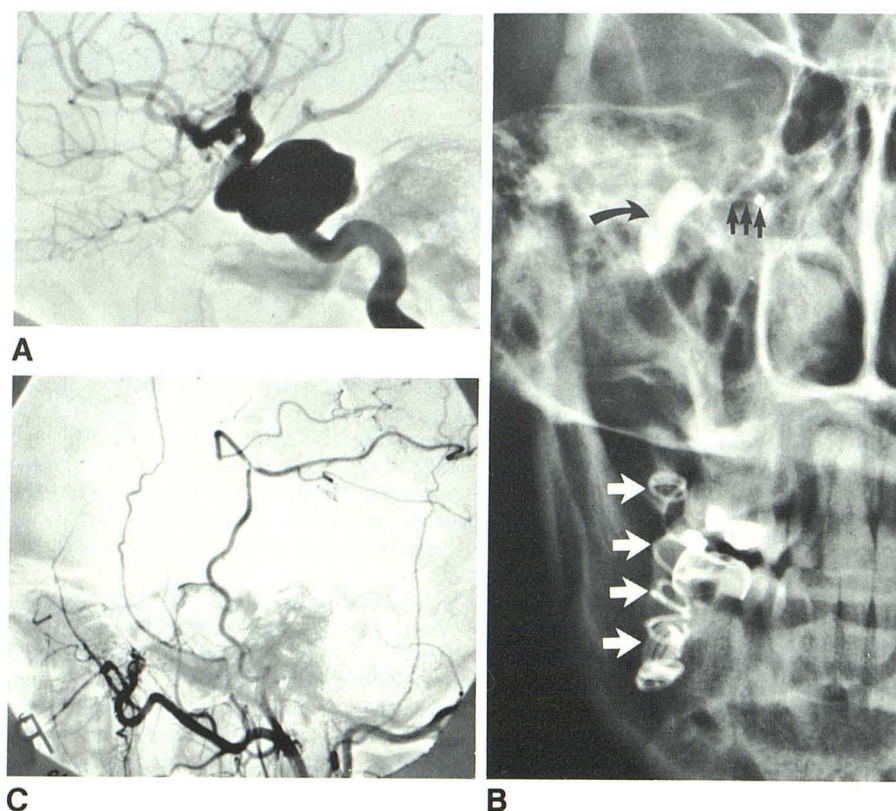


Fig. 1.—Case 1. A, Lateral view of right internal carotid angiogram. Large cavernous aneurysm extends posteriorly. B, Anteroposterior view of skull base after embolization. Silver clip and deflated balloon (*straight black arrows*) are within precavernous segment of internal carotid lumen. Deformed, inverted, somewhat deflated second proximal "safety" balloon (*curved arrow*) is just proximal to first deflated balloon. Second balloon is in more rostral position than when originally detached. Five 5 mm coils are within lumen of cervical internal carotid artery (*white arrows*). C, Lateral view of immediate postembolization angiogram. Complete occlusion of internal carotid artery and patency of STA-MCA bypass. Minimal filling of cavernous aneurysm via ophthalmic artery.

#### Case 2

A 13-year-old girl was admitted for upper respiratory tract bleeding associated with upper airway obstruction. She was healthy, active, and free of symptoms until 3 weeks before admission when she developed fever and a left-sided earache associated with left neck swelling. A diagnosis of acute otitis was made and she was treated with antibiotics. Her symptoms improved within 1 week; however, she still had a minimal earache accompanied by a productive cough. Ten days before admission she became dizzy, experienced chills, and "nearly collapsed" while at a concert. She then developed increasing ear pain, neck pain, and, for the first time, hoarseness and difficulty swallowing. At about this time she began developing partial upper airway obstruction. During the 2½ weeks before admission she was maintained on conservative medical therapy, which consisted of antibiotics and symptomatic treatment.

She was admitted to an outside hospital after an otolaryngologist noted an "abnormal" left drum, pooling of mucous in the piriform sinuses, obstruction of the nasopharynx, and left vocal cord paralysis. One day before admission, bright red bleeding was noted to come from her nose after she had coughed and vomited. This was followed by projectile bleeding of a copious amount of bright red blood from her mouth.

On admission to our facility, the patient was hoarse and complained of left ear pain. Her head was tilted to the left with ptosis of the left eye and associated miosis. The left neck and ear were tender to palpation. A large 4 × 4 cm pharyngeal mass was noted high in the left oral and nasopharynx displacing the soft palate anteriorly, simulating a peritonsillar abscess. No trismus, however, was noted. Left vocal cord paralysis was appreciated. On admission her hemoglobin

was 12.1 g/dl with a 36% hematocrit. Prothrombin and partial thromboplastin times were normal. A lateral skull film revealed a large nasopharyngeal mass, and a CT study in the axial and coronal planes revealed a large left parapharyngeal space mass encroaching on the nasopharynx.

During the course of the night after CT the patient vomited a copious amount of blood with a resultant drop of her hematocrit to 28%. It was decided to pack her airway and perform a tracheostomy. After tracheostomy the patient spontaneously bled around the nasopharyngeal packing, and, in a period of 3–5 min, almost exsanguinated with a loss of her blood pressure and vital signs. The nasopharynx was tamponaded, resuscitative measures successfully carried out, and the patient was transported to the angiography suite where an angiogram revealed the presence of a large cervical internal carotid aneurysm (fig. 2A). An angiogram of the vertebrobasilar system and contralateral internal carotid artery was obtained to determine potential collateral supply.

After consultation with the vascular surgical team, which decided that a direct surgical approach would be too difficult, it was decided to emergently occlude the internal carotid artery via a transcatheter technique. However, no detachable balloons were available, and a decision was made to use coils to occlude the internal carotid artery. An 8-mm-diameter coil was maneuvered distal to the aneurysm into the petrous carotid artery, followed by the deposition of 5 mm coils proximal to this with eventual deposition of coils from the petrous carotid proximally to a point just distal to the bifurcation of the common carotid artery, including the neck of the aneurysm (fig. 2B), requiring a total of 12, 5 mm coils. A postembolization angiogram revealed carotid occlusion and filling of the intracranial vessels via collaterals (fig. 2C).

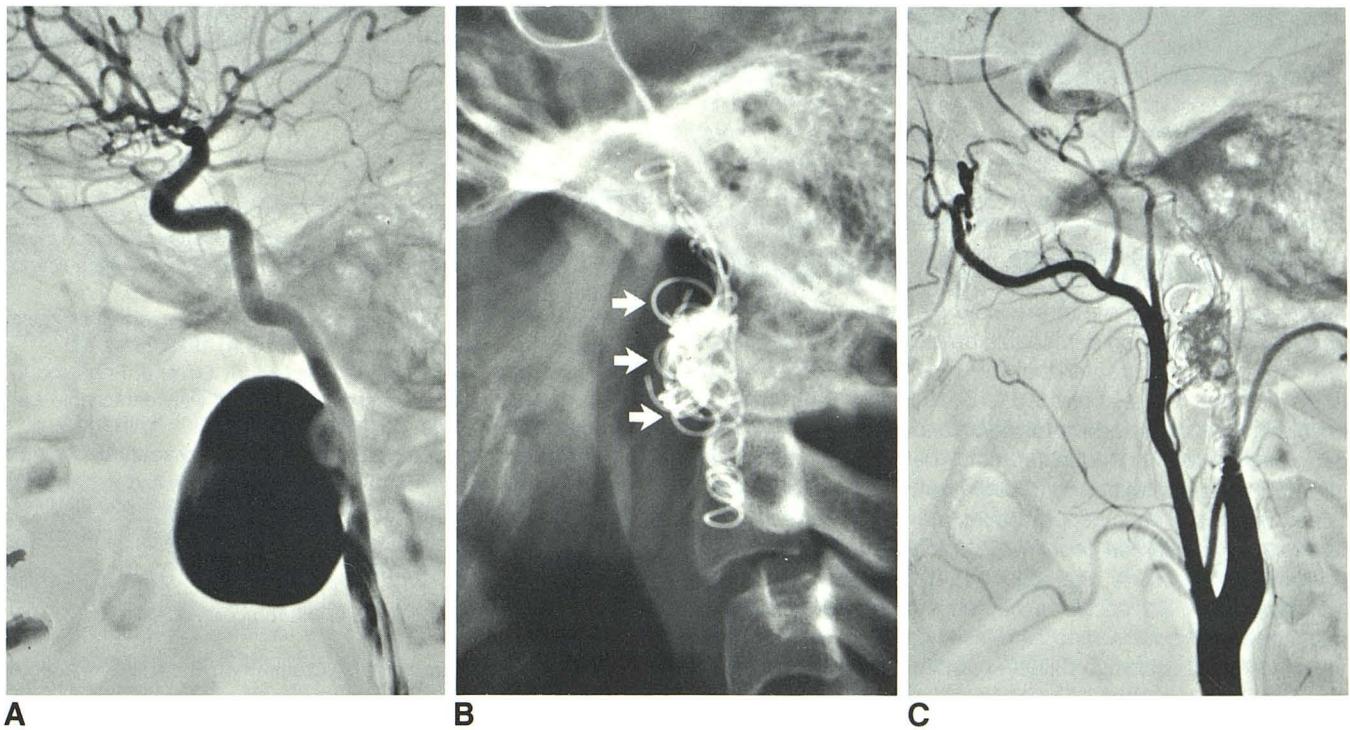


Fig. 2.—Case 2. **A**, Lateral view of high cervical internal carotid artery during internal carotid artery angiogram. Large, anteriorly directed cervical internal carotid artery aneurysm. **B**, Region of skull after deposition of coils for carotid occlusion. Coils are deposited distal to, in neck of (arrows), and proximal to

aneurysm. Those coils delineated by arrows enter neck of aneurysm. **C**, Postembolization angiogram with coils in place. Cervical internal carotid artery is successfully occluded. Filling of cavernous carotid artery is via collateral flow from distal internal maxillary artery and various ophthalmic collaterals.

She tolerated this procedure well and left the angiography suite neurologically intact. She continued with a relatively uneventful hospital course. The packing was removed 2 days after embolization without incident, and she was discharged with some dysphagia, left vocal cord paralysis, and Horner syndrome.

## Discussion

Aneurysms of certain parts of the internal carotid artery, by virtue of their relatively inaccessible locations, can be directly treated surgically only with great difficulty. Two such locations include the high cervical internal carotid artery and the cavernous part of the carotid artery [3, 8]. Carotid ligation, originally used as a means for controlling severe hemorrhage in the neck, is considered the treatment of choice for unclipable aneurysms of the intracranial part of the internal carotid artery [2]. This method of treatment also appears to be the most expeditious one in cases of rupture of a high cervical internal carotid aneurysm, such as in our second case. Surgical exposure for direct repair of the high cervical internal carotid artery requires extensive dissection through facial musculature, mandibular osteotomies, and, at times, rerouting of the facial nerve [9, 10], frequently leaving the patient with various cranial nerve palsies.

Occlusion of the internal carotid artery can be accomplished in different ways. Abrupt ligation of this vessel has been performed many times in the past [11, 12]. A gradual occlu-

sive device such as a Selverstone clamp, which allows some control over tolerance to occlusion, is favored by some [2, 8], although there is no definitive support in the literature that this method is any safer than abrupt carotid occlusion [1]. Indeed, 38% of 62 patients at the Mayo Clinic treated with gradual occlusion developed ischemic complications as opposed to 25% of those treated with abrupt occlusion [12].

Endovascular "ligation" of carotid arteries for unclipable aneurysms using a detachable balloon technique, introduced by Debrun et al. [3], continues to enjoy success. After it is ascertained that carotid occlusion can be tolerated, using balloon occlusion under systemic heparinization for 20–25 min with close monitoring of neurologic status, the initial balloon is detached at an appropriate site. We then routinely insert another balloon into the carotid artery and detach this second balloon just proximal to the original one as a safety mechanism, preventing inadvertent migration of a leaky distal balloon, as occurred in case 1. At this point, because no additional balloons were available and the second "safety" balloon had changed position, immediate occlusion of the carotid was successfully accomplished using stainless steel coils.

In case 2, detachable balloons were not available. After the vascular surgical team decided that this aneurysm was surgically inaccessible and carotid occlusion was the treatment of choice, coils were deposited in the cervical internal carotid artery. The initial coil was placed above the neck of the

aneurysm, and subsequent coils were successfully deposited proximally in minutes to occlude the neck of the aneurysm and the more proximal internal carotid artery.

Coils, as vascular occlusion devices, were introduced in 1975 by Gianturco et al. [4] with subsequent refinements made in their design and delivery system by Anderson et al. [13] and Chuang et al. [14]. These coils, or occluding spring emboli, are made from segments of stainless steel guide wire, preshaped to form a helix in diameters of 3, 5, 8, 10, 12, and 15 mm [13]. Dacron strands are enmeshed in the turns of the helical spring to promote thrombosis. The coils are considerably easier to use than detachable balloons, requiring a delivery catheter of no greater than 5 French with a 0.038 inch (0.97 mm) end hole as opposed to 8–10 French catheters for balloons. Various sizes are always readily available without prior preparation. If used instead of a detachable balloon for carotid occlusion, tolerance to occlusion could still be ascertained under systemic heparinization via the use of a nondetachable double-lumen occlusive balloon catheter. After this determination is made, the balloon is deflated and coils may be inserted via the occlusive catheter, obviating a catheter exchange and reducing the time involved for the procedure. When using an occlusive balloon catheter for this purpose, a 7 French catheter must be used for coil deposition to get the appropriate inner diameter. It is critical to measure the caliber of the carotid artery accurately and to select the coil diameter that is at least 2–3 mm greater than the arterial diameter. Placed in this fashion, coils are stable in position and very rarely migrate distally. In our experience, coils of a diameter greater than the artery being occluded are less likely to migrate distally than are balloons, which may decrease in diameter after detaching.

For the present, we believe that, in our hands and with our experience, we will continue to use the detachable balloon technique for carotid occlusion. However, the use of coils for vascular occlusion elsewhere in the body has been used for many years enjoying a great success rate, and in one of our author's experience (W. J. C.), it allows a complete and permanent occlusion. Because of the lack of a large series of cases of carotid occlusion using coils, it is unclear to us at present which method of carotid occlusion is preferred. It is probable, however, that more radiologists in practice have a great deal more facility with coils than they do with balloons, which require a certain degree of experience and facility in attaching and detaching. The introduction of the use of coils

for the purpose of carotid occlusion conceivably may ultimately allow more patients with relatively inaccessible carotid aneurysms to undergo what we believe is the treatment of choice for this disorder.

#### REFERENCES

1. Heros RC. Thromboembolic complications after combined internal carotid ligation and extra- to intracranial bypass. *Surg Neurol* **1984**;21:75–79
2. Drake CG. Giant intracranial aneurysms: experience with surgical treatment in 174 patients. *Clin Neurosurg* **1979**;26:12–95
3. Debrun G, Fox A, Drake C, Peerless S, Girvin J, Ferguson G. Giant unclippable aneurysms: treatment with detachable balloons. *AJNR* **1981**;2:167–173.
4. Gianturco C, Anderson JH, Wallace S. Mechanical devices for arterial occlusion. *AJR* **1975**;124:428–435
5. Castaneda-Zuniga WR, Lennert M, Nath PH, Zollikofer C, Velasquez G, Amplatz K. Therapeutic embolization of facial arteriovenous fistulae. *Radiology* **1979**;132:599–602
6. Han SS, Parry CE, Simeone FA. Embolization of a dural arteriovenous malformation using Gianturco coils. *AJNR* **1982**;3:341–343
7. Bergsjordet B, Strother GM, Crummy AB, Levin AB. Vertebral artery embolization for control of massive hemorrhage. *AJNR* **1984**;5:201–203
8. Spetzler RF, Schuster H, Roski RA. Elective extracranial-intracranial arterial bypass in the treatment of inoperable giant aneurysms of the internal carotid artery. *J Neurosurg* **1980**;53:22–27
9. Batzdorf U, Gregorius FK. Surgical exposure of high cervical carotid artery: experimental study and review. *Neurosurgery* **1983**;16:657–661
10. Dichtel WJ, Miller RH, Woodson GE, Feliciano DV, Hurt J. Lateral mandibulotomy: a technique of exposure for penetrating injuries of the internal carotid artery at the base of the skull. *Laryngoscope* **1984**;94:1140–1144
11. Miller JD, Jawad K, Jennett B. Safety of carotid ligation and its role in the management of intracranial aneurysms. *J Neurol Neurosurg Psychiatry* **1977**;40:64–72
12. Landolt M, Millikan CHL. Pathogenesis of cerebral infarction secondary to mechanical carotid artery occlusion. *Stroke* **1970**;1:52–62
13. Anderson JR, Wallace S, Gianturco C, Gerson LP. "Mini" Gianturco stainless steel coils for transcatheter vascular occlusion. *Radiology* **1979**;132:301–303
14. Chuang VP, Wallace S, Gianturco C. A new improved coil for tapered-tip catheter for arterial occlusion. *Radiology* **1980**;135:507–509