Are your MRI contrast agents cost-effective?
Learn more about generic Gadolinium-Based Contrast Agents.
FRESENIUS KABI
caring for life

AJNR

Suprasellar arachnoid cysts: 2. Evaluation of CSF dynamics.

L R Gentry, A H Menezes, P A Turski, W R Smoker, S H Cornell and L Ramirez

AJNR Am J Neuroradiol 1986, 7 (1) 87-96
http://www.ajnr.org/content/7/1/87

This information is current as of April 18, 2024.

Suprasellar Arachnoid Cysts: 2. Evaluation of CSF Dynamics

Lindell R. Gentry[1,2]
Arnold H. Menezes[3]
Patrick A. Turski[4]
Wendy R. K. Smoker[1]
Steven H. Cornell[1]
Lincoln Ramirez[5]

Suprasellar arachnoid cysts are an infrequent but surgically remediable cause of hydrocephalus and neurologic deficits. The optimal method of treatment varies according to whether the cyst communicates with the subarachnoid space; the presence or absence of associated hydrocephalus; and the exact site(s) and severity of intraventricular and extraventricular cerebrospinal fluid (CSF) obstruction. Eight patients with suprasellar arachnoid cysts are described to emphasize the importance of pretherapeutic investigation of CSF dynamics. The variability of the ventriculocisternal-cyst CSF dynamics and the value of metrizamide computed tomographic cisternography and ventriculography in investigation of the CSF pathways are stressed. A diagnostic approach to the evaluation of the CSF dynamics is outlined, based on whether hydrocephalic or compressive symptoms predominate.

Suprasellar arachnoid cysts (SSAC) are unusual basal midline masses that represent an infrequent but treatable cause of hydrocephalus and neurologic deficits. In a review of the literature in 1982, Hoffman et al. [1] identified only 46 previously published cases and described eight additional patients. Although uncommon, many SSAC probably go unrecognized or are misdiagnosed as other lesions (e.g., aqueductal stenosis, extraventricular obstructive hydrocephalus, ependymal cysts of the third ventricle) [2–5]. Most SSAC are congenital, secondary to an imperforate membrane of Liliequist [6–7], but others may arise as a result of basal adhesive arachnoiditis from prior infection, trauma, surgery, or subarachnoid hemorrhage [3, 8–11]. The imperforate membrane of Liliequist (or similar acquired arachnoidal web) results in partial or complete obstruction of cerebrospinal fluid (CSF) flow at the level of the suprasellar cistern. CSF pulsations and elevated pressure below the obstructing membrane result in upward expansion of the membrane to form a cystic diverticulum that communicates with the pontine cistern [6–7]. Progressive enlargement leads to invagination of the elongated diverticulum (*communicating cyst*) through the hypothalamus into the third ventricle [7]. *Noncommunicating cysts* in the suprasellar area probably arise when the thin, elongated neck of the diverticulum is pinched off, forming a true cyst [7]. Infection, trauma, or subarachnoid hemorrhage seems to have a role in the obliteration of the neck of the diverticulum in some cases [7]. Binitie et al. suggest that the neck of the elongated diverticulum may become mechanically compressed by the fundus of the cyst when it "rolls up" on itself, resulting in a loss of communication with the subarachnoid space [11].

Hydrocephalus is a common presenting feature, especially in those who are symptomatic from infancy, and may be secondary to either extraventricular or intraventricular CSF obstruction [1, 2, 12–15]. Extraventricular block may result from CSF obstruction at the tentorial incisura by the imperforate membrane (web) or from compression of the suprasellar cisterns by the SSAC [7, 14, 15]. Intraventricular block may occur secondary to severe compression of the anterior aspect of the third ventricle or foramina of Monro by the intraventricular component of the

Received February 13, 1985; accepted after revision July 5, 1985.

Presented at the annual meeting of the American Society of Neuroradiology, Boston, June 1984.

[1] Department of Radiology, University of Iowa Hospitals and Clinics, Iowa City, IA 52242.

[2] Present address: Department of Radiology, University of Wisconsin Hospitals and Clinics, Madison, WI 53792. Address reprint requests to L. R. Gentry.

[3] Department of Neurosurgery, University of Iowa Hospitals and Clinics, Iowa City, IA 52242.

[4] Department of Radiology, University of Wisconsin Hospitals and Clinics, Madison, WI 53792.

[5] Department of Neurosurgery, University of Wisconsin Hospitals and Clinics, Madison, WI 53792.

***AJNR* 7:87–96, January/February 1986**
0195–6108/86/0701–0087
© American Society of Neuroradiology

cyst or from displacement and kinking of the aqueduct [15]. Compressive symptoms may predominate in some patients owing to direct mass effect on adjacent neural structures [2, 15].

Failure to consider the complex CSF dynamics of SSAC (table 1) is a frequent but underemphasized cause of unsuccessful initial treatment [1, 10, 13, 16]. The choice and effectiveness of therapeutic options (ventriculoperitoneal shunting, lumboperitoneal shunting, cystoperitoneal shunting, cyst resection/marsupialization/perforation, combined therapy) depend in part on the nature of the ventriculocisternal-cyst CSF dynamics. We present eight cases of SSAC, equal to the largest series reported thus far, to emphasize the nature and variability of these pathways. The importance of pretherapeutic evaluation of the CSF dynamics of SSAC is stressed, and guidelines for a diagnostic approach to imaging the CSF pathways are discussed.

TABLE 1: **Classification of CSF Dynamics of Suprasellar Arachnoid Cysts**

Communicating cysts:
Without hydrocephalus
With hydrocephalus:
Extraventricular obstruction (tentorial)
Intraventricular obstruction:
Anterior third-ventricular compression
Foramen-of-Monro block
Aqueductal kinking
Combined obstruction
Noncommunicating cysts:
Without hydrocephalus
With hydrocephalus:
Extraventricular obstruction
Intraventricular obstruction
Combined obstruction

Materials and Methods

Since 1978, eight patients with SSAC have been diagnosed at the hospitals and clinics of the Universities of Iowa and Wisconsin. The demographic data, symptomatology, and conventional computed tomographic (CT) findings of these patients were presented in part 1 of this communication [15]. The initial diagnosis was made in seven patients by CT and in one patient by pneumoencephalography. CT was performed with a Picker 600, GE 8800, Siemens DR3, or EMI 5005 scanner in the axial (seven patients) or coronal (two patients) projection before (five patients) and after (seven patients) intravenous administration of contrast medium.

The CSF dynamics were investigated by various techniques: pneumoencephalography (two patients); pneumoencephalography plus ventriculography (two); ventriculography (one); immediate and delayed metrizamide-enhanced CT ventriculography (two); and immediate and delayed metrizamide-enhanced CT cisternography (one). Table 2 summarizes the CSF dynamics of these patients.

Surgical and pathologic confirmation were available in six cases. The two most recent cases have been treated by shunt decompression alone. Although pathologic documentation is not available in these two cases, the characteristic appearance of SSAC at metrizamide CT ventriculography and cisternography, as well as clinical follow-up, strongly supports the diagnosis.

Illustrative Case Reports

Case 1: Noncommunicating Cyst without Hydrocephalus

A 37-year-old man had a 1-year history of bilateral progressive deterioration of visual acuity and transient episodes of alternating hemisensory loss. There was no history of trauma, meningitis, or subarachnoid hemorrhage. Goldman perimetry and visual evoked responses suggested optic chiasm compression.

CT demonstrated a nonenhancing mass in the chiasmatic part of the suprasellar cistern that displaced the internal carotid arteries laterally. At pneumoencephalography the chiasmatic and infundibular recesses of the third ventricle were displaced posteriorly and superiorly by the cyst. Air did not enter the cyst but passed readily into the normal ventricular system, through the tentorial incisura, and into the supratentorial subarachnoid cisterns.

A right subfrontal craniotomy confirmed an SSAC anterior to the optic chiasm and infundibulum. The lateral, anterior, and inferior walls of the cyst were removed, and the residual cyst was shunted internally into the supratentorial cisterns. Histologic analysis of the cyst wall confirmed an arachnoidal lining. The visual symptoms were significantly improved at follow-up.

Comment.—Most SSAC communicate with the pontine cistern. Communicating cysts, therefore, if small and without significant intraventricular obstruction, may be adequately and safely decompressed by a ventricular shunt. Noncommunicating cysts, even if small, require direct decompression by shunting, resection, or marsupialization. The demonstration of cyst noncommunication by pneumoencephalography was necessary in this patient in order to choose the proper therapy (resection).

Case 2: Noncommunicating Cyst with Partial Extraventricular (Tentorial) and Intraventricular (Foramina of Monro) Obstruction

A 21-year-old woman had severe headaches, amenorrhea, and galactorrhea. Intermittent behavioral abnormalities, suicidal tendencies, and hallucinations had been present since the age of 8 years. Anomalous and possibly atrophic optic disks had been noted at age 16. Visual acuity and neurologic evaluation were normal.

A CT scan confirmed a large, nonenhancing SSAC (figs. 1A and 1B). Pneumoencephalography demonstrated a large prepontine, suprasellar, and third-ventricular mass that severely compressed and displaced the anterior third ventricle upward and to the left (figs. 1C and 1D). Air failed to enter the right lateral ventricle owing to complete obstruction of the foramen of Monro and incompletely filled the left lateral ventricle through a partly obstructed intraventricular foramen. Only a small amount of air passed above the basal cisterns into the supratentorial subarachnoid spaces.

Initial surgery consisted of subtotal resection of the anterior cyst wall and shunting of the cyst remnant into the right atrium. Postoperatively, the cyst decreased in size but the headaches and hydrocephalus persisted (fig. 1E). A ventriculojugular shunt was placed, and the hydrocephalus and residual cyst dilatation resolved (fig. 1F).

Comment.—Despite partial decompression of the cyst by resection and external cyst shunting, hydrocephalus persisted because of the extraventricular (tentorial) block. The necessity of both cyst and ventricular decompression should have been predicted by the nature of the CSF dynamics at pneumoencephalography. Extraventricular obstructive hydrocephalus due to basal arachnoid adhesions is a common cause of therapeutic failure after resection.

TABLE 2: **CSF Dynamics of Eight Suprasellar Arachnoid Cysts**

Case No.	Hydro-cephalus	Cyst Communica-tion	Locations of CSF Obstruction				
			Anterior 3V Compression	Foramen of Monro		Tentorial Incisura	Aqueductal Kinking
				R	L		
1	–	–	–	–	–	–	–
2	+	–	+	C	P	P	–
3	+	+	+	P	P	–	–
4	+	+	+	P	P	P	–
5	+	+	+	P	P	P	P
6	+	+	+	P	P	C	–
7	+	+	+	P	P	C	–
8	+	+	+	C	P	C	–

Note.—3V = third-ventricle; R = right; L = ieft; – = absent; + = present; C = complete; P = partial.

Case 3: Communicating Cyst with Positional Bilateral Foramina of Monro Obstruction

A 13-year-old girl presented at 7 years of age with obesity and possible hypothalamopituitary dysfunction, although multiple subsequent endocrine evaluations revealed no definite abnormality. Three months before admission, she had developed severe headaches (worse in the supine position), temper outbursts, irritability, episodic polydipsia and polyuria, left-sided hyperhidrosis, left-lower-extremity numbness, and decreasing visual acuity. She also developed a characteristic to-and-fro nodding of the head and trunk (bobble-head-doll syndrome), commonly found in patients with SSAC [17–19].

A CT scan revealed a large SSAC that was producing obstructive hydrocephalus. Metrizamide CT cisternography (fig. 2) demonstrated communication of the cyst with the pontine cistern and marked invagination of the cyst into the severely compressed third ventricle. Metrizamide immediately entered the supratentorial cisternal spaces (fig. 2B), excluding a CSF block at the tentorial incisura. Delayed scans, after 5 hr of active head bobbing, revealed partial decompression of the third-ventricular component of the cyst (fig. 2E) and less compression of the foramina of Monro.

Treatment consisted of shunting the lumbar subarachnoid space into the peritoneal cavity, resulting in improvement of the headaches, hyperhidrosis, and bobble-head-doll syndrome.

Comment.—Metrizamide CT cisternography demonstrated intercommunication of the lumbar, infratentorial, and supratentorial subarachnoid spaces with the SSAC as well as partial decompression of the cyst and lateral ventricles with head bobbing. The patency of the entire lumboventriculocisternal-cyst CSF pathway allowed this patient to be treated successfully with a minimally invasive lumboperitoneal shunt.

Case 4: Communicating Cyst with Partial Bilateral Foramina of Monro Obstruction

A 24-year-old man had presented at 2 years of age for evaluation of generalized seizures and a delay in attaining normal developmental milestones. At that time he had an intermittent left-sided limp, stumbling gait, and a "spastic" left left. These symptoms gradually resolved and he was asymptomatic until 3 years before admission, when he developed progressive memory loss, intermittent headaches, and a change in personality. A recurrence of seizures, after being seizure-free for 9 years, led to evaluation with CT.

The CT scan demonstrated an SSAC with invagination into the third ventricle. Metrizamide CT ventriculography was performed after intraventricular injection of 4 ml of metrizamide (170 mg I/ml). Immediate axial and coronal scans (figs. 3A–3D) confirmed the diagnosis of SSAC. The third ventricle was severely compressed and displaced anterosuperiorly. The intraventricular portion of the cyst partly obstructed both foramina of Monro. Delayed (7 hr) CT confirmed communication of the cyst with the subarachnoid spaces (fig. 3E) and slight opacification of the sylvian cisterns.

The SSAC was partly resected and marsupialized into the third ventricle by way of a right frontoparietal craniotomy with a transcortical, transventricular approach to the cyst. A catheter was placed at the time of operation along the operative path into the prepontine remnant of the cyst and connected to a "blind" Rickham reservoir. Hydrocephalus failed to resolve until the blind reservoir was converted into a functioning cystoperitoneal shunt 9 days later.

Comment.—In the presence of a basal cisternal CSF block, marsupialization or cystoventricular shunting of a communicating SSAC may be unsuccessful. Although CSF can flow freely from the outlets of the fourth ventricle into the cyst and then back into the ventricular system, it cannot pass over the cerebral convexities to be absorbed by the arachnoid granulations. A communicating SSAC can be treated effectively, however, by internal shunting/marsupialization of the cyst into the supratentorial cisterns or by cystoperitoneal shunting. These procedures allow decompression of both the cyst and the ventricular system, since the basal cisternal block is effectively bypassed. The minimal opacification of the sylvian cisterns on delayed metrizamide CT ventriculography in this patient indicated a partial basal cisternal block and predicted the failure of the initial treatment. Adequate cyst and ventricular decompression required cystoperitoneal shunting.

Case 6: Communicating Cyst with Partial Intraventricular (Foramina of Monro) and Extraventricular Obstructive Hydrocephalus

An 11-year-old boy had presented at 6 months of age with bulging fontanelles and an increased head circumference. Pneumoencephalography demonstrated a patent aqueduct, enlarged "third" and lateral ventricles, and a basal tentorial CSF block. A right ventriculoperitoneal shunt was placed for supposed communicating hydrocephalus. He continued to be neurologically and intellectually normal for the next 10 years, although multiple shunt revisions were necessary for "malfunctioning" shunts. A CT scan was obtained at 11 years of age for evaluation of an episode of acute hydrocephalus.

The CT scan revealed changes typical of an SSAC. Metrizamide CT ventriculography, performed after placement of 4 ml of metrizamide (170 mg I/ml) into the right ventricular shunt (fig. 4), demonstrated partial bilateral foramen-of-Monro obstruction as well as severe compression and upward displacement of the anterior third ventricle.

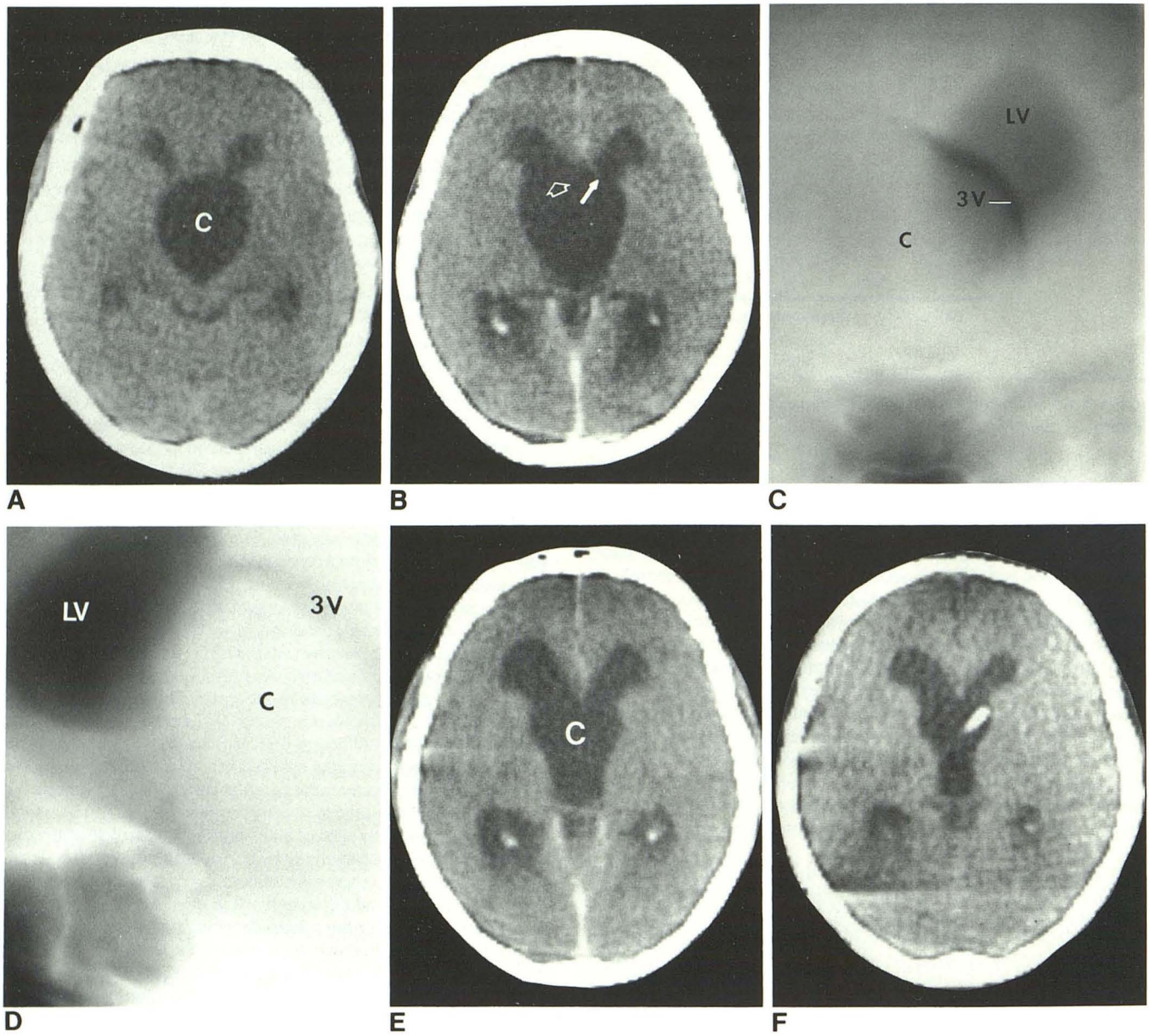

Fig. 1.—Case 2: 21-year-old woman with noncommunicating SSAC. **A** and **B**, CT scans. Large SSAC (C) has invaginated into third ventricle. Mild hydrocephalus due to obstruction of intraventricular foramina. Right foramen of Monro (**B,** *open arrow*) is widened secondary to invagination of cyst into right lateral ventricle. Septum pellucidum (*solid arrow*) is displaced to left. Anteroposterior (**C**) and lateral (**D**) radiographs from pneumoencephalogram reveal large SSAC causing severe compression and upward displacement of third ventricle (3V). There is complete obstruction of right foramen of Monro. Left lateral ventricle (LV) filled through a partly obstructed foramen of Monro. Air did not enter SSAC and did not fill supratentorial cisterns because of tentorial CSF block. **E**, CT scan after partial resection of SSAC. Substantial decompression of cyst, but persistence of hydrocephalus secondary to tentorial CSF block. **F**, After ventricular shunting. Further decompression of cyst and improvement of hydrocephalus.

The aqueduct and fourth ventricle were posteriorly displaced but patent. Delayed (6 hr) CT demonstrated entry of metrizamide into the cyst but not into the supratentorial cisterns.

Comment.—Because of severe intraventricular CSF obstruction, the ventricular shunt did not adequately decompress the communicating cyst or the contralateral left lateral ventricle. Proper therapy requires either an additional shunt (lumboperitoneal or cystoperitoneal) or resection of the cyst itself.

Case 8: Communicating Cyst with Extraventricular (Tentorial Block) and Intraventricular (Bilateral Foramina of Monro) Obstructive Hydrocephalus

An 8-month-old boy had presented with acute onset of nausea, vomiting, craniomegaly, and seizures 2 weeks after a febrile illness. A CT scan at an outside hospital (fig. 5A) revealed enlarged "third" and lateral ventricles, thought to be secondary to aqueductal steno-

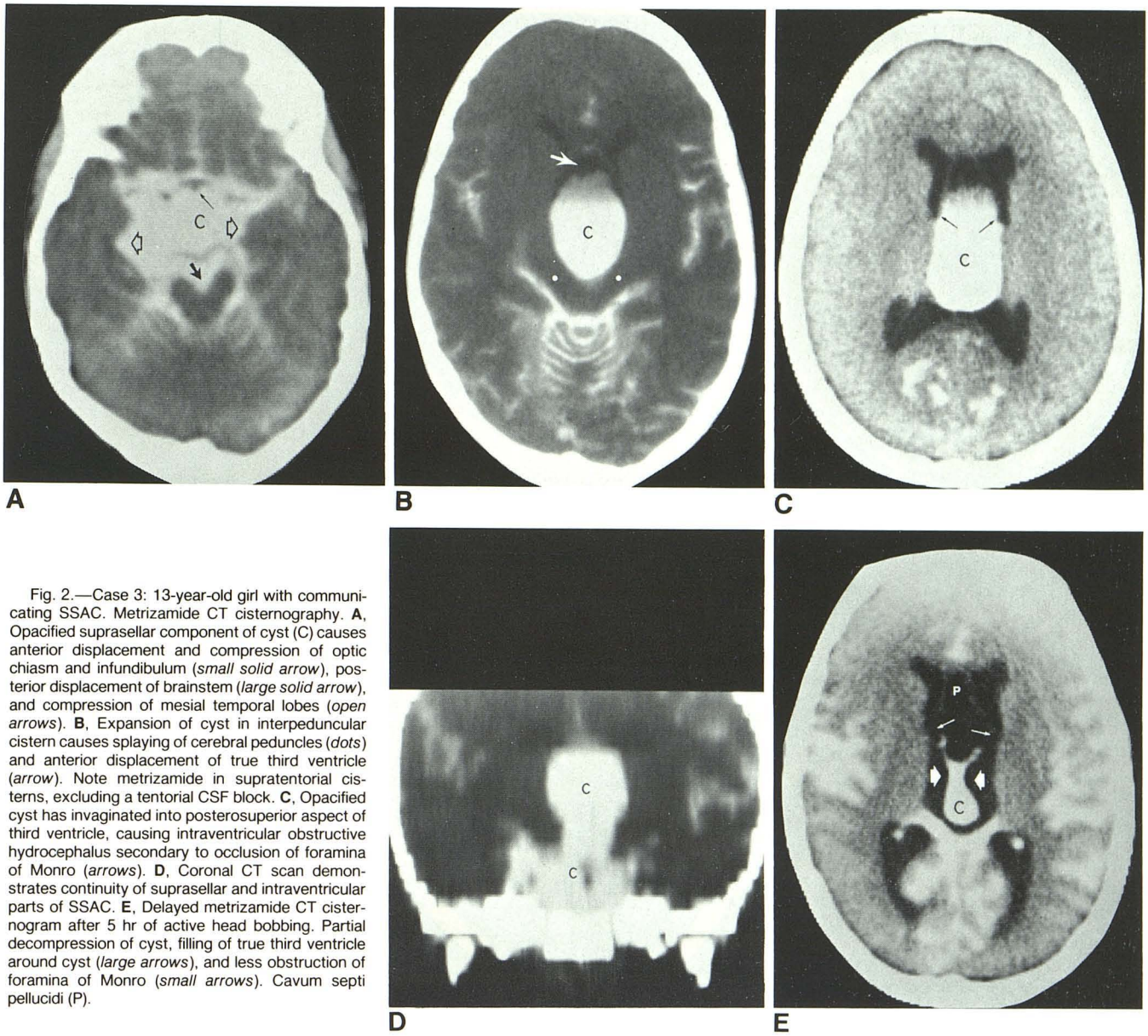

Fig. 2.—Case 3: 13-year-old girl with communicating SSAC. Metrizamide CT cisternography. **A**, Opacified suprasellar component of cyst (C) causes anterior displacement and compression of optic chiasm and infundibulum (*small solid arrow*), posterior displacement of brainstem (*large solid arrow*), and compression of mesial temporal lobes (*open arrows*). **B**, Expansion of cyst in interpeduncular cistern causes splaying of cerebral peduncles (*dots*) and anterior displacement of true third ventricle (*arrow*). Note metrizamide in supratentorial cisterns, excluding a tentorial CSF block. **C**, Opacified cyst has invaginated into posterosuperior aspect of third ventricle, causing intraventricular obstructive hydrocephalus secondary to occlusion of foramina of Monro (*arrows*). **D**, Coronal CT scan demonstrates continuity of suprasellar and intraventricular parts of SSAC. **E**, Delayed metrizamide CT cisternogram after 5 hr of active head bobbing. Partial decompression of cyst, filling of true third ventricle around cyst (*large arrows*), and less obstruction of foramina of Monro (*small arrows*). Cavum septi pellucidi (P).

sis. A right lateral ventricular shunt was placed for acute hydrocephalus, but symptoms persisted. A repeat CT scan 6 weeks later (fig. 5B) revealed decompression of the right lateral ventricle but paradoxical enlargement of the "third" and left lateral ventricles, indicating obstruction of the foramina of Monro.

A ventriculogram (fig. 5C) confirmed obstruction of the left foramen of Monro by the large anterior third-ventricular mass. Pneumoencephalography (fig. 5D) showed that the mass was a communicating SSAC that had invaginated into the third ventricle, displacing it anteriorly and superiorly. Air did not enter the supratentorial cisterns at pneumoencephalography.

A pterional, subfrontal craniotomy confirmed a SSAC involving the prepontine, interpeduncular, and suprasellar cisterns with invagination into the anterior aspect of the third ventricle. Substantial portions of the cyst wall (anterior, lateral, and posterior) were removed and communication with the sylvian fissure established. The previously inserted ventriculoperitoneal shunt was left in place.

Comment.—This case demonstrates that, in the presence of significant intraventricular obstruction, a ventricular shunt will not adequately decompress a communicating cyst. The demonstration of significant intraventricular obstruction indicates that a second, infratentorial, cisternal shunt or treatment of the cyst itself (resection/marsupialization/shunting) will be required.

Discussion

Variations in CSF Dynamics and Methods of Diagnostic Evaluation

SSAC generally cause symptoms as a result of obstructive hydrocephalus (intraventricular or extraventricular) or from

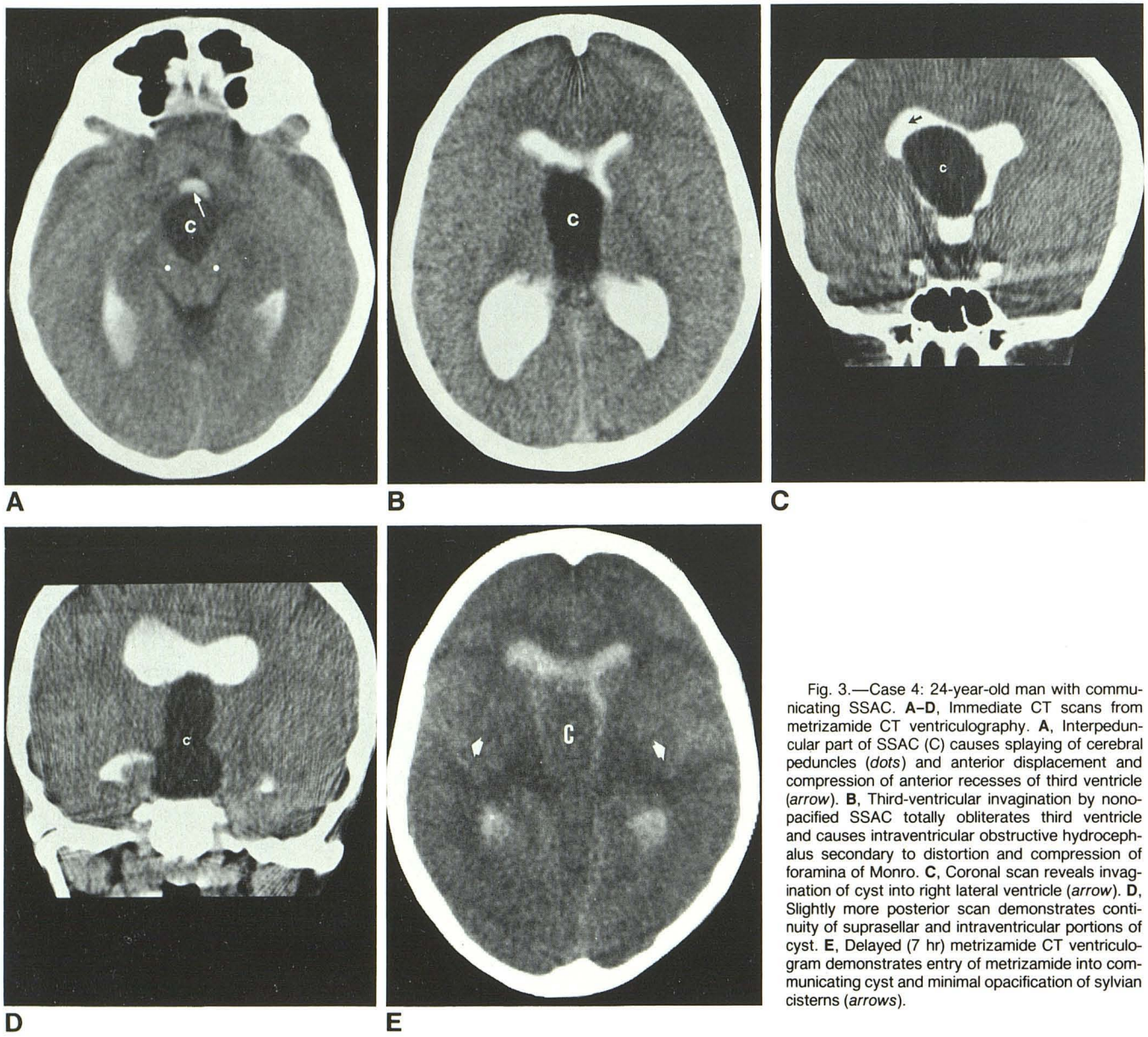

Fig. 3.—Case 4: 24-year-old man with communicating SSAC. **A–D**, Immediate CT scans from metrizamide CT ventriculography. **A**, Interpeduncular part of SSAC (C) causes splaying of cerebral peduncles (*dots*) and anterior displacement and compression of anterior recesses of third ventricle (*arrow*). **B**, Third-ventricular invagination by nonopacified SSAC totally obliterates third ventricle and causes intraventricular obstructive hydrocephalus secondary to distortion and compression of foramina of Monro. **C**, Coronal scan reveals invagination of cyst into right lateral ventricle (*arrow*). **D**, Slightly more posterior scan demonstrates continuity of suprasellar and intraventricular portions of cyst. **E**, Delayed (7 hr) metrizamide CT ventriculogram demonstrates entry of metrizamide into communicating cyst and minimal opacification of sylvian cisterns (*arrows*).

direct compression of the optic chiasm, hypothalamopituitary axis, cerebral peduncles, thalamus, brainstem, or temporal lobes by the expanding cyst [1, 2, 15–18]. Optimal treatment requires decompression both of the ventricular system, to relieve hydrocephalus, and of the cyst, to relieve neural compression [12, 14, 15]. The best method for ventricular and cyst decompression, however, remains controversial. Raimondi et al. [10] recently reviewed the effectiveness of alternative methods of treatment and stressed the difficulty encountered in predicting outcome. Failure of adequate decompression of the cyst and associated hydrocephalus with initial treatment has been a common occurrence, and multiple operative procedures often have been necessary. Unsuccessful initial treatment may occur with ventriculoperitoneal shunting [12, 13, 16, 18], intraventricular shunting or marsupialization of the cyst [1, 7, 17], subarachnoid shunting or marsupialization of the cyst [1, 2], and resection of the cyst wall [1, 3, 7, 9, 10, 17]. Our experience with eight cases of SSAC and our review of the literature suggest that, in most instances, unsuccessful treatment is usually attributable to failure to investigate or to consider adequately the complex CSF dynamics before surgery. Initial treatment failure was predictable, in many cases, by the CSF dynamics.

Before the advent of CT, most of these cysts were preoperatively evaluated with pneumoencephalography, or ventriculography. These studies also provided valuable information about the CSF dynamics [5, 8, 9, 14, 18]. More recently, the diagnosis usually has been made by conventional CT; thus,

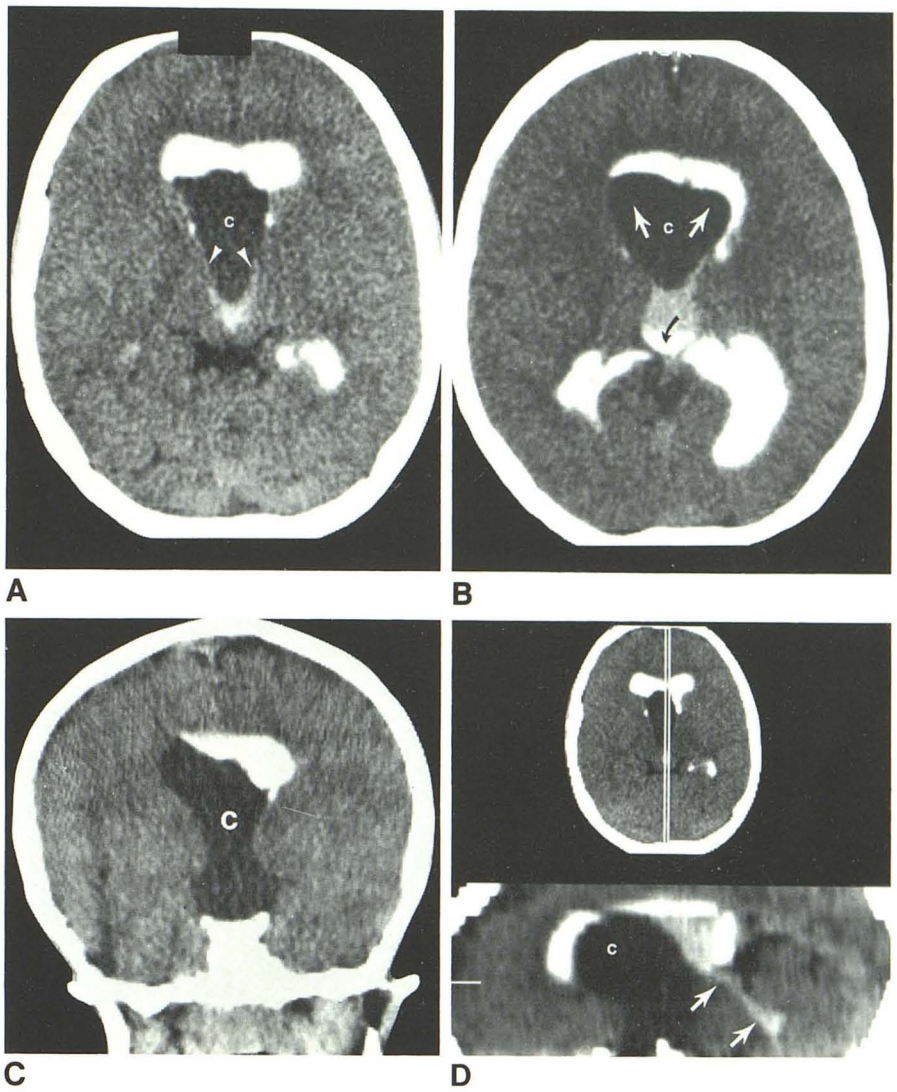

Fig. 4.—Case 6: 11-year-old boy with communicating SSAC producing intraventricular and extraventricular obstructive hydrocephalus. **A**, After placement of metrizamide into right lateral ventricle, metrizamide CT ventriculography demonstrates entry of contrast material into left lateral and third ventricles through partly obstructed foramina of Monro. The slitlike remnant of severely compressed third ventricle (*arrowheads*) fills around intraventricular portion of unopacified cyst (C). **B**, At higher level. Invagination of cyst into lateral ventricles through markedly widened interventricular foramina (*white arrows*). Opacification of disproportionately small suprapineal recess of third ventricle (*curved arrow*) excludes complete obstruction of third ventricle. **C**, Coronal scan illustrates suprasellar, third ventricular, and lateral ventricular components of cyst. **D**, Sagittal reformation demonstrates predominant invagination of cyst into anterior third ventricle as well as patent, but posteriorly displaced, aqueduct and fourth ventricle (*arrows*). Delayed scans (not shown) confirmed entry of metrizamide into cyst but not into supratentorial CSF cisterns.

less information is available about the CSF dynamics. Even in the CT era, however, evaluation of CSF dynamics remains of great importance because of the implications regarding selection of proper treatment. Several authors have emphasized the limitations of conventional CT in diagnostic evaluation of SSAC [1–5]. These reports have illustrated the value of metrizamide CT ventriculography for confirmation of the diagnosis and evaluation of obstruction of the intraventricular foramina. Metrizamide CT cisternography has been valuable for assessment of CSF dynamics of arachnoid cysts in other locations [20, 21].

In order to plan the most effective treatment with the least operative risk, diagnostic evaluation should include determination of cyst communication with the subarachnoid space; identification of the presence, location, and severity of intraventricular CSF obstruction; and detection of basal or tentorial (extraventricular) CSF block.

Cyst communication.—Some authors have emphasized the rarity of communication of SSAC with the subarachnoid space [3, 8, 9, 17]. In our experience, however, the majority of SSAC do communicate. Three of five patients studied with air and all three patients studied with metrizamide revealed communication of the cysts with the pontine cisterns. SSAC do not communicate directly with the ventricular system unless spontaneous intraventricular rupture has occurred. We believed metrizamide CT cisternography to be the most reliable method for determining communication of the cyst with the subarachnoid space. This technique is probably more accurate than pneumoencephalography, since a partly obstructed communicating cyst will fill more readily with metrizamide than with air.

The demonstration of cyst communication is also possible, but much more difficult, with metrizamide CT ventriculography. Most commonly, SSAC present with third-ventricular invagination, which can cause severe compression of the anterior third ventricle, obstruction of the foramina of Monro,

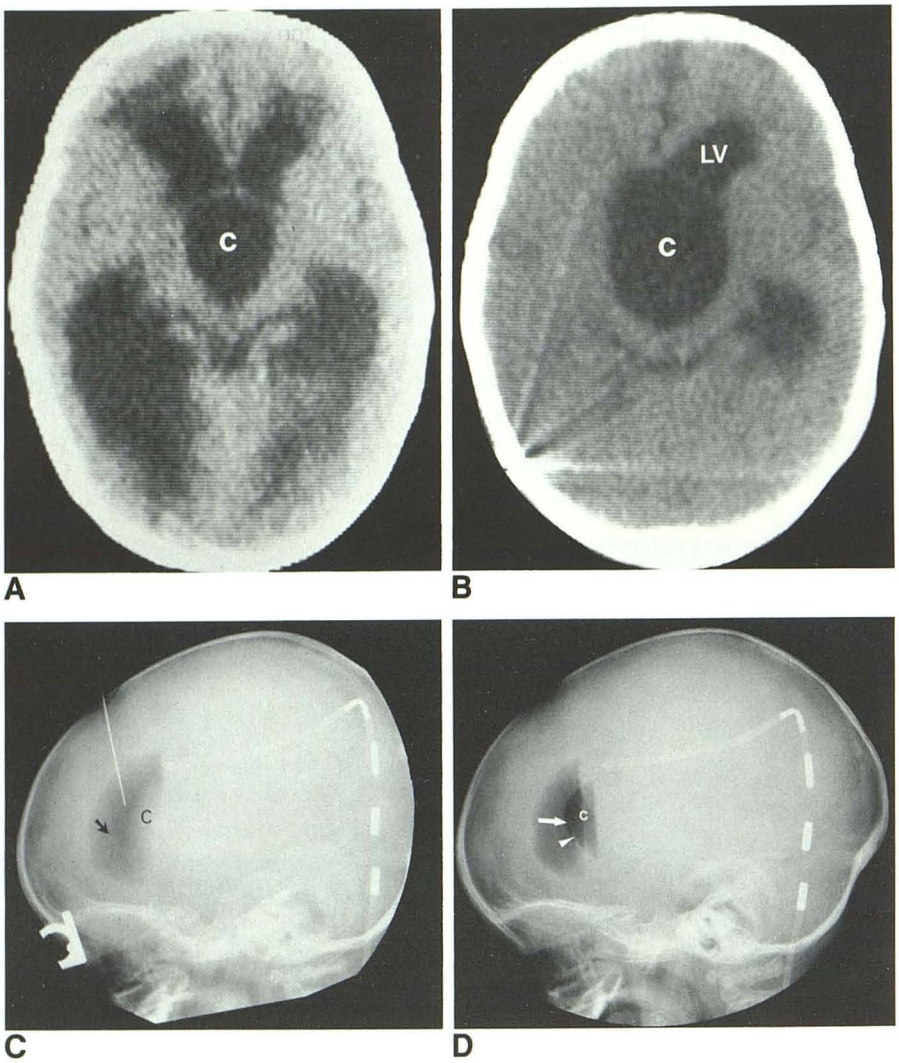

Fig. 5.—Case 8: 8-month-old boy with communicating SSAC producing intraventricular and extraventricular obstructive hydrocephalus. **A**, CT scan reveals large midline SSAC (C) causing obstructive hydrocephalus. **B**, After placement of right ventriculoperitoneal shunt. Complete decompression of right lateral ventricle. Obstruction of foramina of Monro by cyst prevents decompression of both left lateral ventricle (LV) and communicating SSAC by right ventricular catheter. **C**, Air introduced into left lateral ventricle (*arrow*) outlines dome of intraventricular component of cyst. Air initially fails to enter severely compressed third ventricle. **D**, Brow-up pneumoencephalogram demonstrates entry of air into communicating SSAC. A small amount of air has now passed through nearly occluded left foramen of Monro to enter severely compressed, slitlike anterior third ventricle (*arrow*). Anterior wall of cyst (*arrowhead*) is visible as a thin "web" between cyst and third ventricle. Air does not enter supratentorial cisterns because of a tentorial CSF block.

or aqueductal kinking. Intraventricular obstruction can prevent the passage of metrizamide (or air) through the ventricular system, preventing its entry into the pontine cistern and cyst. Delayed metrizamide CT ventriculography was helpful, however, in demonstrating communication of the cyst with the subarachnoid space in two of our patients (fig. 3).

Intraventricular CSF obstruction.—In the eight patients of our series, intraventricular obstruction usually was secondary to severe anterior third-ventricular compression and foramina-of-Monro obstruction. Obstruction of the intraventricular foramina was usually partial and bilateral but occasionally complete or positional (case 3). The location of the site of intraventricular obstruction often was suggested by the appearance of the third and lateral ventricles on conventional CT [15], but was evaluated more accurately by metrizamide CT ventriculography. This study accurately revealed the severity of anterior third-ventricular compression and the degree of foramina-of-Monro obstruction in two of our patients (figs. 3 and 4). Air ventriculography therefore seems to be no longer necessary.

Metrizamide CT cisternography is less reliable then metrizamide CT ventriculography for evaluation of intraventricular obstruction. Unless the ventricular system or the cyst opacifies, the sites and severity of obstruction cannot be accurately evaluated. The severity of intraventricular obstruction can be assessed directly with metrizamide CT cisternography if the aqueduct and ventricular system fill with metrizamide. If the cyst opacifies, the severity of intraventricular obstruction can be estimated indirectly by the degree of distortion of the aqueduct, foramina of Monro, and the third ventricle by the cyst.

Extraventricular CSF obstruction.—Determination of the presence or absence of extraventricular CSF obstruction (tentorial block) should also be made. A ventriculoperitoneal shunt will be required in addition to cyst resection if there is a significant tentorial block. Harrison [14] has noted a high

frequency of extraventricular CSF obstruction as the cause of persistent hydrocephalus after resection of SSAC. The most accurate and direct method of evaluating patency of the infratentorial to supratentorial cisternal pathways is by metrizamide CT cisternography. Immediate and marked opacification of supratentorial cisterns excludes a significant tentorial block (fig. 2). Delayed scanning at metrizamide CT ventriculography is less reliable, especially in the presence of partial intraventricular obstruction.

Diagnostic Approach to Evaluation of CSF Dynamics

Patients with SSAC typically present with one of two major symptom complexes. Predominant symptoms may be related to neural compression by the cyst or to associated obstructive hydrocephalus. We recommend a diagnostic approach to the evaluation of CSF dynamics on the basis of which of these two symptom complexes predominates.

Predominant compressive neurologic symptoms.—The most crucial diagnostic information for directing proper therapy in these patients is the determination of whether the cyst communicates with the subarachnoid space. The best method of cyst decompression to relieve neural symptoms can be determined only in light of this knowledge. If SSAC communicate freely with the infratentorial and lumbar subarachnoid spaces, they may be decompressed safely and effectively by a lumboperitoneal or infratentorial cisternoperitoneal shunt (case 3). Treatment of noncommunicating cysts requires direct decompression by resection, marsupialization, or shunting (cases 1 and 2).

In patients with predominantly compressive symptomatology, we believe metrizamide CT cisternography to be the most accurate and reliable means of determining cyst communication and the initial diagnostic study of choice for evaluation of the CSF dynamics. We have not experienced any problems, nor are we aware of any reports in the literature, of neurologic deterioration after lumbar puncture in patients with compressive symptoms secondary to SSAC. The intrathecal placement of metrizamide through a 22-gauge needle seems to be quite safe. If hydrocephalus is very marked or acute, it may be advisable to wait until ventricular shunting has been performed before proceeding with metrizamide CT cisternography. Scanning should be performed immediately after the intrathecal metrizamide has been run into the infratentorial subarachnoid space. Immediate opacification of the cyst with metrizamide confirms cisternal communication of the cyst. Noncommunicating cysts, however, will appear as CSF density masses in the suprasellar, prepontine, and third-ventricular regions surrounded by the compressed, opacified subarachnoid space [11, 20, 21]. Delayed metrizamide CT cisternography may be necessary in some instances to document cyst communication [11, 20, 21].

Metrizamide CT cisternography often can provide the necessary information about the location(s) of CSF obstruction. Immediate passage of metrizamide into the supratentorial cisterns confidently and most accurately excludes an associated extraventricular block at the level of the suprasellar cisterns. If the cyst opacifies, the severity and location of intraventricular CSF obstruction often can be indirectly estimated by the degree of distortion of the third ventricle and foramina of Monro by the cyst. If the cyst is noncommunicating, metrizamide CT ventriculography may be necessary to accurately reveal the severity of intraventricular obstruction.

Predominant hydrocephalic symptoms.—The most valuable diagnostic information in these patients is accurate determination of the severity and sites of intraventricular obstruction. Urgent ventricular shunting is often required in some of these patients to relieve their symptoms of acute hydrocephalus. Metrizamide CT ventriculography should be the initial diagnostic study of the CSF dynamics in these patients, since metrizamide can be instilled directly through the shunt catheter. It is important to determine the severity of compression of the foramina of Monro in these patients, since the ventricular shunt will not decompress the ventricular system or the cyst in the presence of severe foramina-of-Monro obstruction. In some instances the hydrocephalic symptoms may even become more severe owing to paradoxical expansion of the cyst and the rest of the ventricular system (fig. 5).

In many cases it may be possible to determine whether a significant CSF block is present at the tentorial incisura by delayed metrizamide CT ventriculography. Significant opacification of the supratentorial cisterns with metrizamide on delayed scans excludes this possibility (fig. 3). Metrizamide CT cisternography may be necessary to evaluate basal cisternal obstruction if delayed metrizamide CT ventriculography is equivocal.

Delayed metrizamide CT ventriculography may be useful also for determination of cyst communication with the subarachnoid space. Significant opacification of the cyst after exit of metrizamide from the fourth ventricle suggests cyst communication. In some cases it may be difficult to determine whether contrast within the cyst entered by the cisternal route or by diffusion across the cyst wall unless sequential delayed scans are obtained or the opacification is great. For this reason we believe metrizamide CT cisternography should also be performed when metrizamide CT ventriculography is equivocal, especially if the method of treatment would be altered by the findings.

Therapeutic Implications of Misdiagnosis of SSAC

We believe that unfamiliarity with the etiology, mechanism of formation and expansion, and neuroradiographic features of SSAC have led to much confusion in the literature regarding SSAC and ependymal cysts of the third ventricle. Although true ependymal cysts of the third ventricle undoubtably exist [22], we suspect that most of those reported in the literature are, in fact, SSAC that have invaginated into the third ventricle.

The exact frequency of true third-ventricle ependymal cysts is difficult to determine because of incomplete surgical and pathologic descriptions in many reports. The assertion that many ependymal cysts are actually SSAC is based on several observations: (1) Many ependymal cysts are described as

communicating with the pontine cistern but not with the third ventricle [7, 14, 23]. A true intraventricular ependymal cyst should not communicate with the subarachnoid space. (2) Most are associated with expansion of the pontine and interpeduncular cisterns as well as posterior displacement of the brainstem and basilar artery [7, 14, 23]. This complex should not occur with true third-ventricular cysts. They would be expected to expand within, and conform to the shape of, the third ventricle and should not be associated with a prepontine component. (3) "Ependymal" cysts of the third ventricle are invariably described as arising from the floor of the anterior third ventricle with a broad-based attachment to the hypothalamus [7, 14, 23, 24]. (4) The pathologic diagnosis is more likely to be "ependymal cyst" when the operative approach is through the ventricular system (e.g., transcallosal, transcortical-intraventricular, via the cistern of the lamina terminalis) or when the superior and anterior aspects of the cysts are resected [7, 14, 23, 24]. This is because the specimen submitted for histologic analysis usually contains the adherent wall of the cyst, the thinned hypothalamus, and the ependymal surface of the floor of the third ventricle [24]. The correct diagnosis can be achieved only if care is taken to indicate the inner wall of the cyst [11]. We consider any histologic diagnosis of ependymal cysts of the third ventricle inconclusive, unless the biopsy was obtained away from the region of intraventricular invagination or unless the inner wall of the cyst was specifically identified.

The therapeutic consequences of misidentification of SSAC as ependymal cysts are obvious. Extensive resection of the dome of an SSAC within the third ventricle results in simultaneous removal of the firmly adherent, but upwardly displaced and thinned, hypothalamus. Therefore, it is not surprising that transient or persistent diabetes insipidus commonly accompanies extensive surgical resection of SSAC [1, 10]. For these reasons, if an ependymal cyst of the third ventricle is a diagnostic consideration, we recommend preoperative metrizamide CT cisternography to exclude an SSAC with intraventricular invagination.

REFERENCES

1. Hoffman HJ, Hendrick EB, Humphreys RP, Armstrong EA. Investigation and management of suprasellar arachnoid cysts. *J Neurosurg* **1982**;57:597–602
2. Armstrong EA, Harwood-Nash DCF, Hoffman H, Fitz CR, Chuang S, Pettersson H. Benign suprasellar cysts: the CT approach. *AJNR* **1983**;4:163–166
3. Leo JS, Pinto RS, Hulvat GF, Epstein F, Kricheff II. Computed tomography of arachnoid cysts. *Radiology* **1979**;130:675–680
4. Murali R, Epstein F. Diagnosis and treatment of suprasellar arachnoid cyst: report of 3 cases. *J Neurosurg* **1979**;50:515–518
5. Kishore PRS, Krishna Rao CVG, Williams JP, Vines FS. The limitation of computerized tomographic diagnosis of intracranial midline cysts. *Surg Neurol* **1980**;14:417–431
6. Sansregret A, Ledoux R, Duplantis F, Lamoureux C, Chapdelaine A, Leblanc P. Suprasellar subarachnoid cysts: radioclinical features. *AJR* **1969**;105:291–297
7. Fox JL, Al-Mefty O. Suprasellar arachnoid cysts: an extension of the membrane of Liliequist. *Neurosurgery* **1980**;7:615–618
8. Schimmel DH, Weinstein M. Suprasellar subarachnoid cysts. *Neuroradiology* **1976**;11:141–146
9. Grollmus JM, Wilson CB, Newton TH. Paramesencephalic arachnoid cysts. *Neurology* **1976**;26:128–134
10. Raimondi AJ, Shimoji T, Gutierrez FA. Suprasellar cysts: surgical treatment and results. *Childs Brain* **1980**;7:57–72
11. Binitie D, Williams B, Case CP. A suprasellar subarachnoid pouch: aetiological considerations. *J Neurol Neurosurg Psychiatry* **1984**;47:1066–1074
12. Lee BCP. Intracranial cysts. *Radiology* **1979**;130:667–674
13. Gonzalez CA, Villarejo FJ, Blazquez MG, Castroviejo IP, Higueras AP. Suprasellar arachnoid cysts in children: report of 3 cases. *Acta Neurochir* (Wien) **1982**;60:281–296
14. Harrison MJG. Cerebral arachnoid cysts in children. *J Neurol Neurosurg Psychiatry* **1971**;34:316–323
15. Gentry LR, Smoker WRK, Turski PA, Menezes AH, Ramirez L, Cornell SH. Suprasellar arachnoid cysts: 1. CT recognition. *AJNR* **1986**;7:79–86
16. Cilluffo JM, Onofrio BM, Miller RH. The diagnosis and surgical treatment of intracranial arachnoid cysts. *Acta Neurochir* (Wien) **1983**;67:215–229
17. Benton JW, Nellhaus G, Huttenlocher PR, Ojemann RG, Dodge PR. The bobble-head doll syndrome. Report of a unique truncal tremor associated with third ventricular cyst and hydrocephalus in children. *Neurology* **1966**;16:725–729
18. Segall HD, Hassan G, Ling SM, Carton C. Suprasellar cyst associated with isosexual precocious puberty. *Radiology* **1974**;111:607–616
19. Miller JH, Pena AM, Segall HD. Radiological investigation of sellar region masses in children. *Radiology* **1980**;134:81–87
20. Ruscalleda J, Guardia E, dos Santos FM, Carvajal A. Dynamic study of arachnoid cyst with metrizamide. *Neuroradiology* **1980**;20:185–189
21. Wolpert SM, Scott RM. The value of metrizamide CT cisternography in the management of cerebral arachnoid cysts. *AJNR* **1981**;2:29–35
22. Giudicelli G, Hassoun J, Choux M, Tonon C. Supratentorial "arachnia" cysts. *J Neuroradiol* **1982**;9:179–201
23. Servo A, Porras M, Jaaskinen J. Diagnosis of ependymal intraventricular cysts of the third ventricle by computed tomography. *Neuroradiology* **1983**;24:155–157
24. Krawchenko J, Collins GH. Pathology of an arachnoid cyst: case report. *J Neurosurg* **1979**;50:224–228