Are your MRI contrast agents cost-effective?
Learn more about generic Gadolinium-Based Contrast Agents.
FRESENIUS KABI
caring for life

AJNR

Magnetic resonance imaging of small medullary infarctions.

A J Fox, J Bogousslavsky, L S Carey, H J Barnett, S Vinitski, S J Karlik, F Viñuela, D M Pelz and V Hachinski

AJNR Am J Neuroradiol 1986, 7 (2) 229-233
http://www.ajnr.org/content/7/2/229

This information is current as of April 19, 2024.

Magnetic Resonance Imaging of Small Medullary Infarctions

Allan J. Fox[1,2]
Julien Bogousslavsky[2]
Lewis S. Carey[1]
Henry J. M. Barnett[2]
Simon Vinitski[1]
Stephen J. Karlik[1,3]
Fernando Viñuela[1,2]
David M. Pelz[1,2]
Vladimir Hachinski[2]

Small infarctions of the medulla produce typical neurologic deficits and can be clinically recognized fairly reliably. High-field magnetic resonance imaging with a 1.5 T prototype scanner successfully demonstrated very tiny medulla infarctions in three of five patients. These lesions were imaged readily by a fairly rapid (approximately 1–2 min scan time) partial-saturation technique and confirmed on multiple spin-echo images. In addition, in two cases vertebral occlusion ipsilateral to the infarction was suggested by high signal on T2 weighted spin-echo images.

Infarctions in small areas of the medulla produce typical neurologic deficits [1, 2]. The specific anatomic location of such a localized medullary infarction can be suggested quite confidently on the basis of specific neurologic findings. Normally, clinical anatomic verification in specific cases has not been available; in vivo imaging has been unreliable and many of these patients recover reasonably well so that neuropathologic verification is not available. CT scans in this region cannot produce good anatomic detail because of bone-hardening artifacts.

Magnetic resonance imaging (MRI) does not have artifacts like CT does, and it is the ideal imaging approach in the posterior fossa [3–8]. Infarctions in the brainstem have been demonstrated with low-field magnetic imagers [3, 4, 9, 10] including one case in the lateral medulla [3]. We report the results of an attempt to demonstrate small medulla infarctions using a 1.5 T imager.

Subjects and Methods

Five patients who had some recovery from localized medulla infarctions clinically were studied on a 1.5 T MRI scanner. Four of these had clinical evidence for lateral medullary infarction and one for medial medullary infarction. These patients had been evaluated and cared for at University Hospital, London, Ontario, during their acute phase, and they were reevaluated at the time of the MRI study 1–39 months later (mean, 16 months). Four of these patients had had CT (GE 8800) during the acute phase, and all had unenhanced CT follow-up at the time of the MRI studies. The CT slices were 5 mm thick and were obtained through the posterior fossa. Four of the CT scans were obtained along the radiographic baseline to anatomically compare with MR scans obtained in the same way. In one patient, the CT scan was obtained 20° from the baseline in the usual CT format. Two patients underwent cerebral angiography by arterial catheterization, and one had digital intravenous angiography.

MR images were obtained using the prototype 1.5 T imager at GE NMR Center, Milwaukee. The primary technique was a single and multislice partial-saturation (PS) recovery sequence with a repetition time (TR) of 300–600 msec, generally using a 128 × 256 matrix and one to two averages. Using such sequences, the scan time was 1–2 min. Consecutive 5 mm slices were obtained in an axial projection through the brainstem, either by single-slice acquisition or by interleaved multislice acquisition. In areas of specific interest additional SE sequences were performed using a TR of 2 sec and echo times (TEs) of 25, 50, 75, and 100 msec. Midline sagittal slices were obtained initially as scout images, and additional coronal and sagittal slices were obtained as well in selective instances.

Received April 4, 1985; accepted after revision July 5, 1985.

J. Bogousslavsky is on leave from the Centre Hospitalier Universitaire Vaudois, Lausanne, Switzerland.

[1] Department of Diagnostic Radiology, University of Western Ontario, London, Ontario, Canada N6A 5A5. Address reprint requests to A. J. Fox, University Hospital, P.O. Box 5339, Postal Stn. "A," London, Ontario, Canada N6A 5A5.

[2] Department of Clinical Neurological Science, University of Western Ontario, London, Ontario, Canada N6A 5A5.

[3] Department of Biophysics, University of Western Ontario, London, Ontario, Canada N6A 5A5.

AJNR 7:229–233, March/April 1986
0195–6108/86/0702–0229
© American Society of Neuroradiology

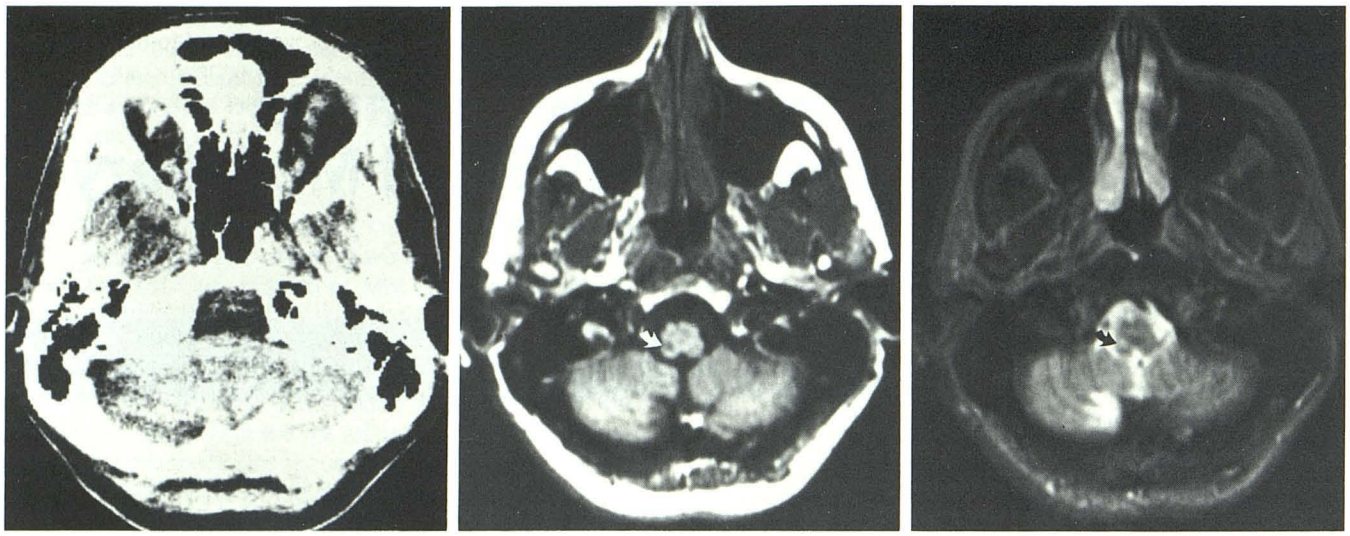

A B C

Fig. 1.—50-year-old woman with moderate recovery from right lateral medulla infarction 17 months earlier. Angiography showed intracranial right vertebral occlusion. **A**, Unenhanced CT scan through medulla. Beam-hardening artifacts. **B**, PS scan, 300 msec TR. Low signal suggests prolonged T1 in medulla infarction (*arrow*). **C**, SE scan, 2 sec TR, 75 msec TE. High signal suggests prolonged T2 in infarction (*arrow*).

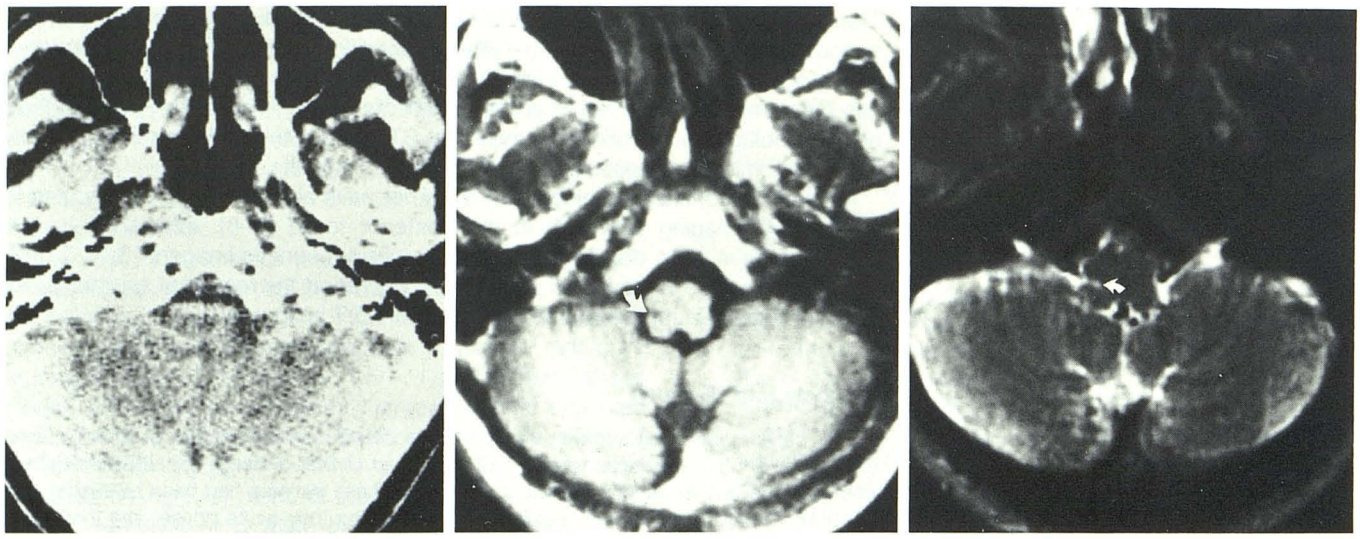

A B C

Fig. 2.—64-year-old woman who had good recovery from right lateral medulla infarction 14 months earlier. **A**, Unenhanced CT scan. Beam-hardening artifacts. **B**, PS scan, TR 300 msec. Infarction is area suggesting prolonged T1 (*arrow*). **C**, SE scan, 2 sec TR, 100 msec TE. High signal suggests prolonged T2 in infarction (*arrow*).

Results

In all five cases with medullary infarctions, the CT scans (figs. 1A and 2A) showed artifacts through the lower brainstem. The expected infarction was imaged by MRI in three cases: two lateral medulla infarctions (figs. 1B, 1C, 2B, and 2C) and one medial medulla infarction (figs. 5A and 5C). The areas of infarction were seen in the expected region as low signal suggesting prolonged T1 on PS scans and high signal suggesting prolonged T2 on SE studies. In two cases the PS scans (figs. 3 and 4A) failed to show a definitely abnormal signal in the expected region, and SE studies were also not definitive. In two cases, absence of signal void in the region of the vertebral artery on SE studies (figs. 4B, 4C, 5B, and 5D) suggested vertebral occlusion, which was confirmed angiographically in one case.

Discussion

One patient with lateral medulla infarction was imaged previously with low-field MRI [3], although other authors have been unable to demonstrate lateral medullary lesions [9]. The identification of small lesions such as lacunar infarction can be a problem, especially if the slice thickness is large [5]. Thin sections are useful, but an improved signal-to-noise ratio is required; this can be accomplished by either increased signal averaging or using a scanner of high magnetic strength [6] or both.

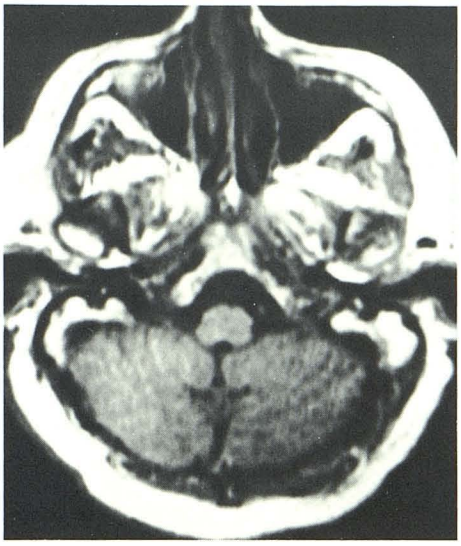

Fig. 3.—67-year-old man who had good recovery from left lateral medulla infarction 39 months earlier. PS scan, 300 msec TR, failed to demonstrate infarction. Additional SE sequences in coronal projection (not shown) were noisy. Infarction was not demonstrated definitively.

In three of our five cases, the very small medullary infarctions, two lateral and one medial, clinically present were well seen as areas of low signal suggesting prolonged T1 on the PS images. The sequences for these T1-weighted images require only 1 or 2 min of scanning and yield good anatomic clarity. Confirmation of these lesions was obtained by additional SE sequences, following with the approach that a genuine lesion can be considered if abnormal signals are reproducible on multiple pulse sequence images [5]. In the two cases in which the PS images failed to show the expected lateral medullary infarction, it is uncertain as to the cause. Those two patients may actually have had smaller anatomic lesions than the other patients. They recovered sooner than the other three patients, 2 weeks and 3 months, as opposed to 8 months and 10 months. The infarctions in those cases, if smaller, may have been lost in the partial-volume averaging of the 5-mm-thick slices [5, 6]. Theoretically, clinical localization of a lesion may be inaccurate, though it is believed that this is unlikely because of the very specific medullary syndromes we studied. The imaging parameters chosen for the PS studies show very well the infarctions that were demonstrated, but they may not be appropriate for those lesions not demonstrated. More noise was seen on the SE images than on the PS slices, making the interpretation of a small lesion more difficult if not seen on the PS studies. In a proper clinical context, all of these five cases, including the "negative" ones, stand as correctly excluding a mass compressing the medulla or enlarging the medulla, and in all five cases information

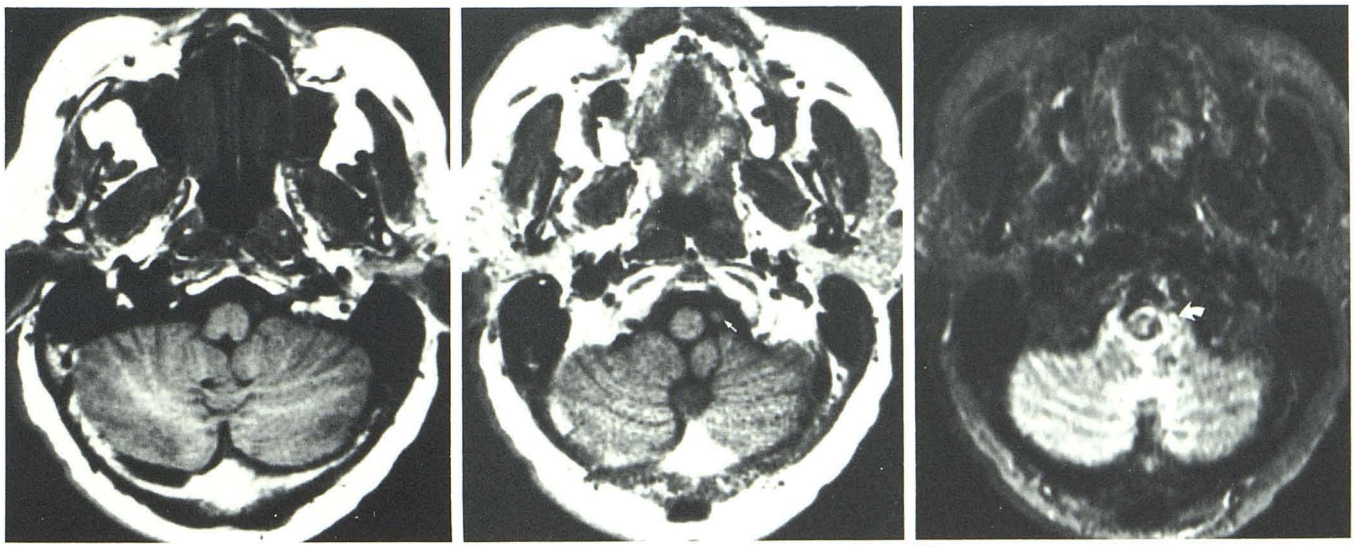

A B C

Fig. 4.—61-year-old man who had good recovery from left lateral medulla infarction 5 weeks earlier. **A**, PS scan, TR 400 msec, through medulla did not demonstrate infarction present clinically, although left side of medulla is slightly atrophic. **B**, PS scan, TR 400 msec, at level of cord medullary junction. Left vertebral artery (*arrow*) surrounded by CSF. **C**, SE scan, TR 2 sec, TE 75 msec, at same level. High signal instead of signal void within lumen of left vertebral artery (*arrow*) suggests vertebral occlusion, confirmed angiographically.

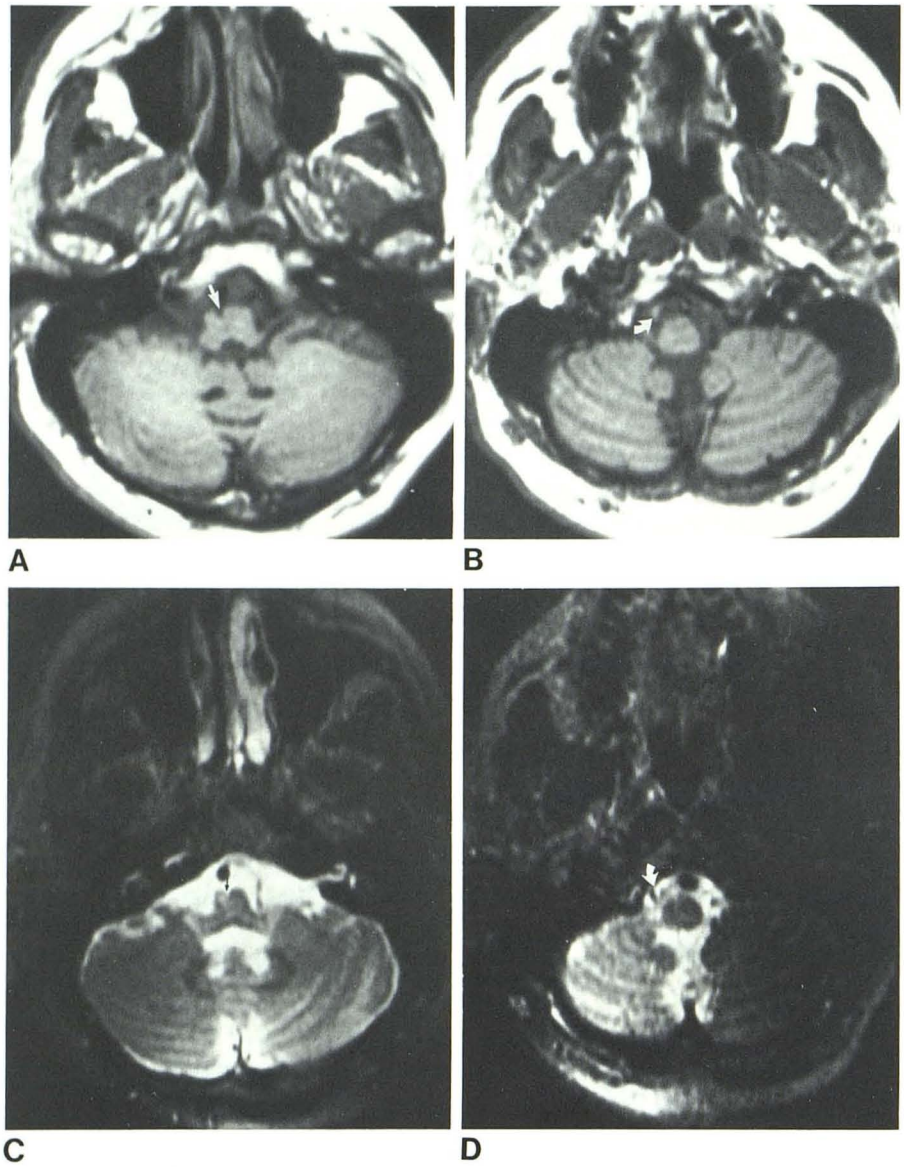

Fig. 5.—51-year-old man with poor recovery from right medial medulla infarction 12 months earlier. **A**, PS scan, TR 470 msec. Atrophic area believed to be infarction is low signal suggesting prolonged T1 (*arrow*). **B**, PS scan, TR 470 msec, in cord medullary junction region. Vessel, presumably right vertebral artery (*arrow*), is surrounded by CSF. **C**, SE scan, TR 2 sec, TE 100 msec, at level similar to **A**. Area of medial medullary infarction is high signal suggesting prolonged T2 (*arrow*). **D**, SE scan, TR 2 sec, TE 100 msec, at same level as **B**. High signal (*arrow*) in center of presumed right vertebral artery, instead of signal void, suggests right vertebral occlusion.

provided by MRI in the medulla was far superior to anything previously available with CT.

That a major intracranial artery is occluded in a patient with stroke can be suggested on occasion on CT, at least for acute cases [11] if there is a high density of that vessel. Since a vessel with a calcified plaque in its wall may also have high density in certain areas, the distinction between an occluded artery and a calcified artery may be somewhat imprecise on CT. With MRI, a flowing artery will show a signal void [12]. However, an occluded artery [12] will have a signal, though the specific T1 and T2 characteristics will depend on the exact material contained in that part of the vessel. Because calcification in an artery wall will not produce a magnetic signal, it may not interfere with the determination of whether a vessel is occluded or patent, but it may be difficult to separate flow from calcification if the residual lumen is too small. The finding of a high signal on T2-weighted images of the vertebral artery ipsilateral to the infarction in two of our five cases is a useful adjunct in the assessment of infarction. The same may be true of infarcts involving the territory of the intracranial carotid artery [13].

The medulla infarctions shown convincingly in our cases had dimensions as small as a very few millimeters in a structure (the medulla) 1.5–2.0 cm in diameter. This confirms the application of MRI to such a small region of the brain and also confirms that the 1.5 T magnet can produce these images in a time-efficient way with good anatomic detail. The applicability to acute medullary lesions and eventual monitoring of therapy appears feasible.

REFERENCES

1. Currier RD, Giles CL, DeJong RN. Some comments on Wallenberg's lateral medullary syndrome. *Neurology* **1961**;1:778–791

2. Ho KL, Myer KR. The medial medullary syndrome. *Arch Neurol* **1981**;38:385–387
3. Bradley WG, Waluch V, Yadley RA, Wycoff RR. Comparison of CT and MR in 400 patients with suspected disease of the brain and cervical spinal cord. *Radiology* **1984**;152:695–702
4. Bydder GM, Steiner RE, Young IR, et al. Clinical NMR imaging of the brain: 140 cases. *AJNR* **1982**;3:459–480
5. Han JS, Bonstelle CT, Kaufman B, et al. Magnetic resonance imaging in the evaluation of the brainstem. *Radiology* **1984**;150:705–712
6. Lee BCP, Kneeland JB, Deck MDF, Cahill PT. Posterior fossa lesions: magnetic resonance imaging. *Radiology* **1984**;153:137–143
7. McGinnis BD, Brady TJ, New PFJ, et al. Nuclear magnetic resonance (NMR) imaging of tumors in the posterior fossa. *J Comput Assist Tomogr* **1983**;7:575–584
8. Randell CP, Collins AG, Young IR, et al. Nuclear magnetic resonance imaging of posterior fossa tumors. *AJNR* **1983**;4:1027–1034
9. Kistler JP, Buonanno FS, DeWitt LD, Davis KR, Brady TJ, Fisher CM. Vertebral-basilar posterior cerebral territory stroke—delineation by proton nuclear magnetic resonance imaging. *Stroke* **1984**;15:417–426
10. Sipponen JD. Visualization of brain infarction with nuclear magnetic resonance imaging. *Neuroradiology* **1984**;26:389–391
11. Gács G, Fox AJ, Barnett HJM, Viñuela F. CT visualization of intracranial arterial thromboembolism. *Stroke* **1983**;14:756–762
12. Mills CM, Brant-Zawadzki M, Crooks LE, et al. Nuclear magnetic resonance: principles of blood flow imaging. *AJNR* **1983**;4:1161–1166
13. Brant-Zawadzki M, Davis PL, Crooks LE, et al. NMR demonstration of cerebral abnormalities: comparison with CT. *AJNR* **1983**;4:117–124