

Are your **MRI contrast agents** cost-effective?

Learn more about generic **Gadolinium-Based Contrast Agents**.



FRESENIUS
KABI

caring for life

AJNR

Intraarterial chemotherapy of head and neck tumors.

Y Y Lee, S Wallace, I Dimery and H Goepfert

AJNR Am J Neuroradiol 1986, 7 (2) 343-348

<http://www.ajnr.org/content/7/2/343>

This information is current as
of April 19, 2024.

Intraarterial Chemotherapy of Head and Neck Tumors

Ya-Yen Lee¹
 Sidney Wallace¹
 Isaiah Dimery²
 Helmuth Goepfert³

Forty-one patients with advanced recurrent or untreated head and neck tumors were treated with intraarterial short-term (1–1½ hr) infusion of cisplatin into the external carotid artery, achieving an immediate tumor response rate of 29.3%. Tumor extent within or beyond the territory of a single external carotid artery was the only significant factor identified affecting the tumor response rate (57.1% vs. 14.8%). Treatment with intraarterial chemotherapy using superselective catheterization before irradiation or surgery is beneficial in some patients.

The purpose of regional chemotherapy is to achieve maximum tumor-cell kill. Regional intraarterial chemotherapy has a potential advantage of delivering a higher concentration of chemotherapeutic agents to the tumor site while minimizing systemic toxicity. Tumor eradication with preservation of function and cosmesis are the essence of therapy for head and neck tumors. Head and neck neoplasms tend to remain localized and only metastasize to regional lymph nodes when advanced. The feeding arteries of the head and neck structures are readily accessible for selective catheterization. Therefore, head and neck neoplasms are theoretically ideal for intraarterial regional chemotherapy. In this communication, we review our experience in intraarterial chemotherapy of head and neck tumors at the University of Texas, M. D. Anderson Hospital and Tumor Institute, and discuss its feasibility and limitations.

Materials and Methods

From April 1979 to October 1984, 41 patients with head and neck tumors were entered into intraarterial chemotherapy regimens. According to the histologic diagnosis, there were 14 squamous cell carcinomas, nine osteosarcomas, five rhabdomyosarcomas, three malignant melanomas, three adenocarcinomas, and seven miscellaneous tumors including one each of malignant osteoblastoma, histiocytic lymphoma, malignant fibrous histiocytoma, adenoid cystic carcinoma, malignant myxoma, mucoepidermoid carcinoma, and invasive juvenile angiofibroma. Patients who had radiologic (mainly CT) or clinical evidence of intracranial extension or regional nodal or distant metastases were not eligible for this approach. Also excluded were those with tumor extending into the territory of the vertebral arteries (by arteriography and/or CT). Thirty cases were recurrent after surgery and/or irradiation, and the other 11 were advanced untreated patients. There were 31 males and 10 females. The age of the patients ranged from 3 to 69 years (mean, 40.5 years). The number of courses of intraarterial infusion was one to seven, depending on the immediate responses.

The immediate treatment response from intraarterial chemotherapy was assessed by clinical examination before each course of intraarterial infusion and by CT after every two or three courses. No attempt was made to evaluate long-term survival. The degree of response by definition was classified as complete response (tumor completely resolved), partial response (tumor reduction more than 50%), no response (tumor reduction less than 50%), and progression [1]. The final assessment of response was made by CT evaluation.

Received March 12, 1985; accepted after revision June 14, 1985.

¹ Department of Diagnostic Radiology, University of Texas System Cancer Center, M. D. Anderson Hospital and Tumor Institute, 6723 Bertner Ave., Houston, TX 77030. Address reprint requests to Y.-Y. Lee.

² Department of Medical Oncology, University of Texas System Cancer Center, M. D. Anderson Hospital and Tumor Institute, Houston, TX 77030.

³ Department of Head and Neck Surgery, University of Texas System Cancer Center, M. D. Anderson Hospital and Tumor Institute, Houston, TX 77030.

AJNR 7:343–348, March/April 1986
 0195–6108/86/0702–0343

© American Society of Neuroradiology

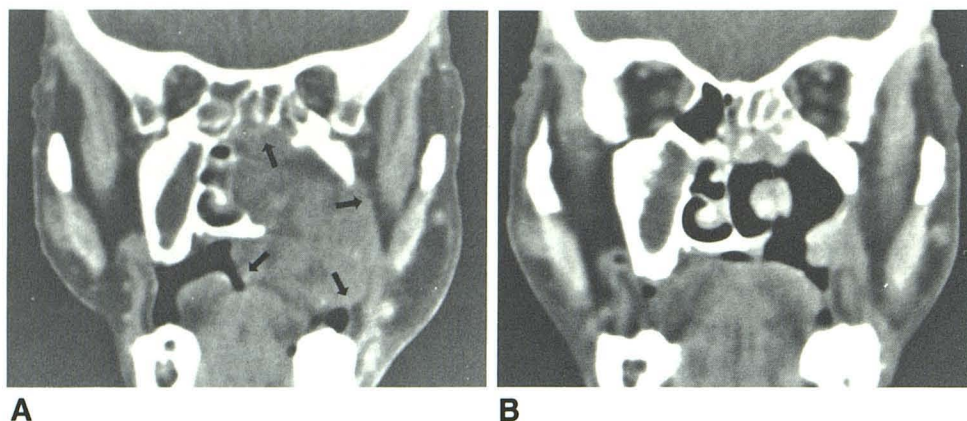


Fig. 1.—64-year-old woman with untreated stage IV (T4 N0 M0) squamous cell carcinoma originating from left maxillary sinus. **A**, Coronal CT scan before initiation of intraarterial chemotherapy. Local tumor extension to left ethmoid sinus and nasal fossa destroying left hard palate with tumor projecting into oral cavity (arrows). **B**, 3 months later after three monthly courses of intraarterial cisplatin 80 mg/m² and bleomycin 40 U. Significant regression of tumor.

Catheterization Consideration

Under local anesthesia in adults or general anesthesia in children, arterial catheterization was performed via the femoral arterial route using the Seldinger technique. A 5 French polyethylene catheter was routinely used in adult patients with a 6.5 French Torcon catheter reserved for those patients with tortuous arteries. In children, 3.7–5 French catheters were used. Systemic heparinization was accomplished with 50 U/kg of aqueous heparin given intraarterially once the arterial system was entered and heparin-saline flush every 2–3 min with 2–3 ml of a solution of 1000 U heparin in 500 ml of normal saline. The half-life of heparin is about 60 min.

External carotid arteriography in the anteroposterior and lateral projections was performed once the catheter was placed in the proximal external carotid artery to evaluate the general vascular anatomy of facial structures and the blood supply to the tumor. For those tumors located in the midline or paramedian structures and those with midline extension on CT, a contralateral external carotid arteriogram was also routinely obtained. Internal carotid arteriography was performed for the lesions extending into the orbit, ethmoid, or sphenoid sinus or invading the base of the skull; vertebral arteriography was done if necessary to rule out tumor supply from the vertebral arteries. Patients with tumor extension into the territories of, or receiving blood supply from, the internal carotid and/or vertebral arteries were excluded. After identifying the vascular territory of the neoplasm originating exclusively from the external carotid, the catheter was advanced distally in the external carotid artery but still encompassing the origins of all supplying branches. The hypo- or avascular lesions were treated arbitrarily with a catheter placed in the main trunk or branch of the external carotid artery supplying the territory of the tumor. For those that received dual blood supply from both external carotid systems, only one external carotid artery was to be infused at each sitting. When superselective catheterization was not difficult, nonnourishing branches were proximally occluded with Gelfoam segments or Ivalon to avoid unnecessary exposure of the unaffected structures. Rich collateral circulation of head and neck structures usually prevents the tissue necrosis of the embolized region. During these maneuvers, caution was used to avoid intimal injury, which might be exacerbated by direct irritation of chemotherapeutic agents and lead to an occlusion of the artery. An extralong floppy guide wire was routinely used to decrease the likelihood of arterial spasm. For the relatively restricted lesion, such as in the maxillary antrum, a new 3 French ultrasoft Gore-Tex catheter was used to achieve superselective catheterization. On subsequent infusions, only a lateral projection of the arteriogram was performed to reassess the vascular supply to the tumor.

Chemotherapeutic Regimen

Cisplatin (cis-diammine-dichloroplatinum II or CDDP) at a dose of 80–120 mg/m², diluted in 200 ml normal saline, was infused over 1–1½ hr through a 0.2 µm filter. Two ml of heparin (2000 U) were added to the intraarterial infusion because of the relatively long total procedure time (1½–2 hr) and catheter placement. The arteries to be infused were restricted to the external carotid artery or its branches. For those lesions receiving dual blood supplies from both external carotid arteries, each external carotid artery was to be infused separately at the same dosage described 2–3 days apart. In the last six patients with squamous cell carcinoma, bleomycin 40 units, diluted in 50 ml normal saline, was combined with the cisplatin infusion. In the group of osteosarcomas, concomitant systemic chemotherapy with adriamycin was delivered intravenously over a period of 96 hr just before intraarterial infusion of cisplatin. The chemotherapy was repeated 3–4 weeks later, and the patients were then evaluated for response and further infusion.

Vigorous hydration with intravenous fluid started 12 hr before infusion of cisplatin and continued for at least 24 hr afterward if no nausea, vomiting, or diarrhea occurred. Intravenous Demerol was used for local pain or discomfort during infusion. Premedication with antiemetics was maintained for at least 8 hr after the infusion. Intravenous Decadron was routinely used to minimize local swelling; at times intraarterial Decadron, up to 100 mg, was helpful to alleviate the local pain, presumably caused by a chemical arteritis.

Results

Tumor Response

No case of complete response was observed in this series. A partial response was achieved in 12 patients (29.3%). The other 29 patients (70.7%) showed either no response or progression throughout the treatment. Partial response was observed in two (14.3%) of 14 patients with squamous cell carcinoma (fig. 1), three (33.3%) of nine with osteogenic sarcoma, three (60%) of five with rhabdomyosarcomas (60%) (fig. 2), and one each with adenoid cystic carcinoma, juvenile angiofibroma, malignant myxoma, and mucoepidermoid carcinoma (fig. 3). No tumor response was observed in any patient with adenocarcinoma or malignant melanoma.

Regardless of the previous treatment(s), a partial response rate of 57.1% (8/14) was achieved in patients whose tumor was confined within the territory of a single external carotid

Fig. 2.—3-year-old boy with untreated extensive rhabdomyosarcoma originating from right infratemporal fossa. **A**, CT scan before initiation of intraarterial chemotherapy. Extensive tumor extension to right temporal region with intraorbital involvement (*arrows*). **B**, 8 months later after seven monthly courses of cisplatin 100 mg/m². Significant partial tumor response with central necrosis (*asterisk*).

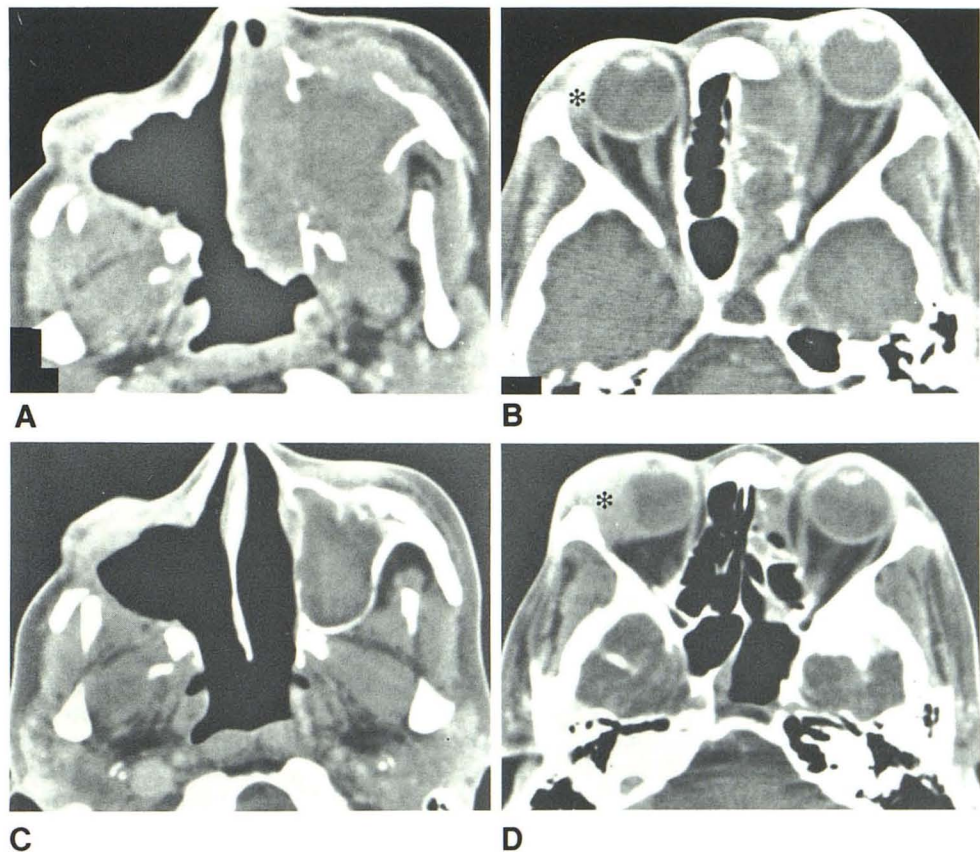
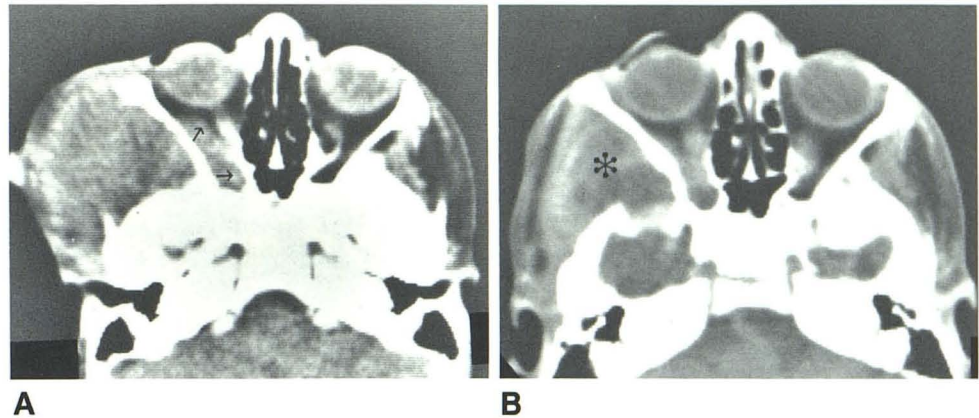


Fig. 3.—34-year-old woman with recurrent mucoepidermoid carcinomas originating from right maxillary sinus after surgery, radiotherapy, and systemic chemotherapy. **A** and **B**, CT before intraarterial chemotherapy. Right surgical defects with recurrent tumor extending into right orbit (*asterisk*), left nasal fossa, left maxillary walls, left ethmoid and sphenoid sinuses, and left orbit. **C** and **D**, 3 months later after 3 courses of intraarterial cisplatin 100 mg/m² each into right and left external carotid arteries with systemic adriamycin. Remarkable regression of recurrent tumor on left. Right intraorbital extension (*asterisk*) did not respond and instead progressed, apparently resulting from inadequate chemotherapeutic infusion from previous surgical ligation of feeding arteries.

artery; conversely, the rate was 14.8% (4/27) when the tumors extended far beyond the territory. The response rate in the subgroup of 11 patients who did not receive previous treatment was 36.3% (4/11), only slightly above the overall rate of 29.3% (12/41). There was no difference in response regarding the vascularity of tumors.

Complications

No major complications, such as cerebrovascular accident, cranial palsy, or ophthalmopathy, were observed. One patient

developed occlusion of both internal maxillary arteries, caused by the intimal damage from catheterization exacerbated by the chemotherapeutic agents. Minor local discomfort, pain, and/or a burning sensation were experienced by almost all of the patients and promptly relieved by intravenous analgesics or intraarterial Decadron. No significant systemic toxicity, such as nephrotoxicity or myelosuppression, was noted in our study. Nausea and/or vomiting of a relatively minor degree, most probably due to cisplatin, was invariably experienced and was well controlled by antiemetic medication.

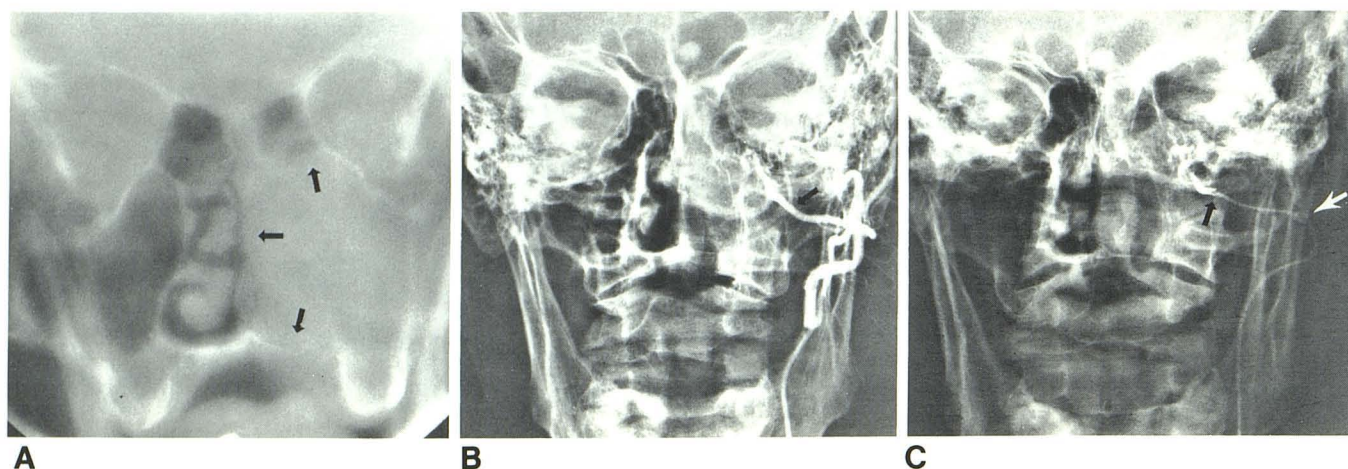


Fig. 4.—69-year-old man with untreated malignant melanoma involving left maxillary antrum. A, Conventional tomogram. Local extension of tumor into nasal fossa and ethmoid sinus (arrows). B, Preinfusion posteroanterior external carotid arteriogram shows origin of left middle meningeal artery (arrow). C,

Posteroanterior arteriogram. Tip of Gore-Tex catheter (black arrow) beyond origin of middle meningeal artery, overcoming tortuous looping of proximal internal maxillary artery (white arrow).

Discussion

In 1950, Klopp et al. [2] first treated head and neck tumors intraarterially using nitrogen mustard. Since then many chemotherapeutic agents [3–7], particularly methotrexate (MTX), have been infused intraarterially through a surgically placed catheter in the superficial temporal artery, with or without an infusion pump [8–12]. Unfortunately, the intraarterial chemotherapy of the head and neck tumors did not yield optimal results, and complications related to the use of an indwelling catheter occurred frequently [13]. In the earlier trials MTX, an antimetabolite, was apparently a poor choice for intraarterial therapy because of its strong dependence on prolonged exposure for cytotoxicity [14]. Alkylating agents such as cisplatin are known to be non-cycle-specific and independent of the duration of drug exposure [15]. Their primary dependence on drug concentration and first-pass extraction make intermittent bolus or short-term infusion (1–1.5 hr) preferable and allow sufficient time between doses for normal tissue to recover [16]. Cisplatin is an antitumor agent that produces DNA interstrand and intrastrand cross-links and cross-links between DNA and associated proteins, behaving as an alkylating agent [17]. Cisplatin has a short initial plasma half-life (about 30 min) and a high affinity for tissue proteins that are thought to bind to the drug during its first pass through the capillary bed [18, 19]. Clinical trials of intraarterial cisplatin at our institution demonstrated the effectiveness of treating extensive regional melanoma by increasing the regional drug concentration and its gradient across the cell membrane [20, 21]. Subsequently, encouraging results were documented in intraarterial cisplatin treatments of varied regionally confirmed malignancies [19, 22–25]. An excellent response was also reported in intraarterial cisplatin treatment of head and neck adenoid cystic carcinoma [26]. The clinical trials of combined 5-fluorouracil intraarterial infu-

sion using an indwelling catheter via the superficial temporal arteries and radiotherapy for previously untreated advanced head and neck cancer were carried out at our institution in the 1960s, with a 47.8%–64.7% complete response rate [27, 28]. However, these encouraging responses were offset by various serious complications including blindness, extensive fibrinoid mucositis, and scarring, as well as necrosis [13]. Selective catheterization of the external carotid artery and its branches through a percutaneous approach has become more consistent and sophisticated in recent years; complications related to short-term percutaneous catheterization have been significantly lower than those induced by an indwelling catheter. With the availability of an alkylating agent such as cisplatin, intermittent intraarterial chemotherapy via the percutaneous approach is feasible with fewer complications, and forms the rationale for this clinical project.

Using cisplatin alone or with concomitant hyperthermia in the earlier trials (two cases) and more recently with intraarterial bleomycin (six cases), the response of squamous cell carcinoma in our study was disappointing, with a partial response rate of 14.3%. A better partial response rate, 33.3%, was noted in nine cases of osteosarcoma, which still did not compare well with that achieved with osteosarcomas occurring in the extremities [24]. Furthermore, no response was observed in three patients with malignant melanoma and in three with adenocarcinoma. Although there was no complete response, three (60%) of five patients with rhabdomyosarcoma showed encouraging partial responses.

The effectiveness of intraarterial chemotherapy depends not only on tumor sensitivity but also on the anatomic territory of the infused artery. If the tumor extent is unilaterally contained within the territory of a single external carotid artery, the response rate will dramatically increase, as demonstrated by our results. This may explain the relatively poor results in our patients with squamous cell carcinoma and

osteosarcoma of the head and neck when compared with the proven effect of cisplatin on these same tumors elsewhere. Unsatisfactory catheter placement, resulting from vascular tortuosity, further negatively influences the response rate [19]. Proximal external carotid catheterization can be accomplished easily but is often suboptimal because of the distance to the tumor bed and the relatively high flow rate. At times superselective catheterization of the tumor-feeding arteries can be associated with intimal damage and subsequent occlusion after repeated infusions. Furthermore, surgery and/or radiotherapy can disturb the regional blood supply to the tumor bed, resulting in a poorer response rate [29, 30], although this factor could not be evaluated in our study because of the small number of patients.

Using a coaxial catheter system, a newly developed 3 French ultrasoft Gore-Tex catheter [31] can be placed close to the tumor bed with minimal manipulation and thus avoid the intimal damage and possible occlusion of the feeding arteries (fig. 4). We have successfully used this new catheter on 11 occasions in three patients with limited disease. Other minicatheters using calibrated-leak balloons [32–34] should achieve the same goal. This superselective catheterization should further decrease the blood flow rate to the tumor and thereby achieve a higher therapeutic index. (The therapeutic advantage [Rt] of intraarterial infusion over the intravenous route can be described as $Rt = 1 + \text{apparent plasma clearance/tumor plasma flow}$ [35, 36].) Furthermore, this approach should limit the unwanted side effects to the tumor bed and adjacent normal tissue. With the availability of cisplatin providing the feasibility of bolus or short-term infusion, reevaluation of the preirradiation or preoperative intraarterial chemotherapy using a superselective catheterization is in order because of its first-pass and radiosynergistic effect.

REFERENCES

- DeVita VT Jr, Hollman S, Rosenberg SA, ed. *Cancer—principles and practice of oncology*. Philadelphia: Lippincott, pp. 444–445
- Klopp CT, Alford TC, Bateman J, Berry GN, Winship T. Fractionated intra-arterial cancer chemotherapy with methyl bisamine hydrochloride: a preliminary report. *Ann Surg* 1950;132:811–832
- Sullivan RD, Miller E, Sikes MP. Antimetabolite-metabolite combination cancer chemotherapy; effects of intra-arterial methotrexate-intramuscular citrovorum factor therapy in human cancer. *Cancer* 1959;12:1248–1262
- Sullivan RD, Miller E, Chrysochoos T, Watkins E Jr. The clinical effects of the continuous intravenous and intraarterial infusion of cancer chemotherapeutic compounds. *Cancer Treat Rep* 1962;16:449–510.
- Westbury G. Regional chemotherapy in malignant disease. *Ann R Coll Surg Engl* 1963;32:358–379
- Johnson RO, Kiskan WA, Curreri AR. A report upon arterial infusion with 5-fluorouracil in 100 patients. *Surg Gynecol Obstet* 1965;120:530–636
- Burkhardt A, Holtje WJ. Effects of intra-arterial bleomycin therapy in squamous cell carcinoma of the oral cavity: biopsy and autopsy examinations. *J Maxillofac Surg* 1975;3:217–230
- Ramsden CH, Duff JK. Continuous arterial infusion of head and neck tumors: improvements in technique by retrograde temporal artery catheterization. *Cancer* 1963;16:133–135
- Oettgen HF, Duff JK, Clifford P. Problems of continuous chemotherapy by arterial catheters. *Arch Surg* 1963;86:323–330
- Watkins E Jr. Chronometric infusor—an apparatus for protracted ambulatory infusion therapy. *N Engl J Med* 1963;269:850–851
- Burn JI, Gains E. The Chemofusor: a new apparatus for maintaining continuous intra-arterial infusion chemotherapy. *Br J Surg* 1973;60:375–377
- Baker SR, Wheeler RH, Ensminger WD, Niederhuber JE. Intra-arterial infusion chemotherapy for head and neck cancer using a totally implantable infusion pump. *Head Neck Surg* 1981;4:118–124
- Goldsmith MA, Carter SK. The integration of chemotherapy into a combined modality approach to cancer therapy vs. squamous cell cancer of the head and neck. *Cancer Treat Rev* 1975;2:137–158
- Muggia FM, Wolf GT. Intra-arterial chemotherapy of the head and neck cancer: worth another look? *Cancer Clin Trials* 1980;3:375–379
- Blum RH, Frei E III, Holland JF. Principles of dose, schedule, and combination chemotherapy. In: Holland JF, Frei E III, eds. *Cancer medicine*. Philadelphia: Lea & Febiger, 1982:730–752
- Baker SR, Wheeler R. Intraarterial chemotherapy for head and neck cancer, part I. Theoretical consideration and drug delivery systems. *Head Neck Surg* 1983;6:664–682
- Zwelling LA, Anderson T, Kohn WK. DNA-protein and DNA interstrand cross-linking by us and trans-platinum (II) diammine-dichloride in L1210 leukemia cells and relation to cytotoxicity. *Cancer Res* 1983;43:917–920
- Stewart DJ, Benjamin RS, Zimmerman S, et al. Clinical pharmacology of intra-arterial cis-diammine-dichloroplatinum II (CDP). Angiographic, pathologic, and pharmacologic studies. *Cancer* 1983;51:402–407
- Jaffe N, Kapp J, Chuang V, et al. Osteosarcoma: intra-arterial treatment of the primary tumor with cis-diammine-dichloroplatinum II (CDP). Angiographic, pathologic, and pharmacologic studies. *Cancer* 1983;51:402–407
- Pritchard J, Mavligit G, Benjamin RS, et al. Regression of regionally confined melanoma with intra-arterial cis-diammine-dichloroplatinum (II). *Cancer Treat Rep* 1979;63:555–558
- Pritchard JD, Mavligit GM, Wallace S, Benjamin RS, McBride CM. Regression of regionally advanced malignant melanoma after arterial infusion with cis-platinum and actinomycin D. *Clin Oncol* 1979;5:179–182
- Calvo DB IV, Patt YZ, Wallace S, et al. Phase I–II trial of percutaneous intra-arterial cis-diammendichloro platinum (II) for regionally confined malignancy. *Cancer* 1980;45:1278–1283
- Feun LG, Wallace S, Stewart DJ, et al. Intracarotid infusion of cis-diammine-dichloroplatinum in the treatment of recurrent malignant brain tumors. *Cancer* 1984;54:794–799
- Lehane DE, Bryan RN, Horowitz B, et al. Intra-arterial cis-platin chemotherapy for patients with primary and metastatic brain tumors. *Cancer Drug Deliv* 1983;1:69–77
- Benjamin RS, Murray JA, Wallace S, et al. Intra-arterial preoperative chemotherapy for osteosarcoma: a judicious approach to limb salvage. *Cancer Bull* 1984;36:32–36
- Sessions RB, Lehane DE, Smith RJH, Bryan RN, Suen JY. Intra-arterial cisplatin treatment of adenoid cystic carcinoma. *Arch Otolaryngol* 1982;108:221–224
- Jesse RH, Goepfert H, Lindberg RD, Johnson RH. Combined intra-arterial infusion and radiotherapy for the treatment of advanced cancer of the head and neck. *AJR* 1969;105:20–25

28. Goepfert H, Jesse RH, Lindberg RD. Arterial infusion and radiation therapy in the treatment of advanced cancer of the nasal cavity and paranasal sinuses. *Am J Surg* **1973**;26:464-468
29. Sealy R, Helman R. Treatment of head and neck cancer with intraarterial cytotoxic drugs and radiotherapy. *Cancer* **1972**;30:187
30. Jussawalla DJ, Shetty PA. Experiences with intra-arterial chemotherapy for head and neck cancer. *J Surg Oncol* **1978**;10:33-37
31. Charnsangavej C, Lee Y-Y, Carrasco CH, et al. Supraclinoid intracarotid chemotherapy using a flow-directed soft-tipped catheter. *Radiology* **1985**;155:655-657
32. Debrun GM, Davis KR, Hochberg FH. Superselective injection of BCNU through a latex calibrated-leak balloon. *AJNR* **1983**;4:399-400
33. Metes J, Lazo A, Milner M, Barboza R, Decker D. Supraorbital placement of microleak balloon catheters for chemotherapy of brain tumors (abstr). Presented at the annual meeting of the American Society of Neuroradiology, Boston, June **1984**
34. Choi IS, Berenstein A, Ranshoff J, Foo SH, Kricheff II. Intra-arterial infusions of BCNU and cis-platinum. Presented at the annual meeting of the American Society of Neuroradiology, Boston, June **1984**
35. Chen H-SG, Gross JF. Intra-arterial infusion of anticancer drugs: theoretic aspects of drug delivery and review of responses. *Cancer Treat Rep* **1980**;64:31-40
36. Campbell TN, Howell SB, Pfeifle CE, Wang WE, Bookstein J. Clinical pharmacokinetics of intra-arterial cisplatin in humans. *J Clin Oncol* **1983**;1:755-762