

Are your **MRI contrast agents** cost-effective?

Learn more about generic **Gadolinium-Based Contrast Agents**.



**FRESENIUS
KABI**

caring for life

AJNR

**Delayed presentation of posttraumatic cervical
disk herniation.**

B Blumenkopf and W F Bennett

AJNR Am J Neuroradiol 1986, 7 (4) 722-724

<http://www.ajnr.org/content/7/4/722.citation>

This information is current as
of April 20, 2024.

Delayed Presentation of Posttraumatic Cervical Disk Herniation

Bennett Blumenkopf¹ and William F. Bennett²

Traumatic injuries of the cervical spine are frequent, especially following motor vehicle accidents [1]. Multiple lesions predominate, with a variable distribution according to vertebral level and anatomic structure [2, 3]. Injury to the intervertebral disk has been seen in slightly less than one-third of patients [2, 3]. A patient with a neck injury developed obvious radiographic signs of spinal injury, but on a delayed basis. The unusual sequence of events and radiologic studies are presented.

Case Report

A 20-year-old man was admitted to our medical center for evaluation of a neck injury sustained 4 weeks previously. The patient was involved in a car accident and sustained a closed-head injury with an occipital bone fracture and a 12–15 hr period of unconsciousness. Thereafter, he complained of right-sided neck pain, but several series of cervical spine radiographs were interpreted as normal. Three weeks following the injury, he complained of dysphagia, and right-sided cervical paraspinal atrophy was noted. In addition, fluoroscopy revealed right hemidiaphragmatic paralysis. He was transferred to the Neurosurgery Service for further evaluation.

Examination

Neurologic examination of the cranial nerves revealed atrophy or absence of the right sternocleidomastoid muscle. There was no Horner's syndrome. The extremity examination revealed atrophy of the right supraspinatus muscle. Motor power appeared full except for withholding because of pain. There was hyperalgesia on the right in a C2 dermatomal pattern. Reflexes were normal. Neck examination revealed tenderness over the cervical spine C2–C3 area.

There was no evidence of cervical spine trauma of either bony or soft tissue upon review of the radiographs taken at the time of injury. Cervical spine tomography was done shortly after admission to our medical center 4 weeks later. Anteroposterior and lateral views revealed evidence of C3–C4 disk injury with loss of the disk space, and increased soft tissue anterior to C1 through C4. Chest fluoroscopy revealed normal diaphragmatic excursions. Electromyographic

studies were performed, revealing denervation changes in the cervical paraspinals bilaterally, sternocleidomastoid muscles bilaterally, and right rhomboid muscle. A metrizamide cervical myelogram was then attempted. Unfortunately, the contrast concentration was poor, but the results suggested an anterior extradural defect at the C3–C4 level (Fig. 1A). Following this, a metrizamide-enhanced CT scan was obtained revealing a right-sided extradural defect at the C3–C4 level consistent with disk herniation (Fig. 1B). Retropharyngeal soft-tissue space widening was also recognized, and plans were made for surgical excision.

While awaiting surgery the patient complained of increased neck pain, now bilaterally. A repeat series of cervical spine radiographs suggested increasing soft-tissue widening anteriorly at the C1–C4 levels. To define the extent of the extradural lesion, another metrizamide cervical myelogram was performed. An extensive anterior extradural defect was now evident overlying the C3 and C4 bodies (Fig. 1C). Again, a follow-up CT scan showed the extradural process (Fig. 1D). Blood counts and sedimentation rates were checked to rule out an infectious etiology. They were all normal.

Operation

Surgery was performed using an anterior approach to the cervical spine under general anesthesia. The prevertebral soft tissues were thickened with a gross appearance of scar formation. The anteroinferior aspect of the C3 body had a small avulsion fracture. The C3–C4 intervertebral disk space was markedly diminished in height. Under microscopic magnification the anterior longitudinal ligament was incised and the C3–C4 intervertebral disk space explored. The entire disk content was displaced posteriorly. There was no evidence of purulence. The disk material was removed until the posterior longitudinal ligament was identified. There were no perforations. The posterior longitudinal ligament was then opened, and it appeared thickened. The anterior dural sac was seen and the right C4 nerve root identified. Again, there was no purulence or hematoma. The wound was then routinely closed.

The patient noted immediate improvement in his neck pain, but his examination results remained unchanged. One month postoperatively, the patient reported continued pain relief, improved proximal right upper-extremity strength, and normal range of neck motion.

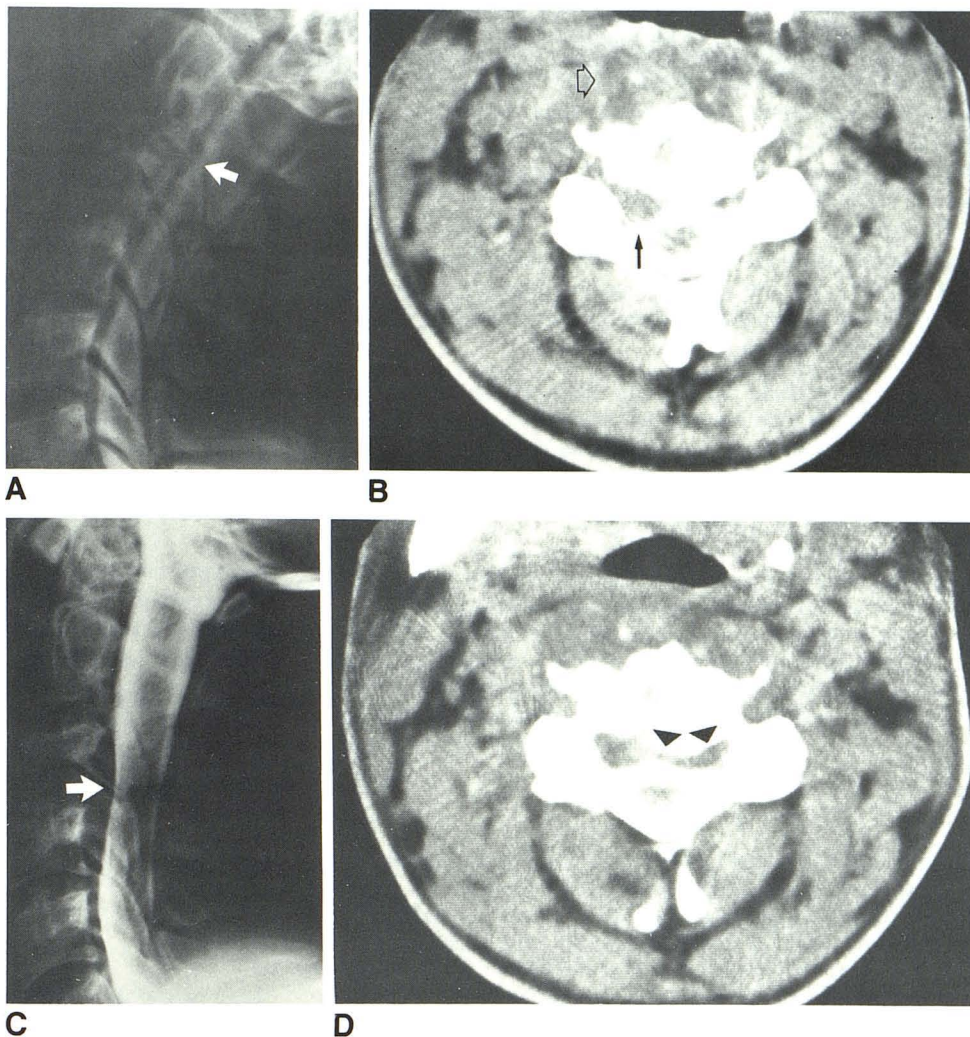
Received October 5, 1984; accepted after revision December 8, 1984.

The opinions or assertions contained herein are the private views of the authors and are not to be construed as reflecting the view of the Department of the Army or the Department of Defense.

¹Department of Surgery, Neurosurgery Service, Brooke Army Medical Center, Fort Sam Houston, TX 78234. Address reprint requests to the Chief, Department of Radiology.

²Department of Radiology, Brooke Army Medical Center, Fort Sam Houston, TX 78234.

Fig. 1.—A, Lateral view of metrizamide myelogram shows subtle displacement of contrast column posteriorly at C3–C4 (arrow). B, Metrizamide CT shows anterior extradural defect (arrow) compatible with herniated disk. Prevertebral soft-tissue swelling is present (open arrow). C, Lateral view of metrizamide myelogram after progression of symptoms. Anterior extradural defect (arrow) has become larger. D, Metrizamide CT shows extension of extradural defect across anterior epidural space (arrowheads).



Follow-up electromyographic studies revealed reinnervation and no increased denervation in the areas previously examined. A low-dose intrathecal metrizamide-enhanced CT scan of the operative level showed resolution of the extradural defect. Four months postoperatively, the patient is clinically intact, and plain radiographs reveal fusion of C3 and C4 with no instability.

Discussion

Cervical spine injuries, often as a consequence of an automobile accident, are relatively common. Other injuries, particularly head injuries, are often associated with them [4]. Owing to the possibility of profound neurologic damage, the diagnosis of a cervical spine injury is of paramount importance [5].

The plain-film radiographic diagnosis of cervical spine injury involves analysis for signs of abnormal soft tissues, abnormal vertebral alignment, and abnormal joints [2, 6]. In a large series of patients with recognized cervical spine injuries, a number of important observations were made [2, 3]. More than one lesion in a given patient was common, averaging 2.4 per patient. Each vertebral level was involved to some extent, but with frequencies varying from 6% at C1 to 27%

at C2 or C6. Twenty percent of patients had several levels of injury. The anatomic structures involved in the injury also varied, with vertebral arch fractures occurring in 50% of the patients; vertebral body, 30%; posterior ligaments, 16%; dens, 14%; locked facets, 12%; and anterior ligaments, 2%. It is of interest in the case being discussed that intervertebral disk injury was seen in 29% of patients.

Additional information in up to 25% of cases can be obtained with polytomography [5, 7, 8]. More recently, CT has proved valuable in defining the extent of injuries. Positive-contrast myelography, now most commonly using metrizamide, and intrathecal metrizamide-enhanced CT are other useful diagnostic procedures.

The patient under discussion presented with signs of upper cervical radiculopathy and spinal-accessory nerve injury. The skull-fracture and associated period of unconsciousness suggested that serious injury occurred during the accident. Despite the clinical evidence, however, plain-film radiographic signs of cervical spine injury were absent, including signs of indirect soft-tissue damage. Approximately 1 month later, definite C3–C4 disk changes were noted, most obviously on tomography. This is a rather uncommon level for cervical disk herniation [9], and of relatively low incidence in cervical spine

injury (10% in the series cited above) [3]. The value of myelography and CT was demonstrated. The delayed and then progressive development of epidural compression at the disk level was noted. This had the initial appearance of a unilateral, focal disk herniation. The subsequent study raised the possibility of epidural infection or hematoma formation, but the surgical findings excluded these.

The anterior approach to the cervical disk was ideal for exploring the location of the dural compression. The exposure was excellent and the decompression complete, as demonstrated on the postoperative study. Fusion proceeded without the use of an interbody graft.

REFERENCES

1. Clark K. Injuries to the cervical spine and spinal cord. In: Youmans JR, ed. *Neurological surgery*. Philadelphia: Saunders, **1982**:2318-2337
2. Gehweiler JA, Osborne RL, Becker RF. In: *The radiology of vertebral trauma*. Philadelphia: Saunders, **1980**:118-129
3. Miller MD, Gehweiler JA, Martinez S, Charlton OP, Daffner RH. Significant new observations on cervical spine trauma. *AJR* **1978**;130:659-663
4. Calenoff L, Chessare JW, Rogers LF, Toerge J, Rosen JS. Multiple level spinal injuries: importance of early recognition. *AJR* **1978**;130:665-669
5. Maravilla KR, Cooper PR, Sklar FH. The influence of thin-section tomography on the treatment of cervical spine injuries. *Radiology* **1978**;127:131-139
6. Clark WM, Gehweiler JA, Laib R. Twelve significant signs of cervical spine trauma. *Skeletal Radiol* **1979**;3:201-205
7. Binet EF, Moro JJ, Marangola JP, Hodge CJ. Cervical spine tomography in trauma. *Spine* **1977**;2(3):163-172
8. Russin LD, Guinto FC. Multidirectional tomography in cervical spine injury. *J Neurosurg* **1976**;45:9-11
9. Murphy F, Simmons JCH, Brunson B. Ruptured cervical discs, 1939 to 1972. *Clin Neurosurg* **1973**;20:9-17