

Are your MRI contrast agents cost-effective?
Learn more about generic Gadolinium-Based Contrast Agents.



AJNR

CT in iatrogenic cerebral air embolism.

M E Jensen and M H Lipper

AJNR Am J Neuroradiol 1986, 7 (5) 823-827
<http://www.ajnr.org/content/7/5/823>

This information is current as
of April 19, 2024.

CT in Iatrogenic Cerebral Air Embolism

Mary E. Jensen¹
Maurice H. Lipper²

Three patients with suspected iatrogenic cerebral air embolism had cranial CTs performed within 24 hr of onset of symptoms. One was interpreted as normal, one showed a large, right frontoparietal enhancing lesion, and the third showed evidence of bi-thalamic infarction. Follow-up scans 7 to 10 days later showed either single or multiple enhancing infarcts in all patients. Although CT proved a valuable tool in the diagnosis of this condition, one out of three initial studies were negative, necessitating a follow-up scan.

Systemic air embolism is more often than not an iatrogenic complication of an invasive procedure. The evanescent nature of air bubbles in the vascular system makes them difficult to recognize, both radiologically and on postmortem inspection [1, 2].

Recently, however, the diagnosis of cerebral air embolism has been confirmed by CT [2, 3]. In both reported cases, an unenhanced scan was performed immediately after onset of symptoms and showed multiple, small, well-defined areas of air density within one or both cerebral hemispheres.

We present three patients with suspected cerebral air emboli whose initial scans were performed within 24 hr of the onset of clinical findings. One was interpreted as normal, two showed low densities consistent with infarction; all three developed abnormally enhancing areas consistent with infarcts within the ensuing 7 to 10 days.

Case Reports

Case 1

A 29-year-old man had a central line placed for parenteral nutrition. After surgery, 2 weeks later, the patient unwittingly disconnected his subclavian line to walk across the room. Within 1 min, he complained of feeling poorly, became unresponsive, and was noted to be diaphoretic with a heart rate of 132 beats/min, blood pressure of 140/92 mm Hg, and irregular respirations with a rate of 20 breaths/min. Neurologic examination showed right eye deviation, increased extensor tone with stiffening of the upper extremities, hyperreflexia, bilateral ankle clonus, and extensor Babinski responses. Thirty minutes after the event, the patient became responsive and was oriented to name and place.

A CT scan of the head was performed 2 hr after the event and was interpreted as negative, both initially and upon review. Residual neurologic deficits included left arm weakness, bilateral leg weakness (left greater than right), and jerking movements shown to be seizures by EEG. A repeat CT scan performed 10 days later (Fig. 1) showed multiple discrete enhancing cortical lesions bilaterally. The patient underwent intensive physical therapy with gradual improvement in his weakness and was discharged 6 weeks after the event with only minimal disability.

Received August 24, 1985; accepted after revision February 27, 1986.

¹ Department of Radiology, Medical College of Virginia, Virginia Commonwealth University, Box 615, MCV Station, Richmond, VA 23298. Address reprint requests to M. E. Jensen.

² Department of Radiology, McGuire VA Medical Center, 1201 Broad Rock Road, Richmond, VA 23249.

AJNR 7:823-827, September/October 1986
0195-6108/86/0705-0823

© American Society of Neuroradiology

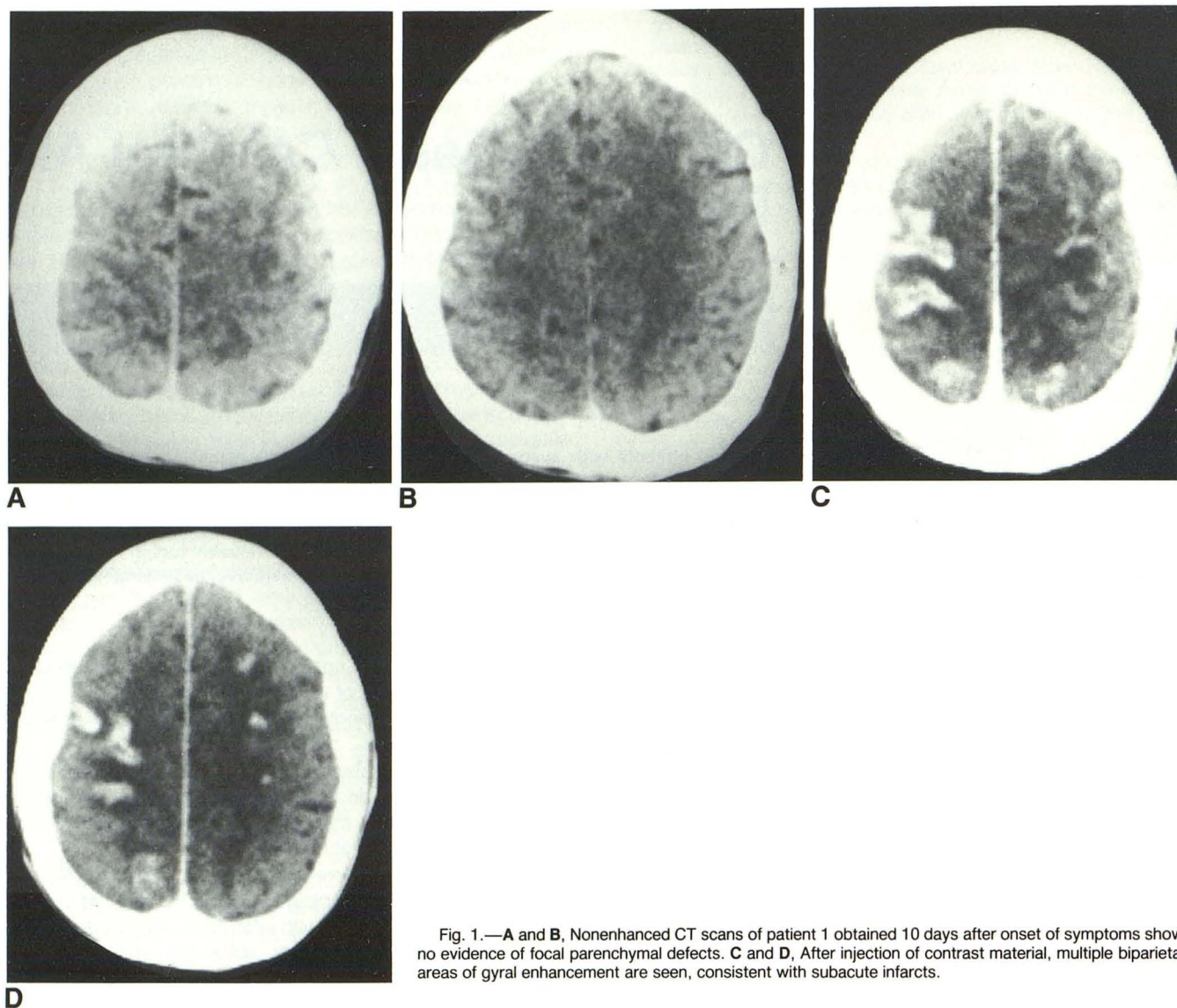


Fig. 1.—A and B, Nonenhanced CT scans of patient 1 obtained 10 days after onset of symptoms show no evidence of focal parenchymal defects. C and D, After injection of contrast material, multiple biparietal areas of gyral enhancement are seen, consistent with subacute infarcts.

Case 2

A 34-year-old woman was placed on hyperalimentation via a subclavian venous catheter, the tip of which was 2 cm from the right atrium. While sitting upright in bed, her central line was inadvertently disconnected. She complained of sudden shortness of breath and was tachycardic and diaphoretic. She became stuporous and developed a left hemiplegia. A CT scan of her head (Figs. 2A and 2B) performed within 2 hr was interpreted as negative by the clinician. The radiologist reviewing the study thought the scan showed a low density in the right frontal region consistent with infarction. Lower-extremity Doppler sonography was negative for deep venous thrombosis, and a ventilation/perfusion pulmonary radionuclide scan was negative for pulmonary emboli. An echocardiogram showed no evidence of a patent foramen ovale. A follow-up CT (Figs. 2C and 2D) 7 days later showed a large right frontoparietal enhancing lesion. The patient's condition improved with intensive rehabilitation and she was discharged with minimal residual weakness, although she still required a cane for mild instability while walking.

Case 3

A 23-year-old man with end-stage renal disease on chronic hemodialysis was admitted for placement of a brachiobasilic arteriovenous fistula. After completion of the venous anastomosis, there was poor flow through the graft. The arterial anastomosis was then opened partially and a No. 4 Fogarty catheter was passed proximally through the graft with return of a small amount of clot. This was done several times, and on two of the passes the balloon was felt to rupture, with an undetermined amount of air passing into the venous system. After the procedure, the patient was taken to the recovery room in stable condition. He was very slow to awaken from general anesthesia and remained stuporous, with withdrawal only to deep pain by the next morning. At that time, he showed no response to visual threat and a left third cranial nerve palsy was present. Also noted was a depressed left nasolabial fold, decreased left corneal reflex, and a left positive Babinski sign. A CT scan of his head (Fig. 3A) showed bilateral thalamic low densities consistent with infarction. The patient's level of consciousness gradually improved, but speech

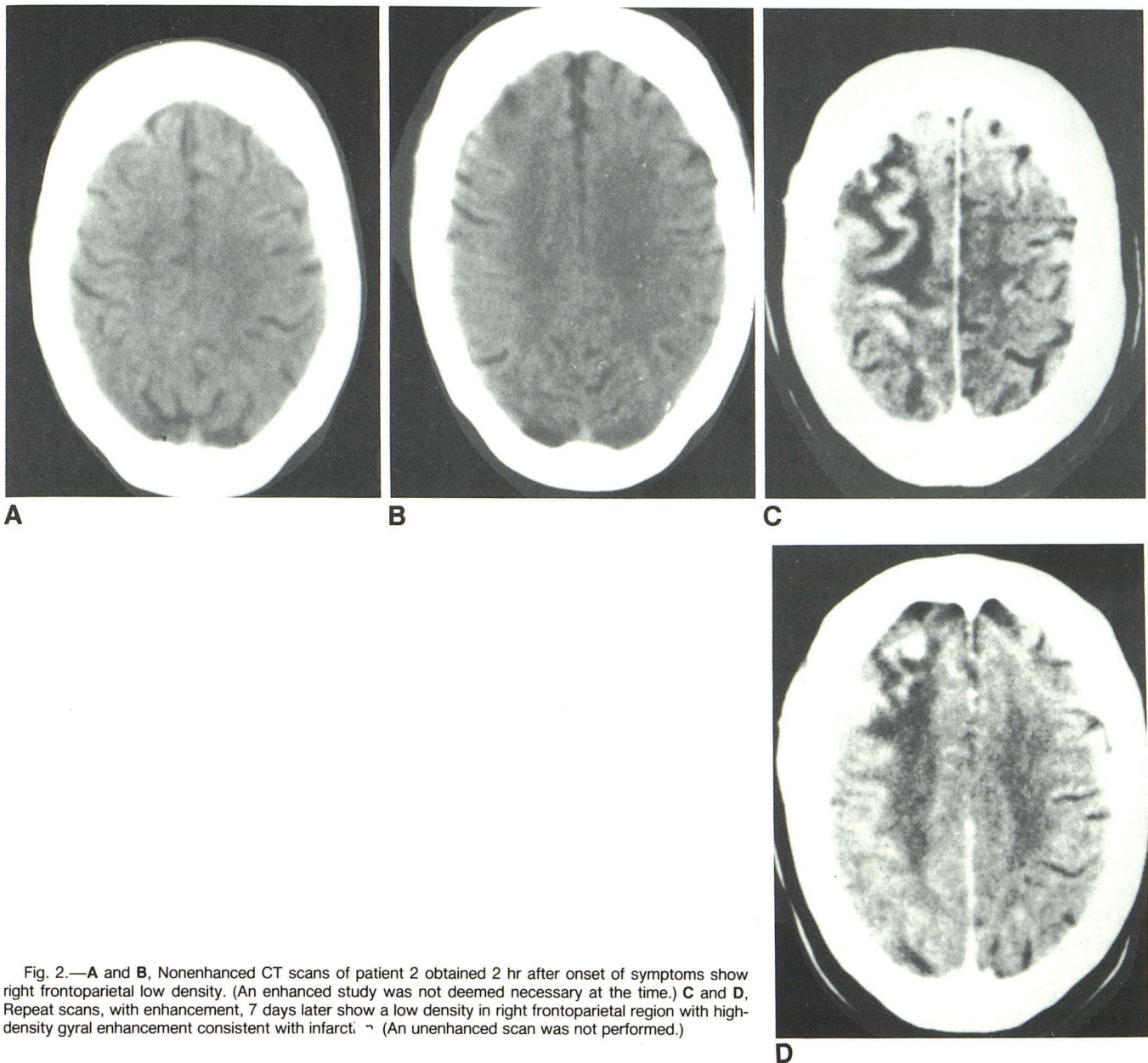


Fig. 2.—A and B, Nonenhanced CT scans of patient 2 obtained 2 hr after onset of symptoms show right frontoparietal low density. (An enhanced study was not deemed necessary at the time.) C and D, Repeat scans, with enhancement, 7 days later show a low density in right frontoparietal region with high-density gyral enhancement consistent with infarct. (An unenhanced scan was not performed.)

defects and left-sided weakness were noted. A follow-up enhanced CT (Fig. 3B) performed 2 days after the event showed no enhancement of the bilateral thalamic infarcts. A third scan (Fig. 3C) done 8 days after the event showed ring enhancement of the right infarct and homogeneous enhancement of the left. He was transferred to the Department of Rehabilitative Medicine, where his speech and ataxia improved and he was able to ambulate safely with the assistance of a walker.

Discussion

Systemic air embolism has been reported as a complication in penetrating thoracic and cranial trauma; central line placement and intravenous therapy; hemodialysis; thoracic, car-

diovascular, and neurosurgical operations; decompression sickness; mechanical ventilation with intermittent positive pressure; diagnostic invasive procedures, such as thoracentesis, needle biopsy of the lung, arteriography, and perirenal air insufflation; abortion; placenta previa; and oral-genital sexual relations in the female. Neurologic lesions caused by venous air introduced through a central line were first reported by Ponsky and Pories in 1971 [4]. The suspected mechanism was first described by Durant et al. in 1947 [5]. After injecting large venous air emboli into dogs, immediate dilatation of the right atrium and ventricle with a rapidly developing area of right ventricular ischemia was seen. They postulated that this was due to unilateral obstruction of the right pulmonary outflow tract. It was also noted that if the head was higher

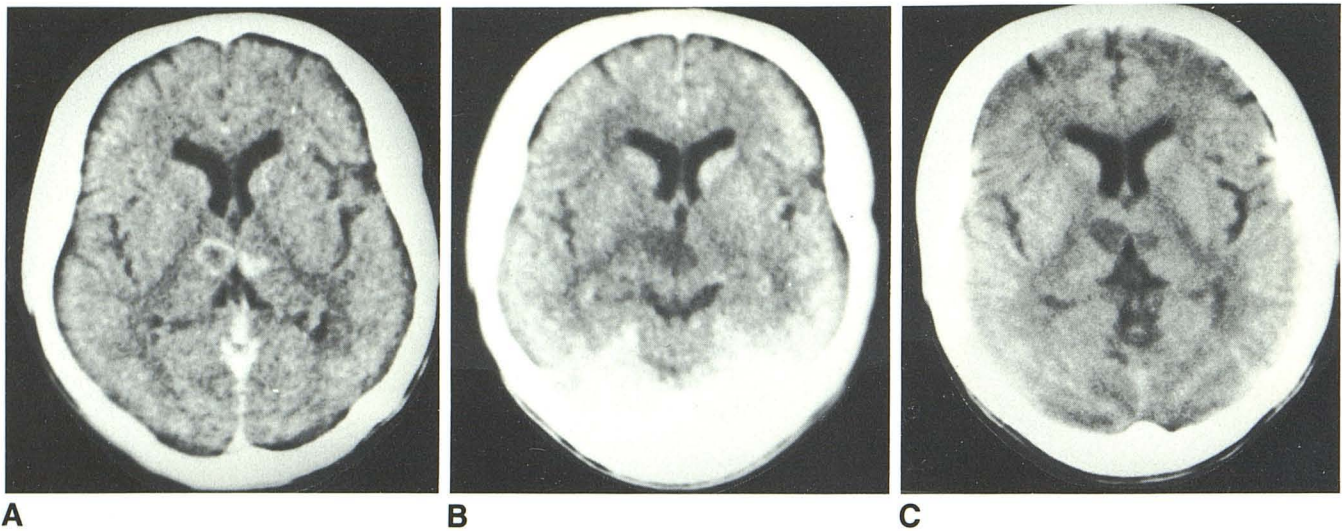


Fig. 3.—**A**, Nonenhanced CT scans of patient 3 obtained 1 day after onset of symptoms show bilateral thalamic low-density lesions, right larger than left, consistent with infarction. **B**, Repeated scan, with enhancement, 2 days after

the event shows no enhancement of bilateral thalamic infarcts. **C**, Enhanced scan done 8 days after the event shows ring enhancement of right thalamic infarct and homogeneous enhancement of left thalamic infarct.

than the aortic arch, air entered the cerebral circulation and caused a variety of neurologic problems.

The mechanism by which venous air emboli enter the arterial circulation is controversial. Originally, it was thought that the increase in the right heart pressures from the pulmonary outflow obstruction caused shunting of blood through a preexisting anatomic defect. In two cases reported by Kearns et al. [6], neither an atrial septal defect nor a patent foramen ovale could be seen. Marquez et al. [7] also reported a paradoxical cerebral air embolism without an intracardiac septal defect. Butler and Hills [8] found that although the lungs act as effective bubble filters, certain conditions—such as pharmacologic agents, oxygen toxicity, and excessive volumes of gas—may allow the passage of venous bubbles through the pulmonary vasculature. Rapid infusions of air at 0.35 ml/kg/min can result in systemic embolization in patients with nondefective hearts [9].

The diagnosis is usually based on the clinical findings, which are nonspecific. Symptoms may include dizziness, anxiety, fear of death, dyspnea, chest pain, and sudden loss of consciousness [1]. The only specific clinical finding is the classic mill-wheel murmur, which may be transient, and often is not present [10]. Wheezing due to acute bronchospasm, elevated right heart pressures, hypotension, and pulmonary edema may be present with large emboli [11]. Focal neurologic defects, seizures, and coma have been reported with cerebral involvement; and examination of the fundi may show air bubbles in the retinal vessels [1, 5].

The classical course of venous air emboli, after they traverse the pulmonary vasculature, is from the left ventricle into the aorta, where they enter the first major branch, the brachiocephalic artery, and proceed on to the right carotid circulation. If the patient is erect, the target regions are the parietal and occipital lobes. When the patient is in the supine

position, the emboli are more likely to travel to the neurologically silent areas, resulting in a lack of symptoms [6]. Menkin and Schwartzman [1], however, state that no unique pattern of lesions is seen. Supratentorial involvement in the distribution of the major arteries and branches is more common than involvement of subtentorial structures.

Very little has been reported on CT findings in cerebral air embolism. Voorhies and Fraser's case [2] showed multiple small areas of air density in the right cerebral hemisphere on the initial scan. Kearns et al. [6] showed a single air-density lesion in the right occipital lobe. A repeat scan 5 days later showed resolution of the air-density lesion with a residual area of low density consistent with infarction. A second patient also showed a right occipital cortical low density consistent with infarction 5 days after onset of left homonymous hemianopsia. An initial scan had not been obtained. Hwang et al. [3] showed multiple bilateral low-density lesions of varying sizes in the frontal lobe on an initial scan. Attenuation coefficients of the lesions were equal to that of air in the left frontal sinus.

Marquez et al. [7] showed, on autopsy, multiple foci of infarction and encephalomalacia in both hemispheres, right greater than left, in a neurosurgical patient who underwent trigeminal rhizotomy in the sitting position. Encephalomalacia was seen in the cortical, subcortical, and deeper locations more often on the right than the left. Other lesions were noted in the corpus callosum, right basal ganglia, and thalamus. Most lesions were in the distribution of the middle cerebral artery and the anterior cerebral artery, both of which were free of atherosclerosis and thrombosis.

Our patients displayed a variety of CT findings. All had initial scans without contrast, one of which was interpreted as normal. Patient 1 has a repeat study 10 days later showing multiple enhancing lesions in both parietal lobes, right greater

than left. Patient 2 showed a large, enhancing lesion in the right frontoparietal lobe 7 days after the event. Patient 3 showed bilateral low-density regions in the thalami within 24 hr, the right being larger than the left. Both enhanced 8 days later, with the right infarct showing ring enhancement.

Prevention and Treatment

Systemic air emboli can be prevented by using the proper technique during central line placement. The patient should be in the Trendelenburg position prior to starting the procedure. The Valsalva maneuver is performed during insertion, and the hub is occluded as much as possible to prevent air from entering [11]. Luer-Lock connections to avoid disconnection, and placement of sutures to prevent dislodgement, are recommended [6].

During surgical procedures in which air embolism is a risk, Doppler monitoring over the right heart is valuable, as is measurement of end-tidal carbon dioxide and pulmonary artery pressure [11].

Immediate treatment of air embolism includes placing the patient in the left lateral decubitus position [5], aspirating air through a central venous catheter [11], and administering 100% oxygen to decrease nitrogen content in the alveolus [11]. The patient should be transferred to a hyperbaric recompression (HBR) chamber, if available. Response to HBR is variable, but Mader and Hulet [12] reported resolution of neurologic deficits following HBR that was performed 29 hr after the onset of symptoms.

If cerebral embolism is suspected and HBR is immediately available, then CT can be dispensed with in favor of treatment.

However, an emergency noncontrast CT can be performed while awaiting transfer, if HBR is located elsewhere [3].

REFERENCES

1. Menkin M, Schwartzman RJ. Cerebral air embolism. *Arch Neurol* 1977;34:168-170
2. Voorhies RM, Fraser RA. Cerebral air embolism occurring at angiography and diagnosed by computed tomography. *J Neurosurg* 1984;60:177-178
3. Hwang T, Fremaux R, Sears ES, et al. Confirmation of cerebral air embolism with computerized tomography. *Ann Neurol* 1983;13:214-215
4. Ponsky JL, Pories WJ. Paradoxical cerebral air embolism. Letter to the editor. *N Engl J Med* 1971;284:985
5. Durant TM, Long J, Oppenheimer MJ. Pulmonary (venous) air embolism. *Am Heart J* 1947;33:269-281
6. Kearns PJ, Haulk AA, McDonald TW. Homonymous hemianopsia due to cerebral embolism from central venous catheters. *West J Med* 1984;140:615-617
7. Marquez J, Sladen A, Gendell H, Boehnke M, Mendelow H. Paradoxical cerebral air embolism without an intracardiac septal defect. *J Neurosurg* 1981;55:997-1000
8. Butler BD, Hills BA. The lung as a filter for microbubbles. *J Appl Physiol* 1979;47:537-543
9. Butler BD, Hills BA. Paradoxical air embolism: transcapillary route. Letter to the editor. *Crit Care Med* 1983;11:837
10. Grace DM. Air embolism with neurologic complications: a potential hazard of central venous catheters. *Can J Surg* 1977;20:51-53
11. O'Quin RJ, Lakshminarayan S. Venous air embolism. *Arch Intern Med* 1982;142:2173-2176
12. Mader JT, Hulet WH. Delayed hyperbaric treatment of cerebral air embolism. *Arch Neurol* 1979;36:504-505